Plevral Effüzyon Kliniğini Taklit Eden Dev Aort Anevrizması Olgusu

Giant Dissecting Aortic Aneurysm Imitating Pleural Effusion

Plevral Effüzyonda Yanıltıcı Akciğer Grafisi / Misleading Chest Radiography of Pleural Effusion

Göktürk Fındık, Seray Kalaycıoğlu Hazer, Sadi Kaya
Department of Thoracic Surgery, Atatürk Chest Diseases and Chest Surgery Education and Research Hospital, Ankara, Türkiye.

62 years old male patient, was admitted to our clinic suffering severe dyspnea. Breath sounds are absent on the left side. The chest graphy, pleural effusion was seen on the left hemythorax (Figure 1). Thoracoabdominal computed tomography showed giant aortic aneurysm that filled half of the left hemythorax and bilateral polycystic kidney (Figure 2-3).

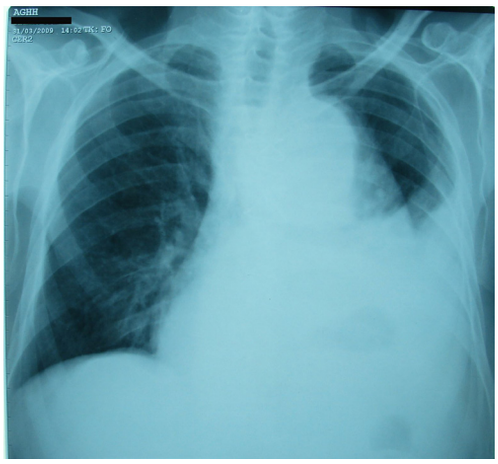

Figure 1. Dissecting aortic aneurysm seems like left pleural effusion in posterior anterior chest radiography

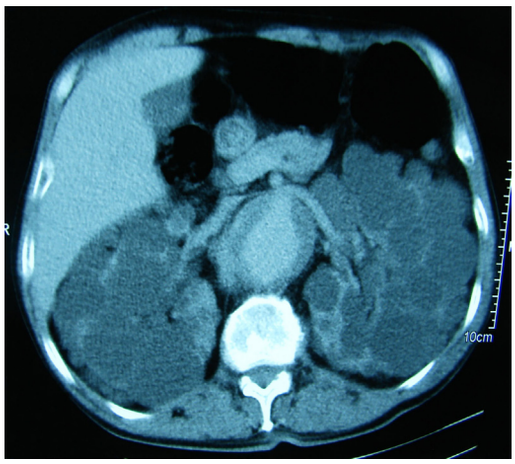

Figure 2. Abdominal computed tomography shows bilateral polycystic kidney

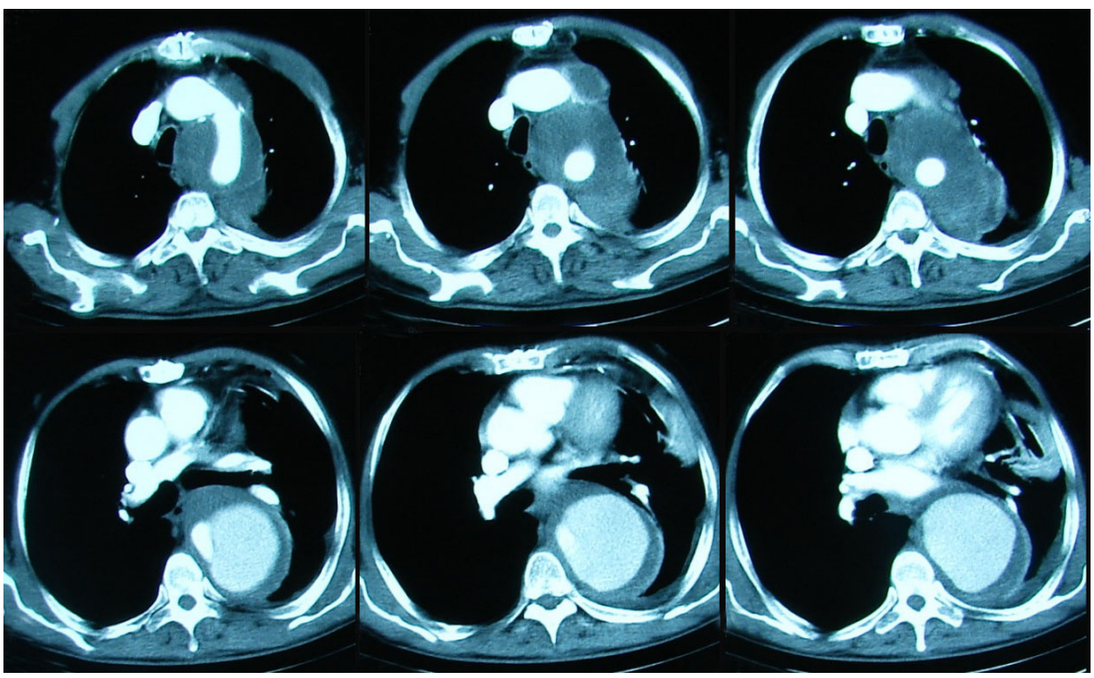

Figure 3. Thorax computed tomography shows dissecting aortic aneurysm and atelectatic lung field

DOI: 10.4328/JCAM.10.2.31 Received: 26.11.2009 Accepted: 17.12.2009 Printed: 01.05.2010 J Clin Anal Med 2010;1(3):180-180
Corresponding author: Göktürk Fındık, Department of Thoracic Surgery, Atatürk Chest Diseases and Chest Surgery Education and Research Hospital, Ankara, Türkiye. Phone: +90 312 355 21 10 Email: gokturkfindik@hotmail.com