

Bronş Ağacının Dallanma Biçimindeki Farklılıklar

Variations in Patterns of Bronchial Tree

Bronş Ağacı / Bronchial Tree

Cenk Kılıç[1], Yalçın Kirici[1], Hasan Ozan[1]
[1]Department of Anatomy, Gulhane Military Medical Academy, Faculty of Medicine, Ankara, Turkey.

Özet

Amaç

Bronş ağacının dallanma biçimindeki farklılıkların bilinmesi göğüs hastalıklarının tanısı ve cerrahisi için yararlıdır. Çalışmamızda bronş ağacının dallanma biçimindeki farklılıkları ortaya çıkarmayı amaçladık.

Gereç ve Yöntemler

Bu çalışmada 15 kadavraya ait 15 sağ, 15 sol akciğer kullanıldı. Her bir lobun tüm dalları etrafını saran parankimden diseke edildi. Bronş ağacının dallanması görünür hale getirildi. Segmental ve bazı subsegmental bronkusların dallanma biçimleri belirlendi ve aksesuar bronkusların bulunup bulunmadığı incelendi.

Bulgular

Bronş ağacının dallanma biçimindeki en sık farklılıkların sağ tarafta B6c, B6a+6b; B7, B8, B9+10 ve sol tarafta B1+2, B3; B7+8, B9+10 şeklinde olduğunu tespit ettik. En sık görülen aksesuar bronkuslar sağ tarafta B10 segmentinden çıkan bronchus segmentalis subsuperior, ve sol tarafta bronchus segmentalis subsuperior ve B10 segmentinden çıkan bronchus segmentalis subsuperior'dur. Birçok araştırmacı bronş ağacının dallarının tespit edilmesi için farklı terminolojiler kullanmıştır. Sol akciğerlerde B1+2 (60%) ve B7+8 (79,99%) şeklindeki dallanma biçimlerini daha sık olarak bulduk.

Sonuç

Sol tarafta 8 segmental bronkus bulunduğunu tespit ettik. Bu çalışma birçok radyolojik ve anatomik çalışma için faydalı olacaktır.

Anahtar Kelimeler

Bronkuslar, Akciğer, Göğüs Cerrahisi, Bronkoskopi, Bronşiyal Hastalıklar, Terminoloji.

Abstract

Aim

Knowledge of variations in patterns of bronchial tree is useful for diagnosis and surgery of chest diseases. In our study we aimed to expose the variations in patterns of bronchial tree.

Material and Methods

In this study 15 right and 15 left lungs from 15 cadavers were used. All branches of each lobe were dissected from the surrounding parenchyma. Ramification of bronchial tree was displayed. The patterns of segmental and some subsegmental bronchi were determinated and whether accessory bronchus present or not was examined.

Results

We identified that most common variations in the patterns of bronchial tree are B6c, B6a+6b; B7, B8, B9+10 in right side and B1+2, B3; B7+8, B9+10 in left side. The most common accessory bronchi were bronchus subsuperior arising from B10 in right side, and bronchus subsuperior and bronchus subsuperior arising from B10 in left side. Many researchers used different terminologies for identification of branches of bronchial tree. We commonly found patterns of B1+2 (60%) and B7+8 (79,99%) in left lungs.

Conclusion

It is identified that there are 8 segmental bronchi on the left. This study will be helpful for many radiological and anatomical studies.

Keywords

Bronchi, Lung, Thoracic Surgery, Bronchoscopy, Bronchial Diseases, Terminology.

DOI: 10.4328/JCAM.10.3.16 **Received:** 24.01.2010 **Accepted:** 19.02.2010 **Printed:** 01.09.2010 J.Clin.Anal.Med. 2010;1(3):147-151
Corresponding Author: Cenk Kılıç, Department of Anatomy, Faculty of Medicine, Gulhane Military Medical Academy, Etlik, Ankara, 06018, Turkey. **Phone:** +90 312 304 35 09 **Fax:** +90 312 381 06 02 **E-mail:** ckilicmd@yahoo.com

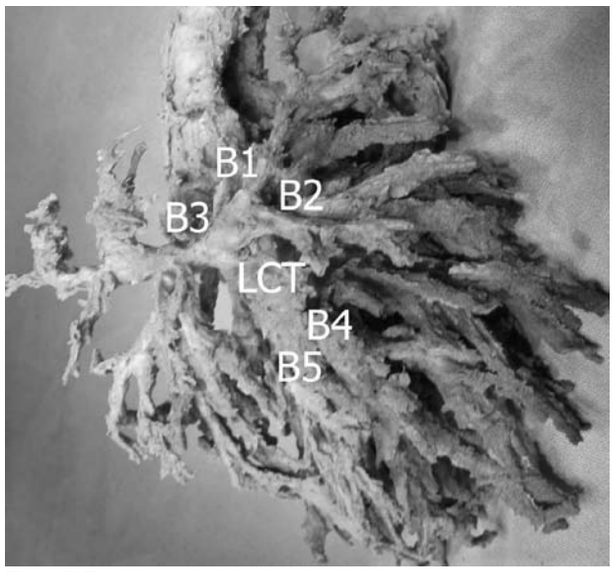

Figure 3. The left superior lobar bronchus (left lung, lateral view) shows a division into four branches: B1 (apical), B2 (posterior), B3 (anterior) and LCT (lingular common trunk).

Table 1. The rates of patterns of segmental bronchi according to side.

	Right lung	Left lung
B1,B2,B3	86,6%	40%
B1,B2,B3,X	13,33%	-
B1+B2,B3	-	60%
B4 and B5 superior-inferior	6,66%	100%
B4 and B5 medial-lateral	93,33%	-
An extra bronchus after lingular division	-	13,33%
Three bronchi in the lingular division	-	46,66%
B7 absent	13,33%	6,66%
B7,B8, B9,B10	20%	-
B7+8, B9+10	6,66%	53,33%
B7,B8, B9+10	53,33%	-
B7+8, B9,B10	-	26,66%
B7,B8+9+10	6,66%	-
B7 separated from B8	-	13,33%
Irregular basal stem	-	-

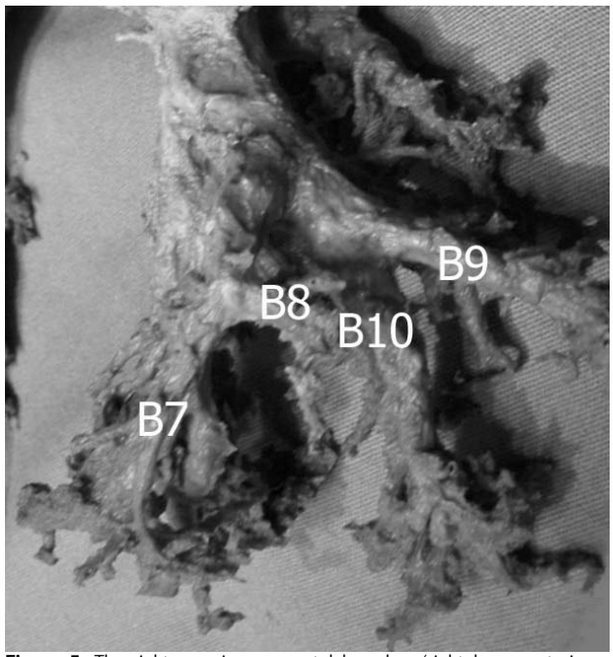

Figure 5. The right superior segmental bronchus (right lung, posterior view) shows a division into two branches: B6a+6b (medial+superior) and B6c (lateral).



Figure 4. The left superior lobar bronchus (left lung, lateral view) shows a division into three branches: B1+B2 (apicoposterior), B3 (anterior) and LCT (lingular common trunk).

Table 2. The rates of patterns of the superior segmental bronchi according to side.

	Right lung	Left lung
B6a,B6b,B6c	20%	40%
B6a,B6b+c	-	26,66%
B6b,B6a+c	6,66%	6,66%
B6c,B6a+b	66,66%	20%
Irregular B6	6,66%	6,66%

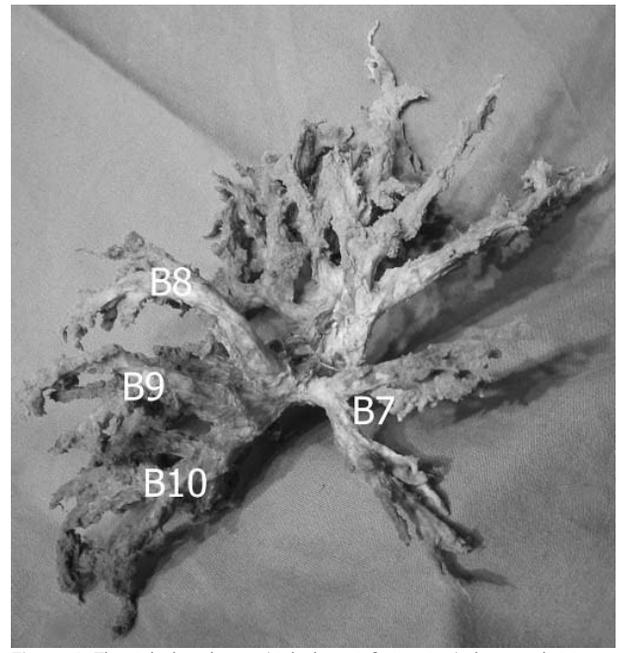

Figure 6. The right basal stem (right lung, inferior view) shows a division into three branches: B7 (medial basilar), B8 (anterior basilar) and B9+10 (lateral and posterior basilar).

Introduction

Variations of airways may cause unexpected complications during endotracheal intubation and chest surgery. Knowledge of variations in patterns of bronchial tree is necessary for diagnosis and surgery of chest diseases. Thus in our study we aimed to expose the variations in patterns of bronchial tree.

The right superior lobar bronchus arises from the right main bronchus. The right superior lobar bronchus commonly divides into three branches designated apical (B1), posterior (B2) and anterior (B3) [1-4]. Then, the right main bronchus continues as the intermediate bronchus [2-4]. The intermediate bronchus bifurcates to become the bronchi to the middle and lower lobes [2,3]. The middle lobar bronchus bifurcates into lateral (B4) and medial (B5) segmental branches [1-4]. The right inferior lobar bronchus; bifurcates into superior (B6), medial basilar (B7), anterior basilar (B8), lateral basilar (B9) and posterior basilar (B10) segmental branches [1-4].

The left main bronchus divides into the upper and lower lobar bronchi [1-4]. The left superior lobar bronchus commonly bifurcates two divisions. The upper division immediately divides into three segmental branches, B1, B2 and B3. The lower division is the lingular common trunk and divides into superior (B4) and inferior (B5) divisions [2,3]. The left inferior lobar bronchus; bifurcates into B6, B7, B8, B9 and B10 segmental branches [1-3].



Figure 1. The right superior lobar bronchus (right lung, lateral view) shows a division into three branches: B1 (apical), B2 (posterior) and B3 (anterior).

Material and Methods

In this study 15 right and 15 left lungs from 15 cadavers fixed with formaldehyde were used. The cases with bronchopulmonary disease were not included in the study. The ages of the subjects were from 37-64 years (8 males and 7 females). Anterior thoracic wall was cut with costotomy and elevated. Then the lung was removed.

All lungs were injected with red ink through the trachea. Then, vessels and lymph nodes in the hilar region was removed. The primary branches of each lobe were dissected from the surrounding parenchyma. Each lobe was also dissected from the anterior surface under the dissecting microscope. Ramification of bronchial tree was displayed and photographied.

The patterns of segmental and some subsegmental bronchi were determinated and whether accessory bronchus present or not was examined.

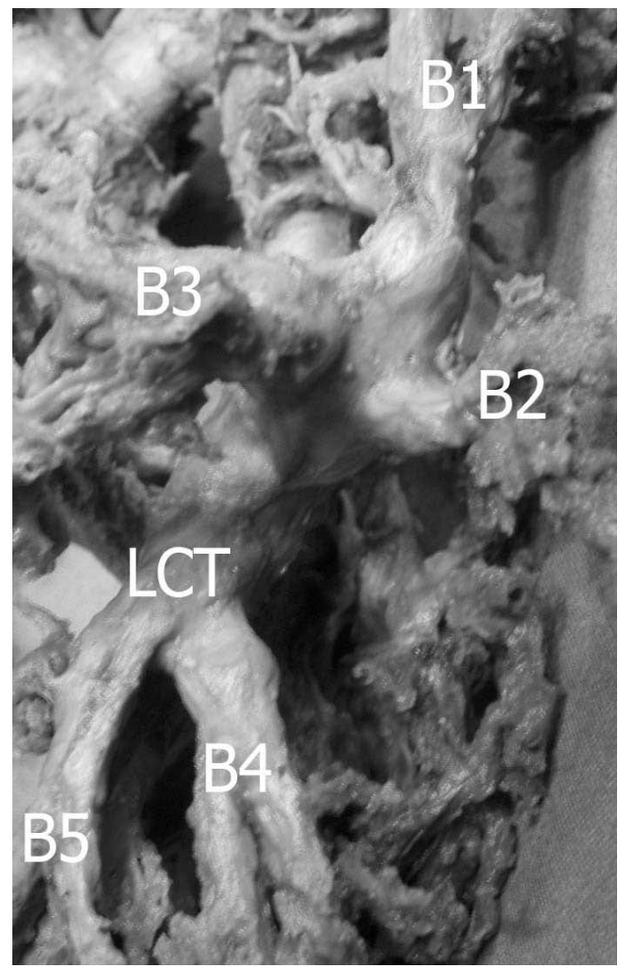

Figure 2. The right superior lobar bronchus (right lung, lateral view) shows a division into four branches: B1 (apical), B2 (posterior), B3 (anterior) and BX (accessory bronchus).

Results

The patterns of segmental and some subsegmental distribution bronchi and accessory bronchi were displayed in Figure 1-8 and documented in Table 1-3.



Figure 7. The left basal stem (left lung, anterior view) shows a division into two branches: B7+8 (medial and anterior basilar) and B9+10 (lateral and posterior basilar).

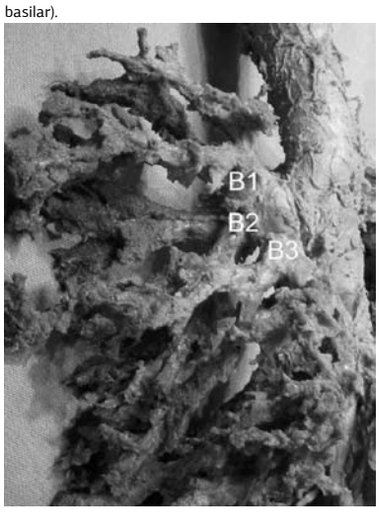

Figure 8. B*, The subsuperior bronchus; B*(9), the subsuperior bronchus arising from B9 segment; B*(10), the subsuperior bronchus arising from B10 segment (right lung, posterior view).

Table 3. The rates of patterns of accessory bronchi according to side.

	Right lung	Left lung
Bronchus subsuperior	60%	60%
Bronchus subsuperior arising from B9	60%	46,66%
Bronchus subsuperior arising from B10	73,33%	60%

Table 4. The comparison of variations in ramifications of the left upper, right upper and right middle lobes.

	Right lung			Left lung			
	B1,B2, B3	B1,B2, B3,X	B4 and B5 superior-inferior	B1,B2, B3	B1+2, B3	An extra bronchus	Three bronchi
Boyden and Hamre	-	-	18%	-	-	-	-
Boyden and Scannell	46%	14%	-	-	-	-	-
Ghaye	30%	-	23%	83%	17%	-	-
Gonlugur	-	0,35%	-	-	-	0,4%	0,2%
Koshino	45%	2,6%	-	-	-	-	-
Scannell	-	-	-	-	-	12%	-
Present study	86,66%	13,33%	6,66%	40%	60%	13,33%	46,66%

Table 5. The comparison of variations in ramifications of the superior segmental bronchi.

	Right lung					Left lung				
	B6a, B6b, B6c	B6a, B6b+c	B6b, B6a+c	B6c, B6a+b	Irregular	B6a, B6b, B6c	B6a, B6b+c	B6b, B6a+c	B6c, B6a+b	Irregular
Berg	-	-	-	-	-	15%	43%	27%	10%	5%
Ferry and Boyden	4%	8%	2%	72%	14%	-	-	-	-	-
Ghaye	-	-	-	>65%	-	-	45%	-	-	
Naidich	-	-	-	60%	-	-	45%	-	-	-
Pitel and Boyden	-	-	-	-	-	18%	42%	32%	2%	6%
Smith and Boyden	6%	-	-	86%	8%	-	-	-	-	-
Present study	20%	-	6,66%	66,66%	6,66%	40%	26,66%	6,66%	20%	6,66%

Table 6. The comparison of variations in ramifications of right basal stem.

	B7 absent	B7,B8, B9,B10	B7+8, B9+10	B7,B8, B9+10	B7, B8+9+10
Berg	-	-	-	-	-
Ferry and Boyden	20%	-	-	-	-
Ghaye	10%	6%	3%	68%	10%
Naidich	-	15%	-	60%	-
Pitel and Boyden	-	-	-	-	-
Smith and Boyden	14%	-	-	-	-
Present study	13,33%	20%	6,66%	53,33%	6,66%

Table 7. The comparison of variations in ramifications of left basal stem.

	B7 absent	B7 separated from B8	B7+8,B9+10	B9,B10,B7+8	Irregular
Berg	3%	8%	67%	13%	9%
Ferry and Boyden	-	-	-	-	-
Ghaye	-	14%	76%	10%	-
Naidich	<5%	-	45%	15%	-
Pitel and Boyden	18%	42%	32%	2%	6%
Smith and Boyden	-	-	-	-	-
Present study	6,66%	13,33%	53,33%	26,66%	6,66%

Table 8. The comparison of rates of accessory bronchi.

	Right lung			Left lung		
	Bronchus subsuperior	Bronchus subsuperior arising from B9	Bronchus subsuperior arising from B10	Bronchus subsuperior	Bronchus subsuperior arising from B9	Bronchus subsuperior arising from B10
Berg	-	-	-	28,3%	66,7%	85%
Ferry and Boyden	61%	-	84%	-	-	-
Ghaye	56%	-	-	26%	-	-
Naidich	30%	-	-	30%	-	-
Pitel and Boyden	-	-	-	26%	80%	84%
Smith and Boyden	62%	-	84%	-	-	-
Present study	60%	60%	73,33%	60%	46,66%	60%

Discussion

Many researchers used different terminologies for identification of branches of bronchial tree [1-5]. There are 10 segmental bronchi on each lung as emphasized some authors [1,5]. Others reported that there are 8 or 9 segmental bronchi on each left lung [2-4]. We commonly found patterns of B1+2 (60%) and B7+8 (79,99%) in left lungs. It is identified that there are 8 segmental bronchi on the left.

The results of some researchers [3,6-15] were documented and compared in Table 4-8. It is reported that the most common variation in left upper lobe is three bronchi in the lingular division as our findings [4]. As a result of performing lingulectomy in case of this variation momentous complications may occur. Rate of "B1+2 and B3" in left side in our study is in conformity with results in literature [2,3,16]. Some reports [2,3] comment lingular common trunk is present in left upper lobe of all lungs as our study. Scannell cited that medial-lateral placement instead of superior-inferior is common in B4 and B5 segments of left upper lobe [7]. Ghaye et al [8] found that rate of this placement is 25%. On the contrary, this placement is absent in our study. In contrast to previous reports [9,10], in this study trifurcate pattern in middle lobe bronchus was not found. Computed Tomography and Magnetic Resonance of the Thorax states that right superior segmental bronchus is usually bifurcate, rarely trifurcate as our study [3]. In present study, B9 and B10 are usually arised from a common root the similarity in previous results [4,16]. General Thoracic Surgery mentions that the most common ramification pattern in left basal root is "B7+8 and B9+10" as our study [4]. We ascertained that rate of "B7+8" is more higher in left side than right side. Also, previous authors [2,4] assumed that "B7+8" is a single bronchus in left side. Variations in the patterns of the bronchial tree, for the most part, due to displacement of segmental and subsegmental bronchi. We thought that knowledge of variations in the patterns of the bronchial tree is necessary for most of the clinical implications. Also, this study will be helpful for many radiological and anatomical studies.

References

1. Bannister LH. Respiratory system. In: Williams PL, Bannister LH, Berry MM, Collins P, Dyson M, Dussek JE, Ferguson MWJ, editors. Gray's anatomy. 38th ed. New York: Churchill Livingstone; 1993. p. 1653-62.
2. Fraser RS, Müller NL, Colman N, Paré PD, editors. Fraser and Paré's diagnosis of diseases of the chest. 4th ed. Philadelphia: Saunders W.B. Company; 1999. p. 3-629.
3. Naidich DP, Webb WR, Müller NL, Krinsky GA, Zerhovni EA, Siegelma SS, editors. Computed tomography and magnetic resonance of the thorax. 3th ed. Philadelphia: Lippincott Williams & Wilkins; 1999. p. 169-226.
4. Shields TV. General thoracic surgery. 4th ed. Philadelphia: Lippincott Williams & Wilkins; 1994. p. 3-90.
5. Khurshid I, Anderson L, Downie GH. Tracheal accessory lobe take-off and quadrifurcation of right upper lobe bronchus: A rare tracheobronchial anomaly. Journal of Bronchology. 2003;10:58-60.
6. Berg RM, Boyden EA, Smith FR. An analysis of variations of segmental bronchi of the left lower lobe of fifty dissected, and ten injected lungs. J Thorac Surg. 1949;18:216-37.
7. Scannell JG. A study of variations of the bronchopulmonary segments in the left upper lobe. J Thorac Surg. 1947;31:530-7.
8. Ghaye B, Szapiro D, Fanchams JM, Dondelinger RF. Congenital bronchial abnormalities revisited. Radiographics. 2001;21:105-19.
9. Boyden EA, Hamre CJ. An analysis of variations in the bronchovascular patterns of the middle lobe in fifty dissected and twenty injected lungs. J Thorac Surg. 1951;21:172-88.
10. Gonlugur U, Efeoglu T, Kaptanoglu M, Akkurt I. Major anatomical variations of the tracheobronchial tree: Bronchoscopic observation. Anat Sci Int. 2005;80:111-5.
11. Boyden EA, Scannell JG. An analysis of variations in the bronchovascular pattern of the right upper lobe of fifty lungs. Am J Anat. 1948;82:27-72.
12. Ferry RM, Boyden EA. Variations in the bronchovascular patterns of the right lower lobe of fifty lungs. J Thorac Surg. 1951;22:188-201.
13. Koshino T, Murakami G, Sato TJ, Tsugane MH, Fujisawa Y, Mawatari T, Abe T. Configurations of the segmental and subsegmental bronchi and arteries in the right upper lobe of the human lung with special reference to their concomitant relations and double subsegmental arterial supply. Anat Sci Int. 2002;77:64-73.
14. Pitel M, Boyden EA. Variations in the bronchovascular patterns of the left lower lobe of fifty lungs. J Thorac Surg. 1953;26:633-53.
15. Smith FR, Boyden EA. An analysis of variations of the segmental bronchi of the right lower lobe of fifty injected lungs. J Thorac Surg. 1949;18:195-215.
16. Thompson BH, Lee WJ, Galvin JR, Wilson JS. University of Iowa's virtual hospital: lung anatomy. 1993. Available from: http://lib.cpums.edu.cn/jiepou/tupu/atlas/www.vh.org/adult/provider/radiology/LungAnatomy/LungAnatomy.html [accessed February, 2008]