Case Report
JCAM

Pulmonary vein thrombosis associated with metastatic ovarian cancer

Vermi Degerli, Arife Erdogan
Department of Emergency Medicine, Izmir Bozyaka Education and Research Hospital, Bozyaka, Izmir, Turkey

Abstract

Pulmonary vein thrombosis (PVT) is a rare, life-threatening, and difficult-to-diagnose condition. Most of the literature on PVT consists of case reports, and its actual incidence is unknown. It occurs especially as a complication of malignancy or pulmonary surgery. We present a case of PVT detected incidentally in a 25-year-old female who presented with dyspnea and left flank pain and underwent computed tomography pulmonary angiography with a preliminary diagnosis of pulmonary artery embolism. Further investigation revealed that the PVT was associated with the lung metastasis of ovarian cancer. The patient died one month after diagnosis due to malignancy-related complications. Because of its nonspecific symptoms and findings, PVT may easily be missed or misdiagnosed. An emergency physician should consider not only pulmonary artery embolism but also PVT when considering a thromboembolic event in the differential diagnosis regardless of etiology and use appropriate imaging modalities to confirm this diagnosis.

Keywords

Pulmonary Vein; Thrombosis; Rare Disease

DOI: 10.4328/JCAM.5880 Received: 28.04.2018 Accepted: 01.06.2018 Publihed Online: 05.06.2018 Printed: 01.01.2019 J Clin Anal Med 2019;10(1): 123-125
Corresponding Author: Vermi Degerli, Department of Emergency Medicine, Izmir Bozyaka Education and Research Hospital, 35170, Bozyaka, Izmir, Turkey.
GSM: +905072334186 F.: +90 2322277201 E-Mail: vermidegerli@yahoo.com
ORCID ID: 0000-0002-8556-1305

Introduction

Pulmonary vein thrombosis (PVT) is a rare disease which is difficult to diagnose. Although it is a life-threatening condition, it may easily be misdiagnosed given its nonspecific clinical presentations. Because the medical literature on the disease is mostly limited to case reports, its actual incidence remains unknown [1]. Although idiopathic cases have been reported in the literature, it often develops as a complication of pulmonary surgery or malignancy [2-4]. There is no gold standard for the diagnosis of PVT. A combination of diagnostic modalities such as computed tomography pulmonary angiography (CTPA), transesophageal echocardiogram (TEE), transthoracic echocardiogram (TTE), and magnetic resonance imaging (MRI) may be required for the diagnosis. Treatment may vary depending on the etiology, but anticoagulation is recommended in all cases unless there is an active bleeding [1,2]. We present an incidentally detected PVT in a young patient with metastatic ovarian cancer.

Case Report

A 25-year-old female presented to the emergency department (ED) with complaints of left flank pain for a week, and shortness of breath for 2-3 days. Her past medical history and family history were unremarkable for thromboembolic disorders and she did not have any diagnosed diseases. She denied smoking and using oral contraceptives or any other medication. Physical examination was remarkable for tachycardia (blood pressure 120/70 mmHg, heart rate 120 beats/min, respiratory rate 12 breaths/min and oxygen saturation 96% on room air). Pulmonary auscultation was normal. ECG confirmed sinus tachycardia. Laboratory results were within normal limits except for an elevated D-Dimer level (1179 ng/mL, normal range: 0-240). CTPA was performed to assess for pulmonary embolism, which revealed a large filling defect within the left inferior pulmonary vein consistent with a thrombus. Other findings on the CTPA included an invasive pulmonary mass in the left inferior lobe, left pleural effusion, mediastinal lymphadenopathy, bone metastasis, and post-obstructive infiltrates (Figure 1A-B). Anticoagulation therapy started; and patient admitted to the pulmonology department. The patient also received antibiotics for post-obstructive pneumonia. The TTE was normal and bilateral lower extremity venous Doppler ultrasonography was negative for deep vein thrombosis. Abdominal ultrasonography showed a left ovarian mass. The CA-125 level was elevated (456.3 U/mL, normal range: 0-35 U/mL). Transthoracic Tru-Cut biopsy was consistent with metastatic ovarian cancer. The PET-CT revealed ovarian cancer with lung, bone and adrenal gland metastases. She was discharged home on warfarin. Gynecologic oncology follow-up was arranged, and chemotherapy was initiated. About 1 month after discharge, the patient presented to another ED with shortness of breath and was admitted to the intensive care unit. CTPA was consistent with bilateral diffuse pneumonia and massive left pleural effusion (Figure 2). The patient died 3 days later due to multiple organ failure and respiratory failure requiring intubation and mechanical ventilation.

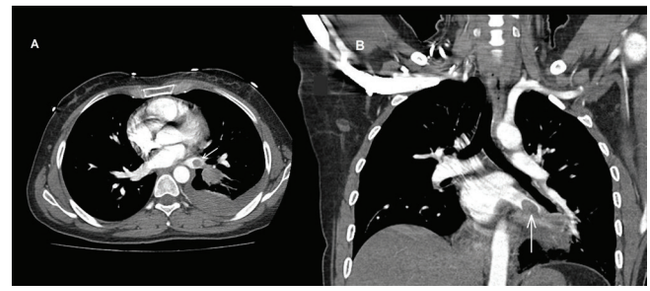

Figure 1. The arrow shows a filling defect in the left inferior pulmonary vein in the axial (A) and coronal (B) planes of the computed tomography pulmonary angiography.

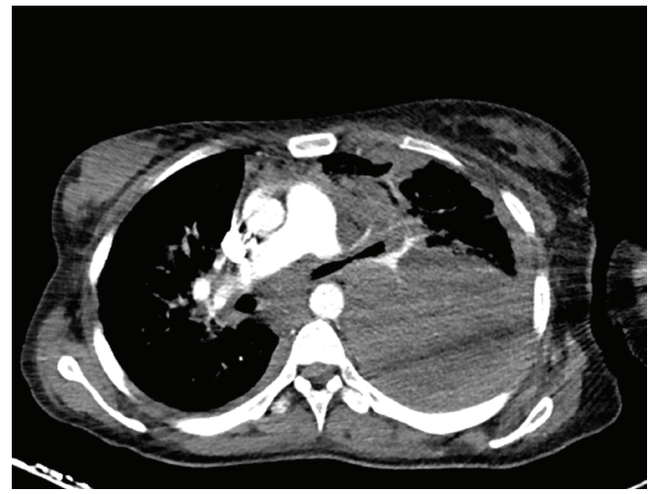

Figure 2. Malignant pleural effusion in the axial plane of the computed tomography pulmonary angiography

Discussion

PVT is a rare entity which is mostly underdiagnosed in clinical practice. Since most of the literature on the subject is limited to case reports, the exact cause and incidence of the disease are unknown. Thromboembolic events generally occur in the presence of clinically evident malignancies. PVT has most commonly been associated with malignancy (primary or metastatic lung tumors), pulmonary surgery or radiofrequency ablation for atrial fibrillation. Though less common, PVT may also occur in patients with arteriovenous malformation, atrial myxoma, blunt trauma, and mitral stenosis [1,2,5,6]. In addition, PVT has also been reported in a patient with sickle cell anemia and in a patient with a large hiatal hernia [7,8]. In some cases, it is idiopathic [3,4].

Patients with PVT are often asymptomatic, or they may present with nonspecific findings including pleuritic chest pain, shortness of breath, coughing, and hemoptysis. Thus, its diagnosis is often challenging and cannot be made on clinical grounds alone [1,2,7]. Besides, there is no gold standard method for the diagnosis of PVT. The findings and results should be interpreted in the appropriate clinical context in order to be diagnostically meaningful. Since the clinical findings of PVT are similar to those of pulmonary embolism, CTPA is often the imaging method of choice. Echocardiography may also be helpful by showing a thrombus in the left atrium, and TEE is more sensitive than TTE. In some cases, MRI may be preferred in order to differentiate between tumor thrombus and bland thrombus. A delay in the diagnosis may lead to pulmonary infarction, pulmonary edema, right ventricular failure, stroke, peripheral embolism, and renal or splenic infarction [1,2,5].

The treatment of PVT depends on the underlying cause and the patient's clinical condition. Anticoagulation is required in all patients, provided that there is no active bleeding. There is no consensus on the duration and type (warfarin, unfractionated heparin or low molecular weight heparin) of anticoagulant treatment. Anticoagulation plays an important role in pulmonary vein recanalization and prevents clot formation in the left atrium [1,2].

Antibiotics are generally required due to the risk of secondary infection in the obstructed or infarcted lung tissue [1,2,5]. Patients who do not respond to medical treatment and patients who develop thrombosis after lobectomy or lung transplantation may be treated successfully with thrombectomy [1,7]. However, there is little data regarding the outcomes of thrombectomy in patients with malignancy-associated PVT [1-2]. The treatment of post-operative PVT consists of conservative (anticoagulation, antibiotics) or more aggressive approaches (thrombectomy). In life-threatening circumstances such as massive hemoptysis or pulmonary necrosis, lobectomy may be performed [1,7].

Ovarian cancer is the most lethal gynecologic malignancy because patients generally present with nonspecific complaints and are mostly diagnosed at advanced stages when widespread metastases have already been established [9]. Our patient had presented with dyspnea and PVT was identified incidentally in the CTPA which was performed to exclude pulmonary embolism. Further examination had revealed metastatic ovarian cancer. We believe that in our patient, PVT was associated with the ovarian malignancy. Although there are various hypotheses, the pathogenetic relationship between PVT and malignancy is unclear. The suggested mechanisms are the extension of the tumor into the vein, the compression of the vein by the tumor, or epithelial damage caused by tumor invasion [5,7].

In conclusion, we would like to emphasize that when a thromboembolic event is considered in the differential diagnosis, not only pulmonary artery embolism but also PVT should be kept in mind, regardless of the etiology. Therefore, obtaining venous phase images during CTPA is important in order not to misdiagnose PVT. In addition, unless there is an active bleeding or a contraindication, anticoagulation should be initiated as soon as possible.

Scientific Responsibility Statement

The authors declare that they are responsible for the article's scientific content including study design, data collection, analysis and interpretation, writing, some of the main line, or all of the preparation and scientific review of the contents and approval of the final version of the article.

Animal and human rights statement

All procedures performed in this study were in accordance with the ethical standards of the institutional and/or national research committee and with the 1964 Helsinki declaration and its later amendments or comparable ethical standards. No animal or human studies were carried out by the authors for this article.

Conflict of interest

None of the authors received any type of financial support that could be considered potential conflict of interest regarding the manuscript or its submission.

References

1. Chaaya G, Vishnubhotla P. Pulmonary vein thrombosis: a recent systematic review. Cureus. 2017 Jan; 9 (1): e993.
2. Rana MA, Tilbury N, Gambling Y, Ahmad H, Naser K, Mady AF, et al. Idiopathic pulmonary vein thrombus extending into left atrium: A case report and review of the literature. Case Rep Med. 2016; 2016: 3528393.
3. Yu Y, Zhou L, Ni Y, Shi G. Negative D-dimer in idiopathic pulmonary vein thrombosis: a case report and literature review. Int Clin Exp Med. 2016; 9 (11): 22595-9.
4. Barreiro TJ, K ollipara VK, Gemmel DJ. Idiopathic pulmonary vein thrombosis? Respirology Case Reports. 2018; 6 (1): e00277
5. Akiode O, Prakash G. Pulmonary vein thrombosis associated with metastatic carcinoma. Fed Pract. 2014; 31 (12): 26-8.
6. Tamizifar B, Zadeh MR, Foroghi E. Pulmonary vein thrombosis after metastatic liposarcoma. Med Arh. 2012; 66 (1): 68-9.
7. Saoraya J, Inboriboon PC. Pulmonary vein thrombosis associated with a large hiatal hernia. J Emerg Med. 2013; 44: e299-e301.
8. Selvidge SD, Gavant ML. Idiopathic pulmonary vein thrombosis: Detection by CT and MR imaging. Am J Roentgenol. 1999; 172: 1639-41.
9. Kurman RJ, Shih IeM. Pathogenesis of ovarian cancer: lessons from morphology and molecular biology and their clinical implications. Int J Gynecol. Pathol. 2008; 27 (2): 151-60.

How to cite this article:
Degerli V, Erdogan A. Pulmonary vein thrombosis associated with metastatic ovarian cancer. J Clin Anal Med 2019;10(1): 128-30.