**Annals of Clinical and Analytical Medicine**
*Original Research*

# Hinged prosthesis in the knee revision surgery: Is there a great need?

Knee revision surgery

Mahmut Özdemir[1], Yüksel Uğur Yaradılmış[2], Ahmet Ateş[2], Ali Teoman Evren[2], Mustafa Caner Okkaoğlu[2] ,Murat Altay[2]
[1] From Department of Orthopaedics and Traumatology, VM Medikal Park Hospıtal
[2] Department of Orthopaedics and Traumatology, University of Health Sciences, Keçiören Health Practice and Research Center, Ankara, Turkey

**Abstract**
Aims: Two main different prosthesis designs are frequently used in revision surgery: the Constrained condylar knee (CCK) prosthesis and the Rotating hinge knee prostheses (RHK). The aim of this study is to present the successful results of the CCK prosthesis to the literature and compare these results with the RHK design.
Material and Methods: One hundred and ninety patients who underwent total knee revision surgery between February 2014 and October 2018 were retrospectively evaluated. They were classified in terms of age, gender and etiology, and bone defects were evaluated according to the AOIR classification. A total of 148 patients, 129 with CCK and 19 with RHK, were included. Functional results were evaluated with the WOMAC Osteoarthritis Index, and a Likert analysis was applied to measure patient satisfaction.
Results: According to the AORI classification, 34.5% of the patients were type I, 45% were type II, and 20.5% were type III. The mean preoperative WOMAC was 74 ± 9.6 in the CCK group, and 73.6 ± 10.6 in the RHK group postoperatively. In assessing patient satisfaction, t 5-Likert score was 4.2±0.6 in the CCK group, and 4.27±0.4 in the RHK group. There were no statistical differences in WOMAC and Likert analysis between CCK and RHK groups (respectively: p=0.876, p=0.962).
Discussion: CCK design implants provide sufficient successful functional outcomes in all types of bone defects in knee revision surgery. RHK-type prostheses are rarely required and more preferable for AORI type III bone loss.

**Keywords**
Knee Arthroplasty, Revision, Hinged Prosthesis, Constrained Prosthesis, Survivorship

DOI: 10.4328/ACAM.20990 Received: 2021-12-10 Accepted: 2022-04-19 Published Online: 2022-09-23
Corresponding Author: Yüksel Uğur Yaradılmış, Department of Orthopedics and Traumatology, Keçiören Health Practice and Research Center, 06280, Keçiören, Ankara, Turkey.
E-mail: ugur_yaradilmis@outlook.com P: +90 532 769 78 02 F: +90 312 356 90 02
Corresponding Author ORCID ID: https://orcid.org/0000-0002-7606-5690

## Introduction

The number of patients who underwent total knee arthroplasty is increasing worldwide and the need for revision also increases at the same rate. Recent projections expect the number of knee replacements performed in the United States to grow by about 673% in 2005 to 2030 [1]. The increase in primary and revision surgeries not only decreases patient satisfaction but also creates a significant increase in health expenditures [2,3]. Re-revision rates are higher than the need for revision after primary knee arthroplasty due to many reasons such as impaired ligament balance, decreased bone stock, joint line imbalance, more extensor mechanism problems and high infection rates due to long operation time [4,5].

While the most common cause of failure after revision knee prosthesis is infection, the second reason is prosthesis-related causes such as mechanical loosening and implant failure [6]. Apart from infection, the most important issue to be considered during revision surgery is to achieve good ligament balance with implants of appropriate size and appropriate mechanical properties in order to prevent aseptic loosening, wear and instability [7,8]. Therefore, the choice of implant is critical in revision surgery. Two different prosthesis designs are frequently used in revision surgery: Constrained condylar knee (CCK) prosthesis and Rotating hinge knee prostheses (RHK). Hinged prosthesis design is often used in ligament insufficiency or absence and provides high stability. However, mechanical complications such as wear and loosening are its main disadvantages [9,10]. CCK design implants have been manufactured more recently, are less constrained than hinged designs, and have been suggested for use in moderate ligament insufficiency and bone loss [11,12].

Two different prosthesis designs have been evaluated and compared in many studies in terms of many parameters such as survival rates, functional results and complications [13-15]. Despite many studies, there is no consensus on which design has better functional results and longer survival and which type of design should be preferred. Although it has been claimed that CCK design revision prostheses cause instability in severe insufficiency or absence of ligaments, we observed that the wide and deep post provided sufficient stability in our clinical practice. Therefore, our hypothesis is CCK design sufficient in revision knee surgery and RHK is rarely needed.

The aim of this study is to present the successful results of CCK prothesis to the literature and compare this results with the RHK design.

## Material and Methods

### *Patients and study design*

We retrospectively reviewed 190 patients who underwent total knee revision surgery between February 2014 and October 2018, after ethics committee approval. Exclusion criteria were revision with primary components (n = 2), arthrodesis (n = 1), amputation (n = 1), ex (n = 2), fracture fixation due to periprosthetic fracture (n = 4), missing data (n:12) and refusing to participate in the study (n = 20). A total of 148 patients, 129 with CCK and 19 with RHK, were included. Written informed consent was obtained from the legal guardian of each patient. The study was conducted in accordance with the principles of the Declaration of Helsinki.

The patients were classified in terms of age, gender, etiology and bone defects were evaluated according to the AOIR classification. Details of any complications developing after surgery were also recorded from hospital charts and clinic records. Bone defects during revision were documented intraoperatively by a research fellow present for each revision surgery and corroborated by operative recorders. Patients were followed up every 3 months in the first postoperative year and then annually. During these follow-ups, it was recorded whether additional interventions or surgical procedures were applied to the patients and whether complications developed in the patients. Functional results were evaluated with the WOMAC Osteoarthritis Index, and a Likert analysis was applied to measure patient satisfaction at the last visit.

***Clinical treatment:***

Before surgery, routine blood tests, ECG, PA chest radiography, ESR, CRP and, if necessary, joint fluid analysis were applied to the patients. In case of clinical suspicion, radiological examinations such as CT, MRI or scintigraphy were performed and the etiology was clarified. Two-stage revision surgery was performed in all patients with septic etiology. Antibiotic treatment was given according to the results of the cultures or according to the recommendations of the infectious diseases specialist in patients with negative cultures. The treatment was terminated after the recommended period was completed, and the ESR and CRP values returned to normal. After the end of antibiotic treatment, normal infection parameters, measured twice at one-week intervals were accepted as the termination of the infection and revision process has been applied. All revision surgeries were performed by a fellowship trained adult reconstruction surgeon at our institution. Culture-specific antibiotics were administered at recommended doses in septic patients, and 2 g cefazolin sodium in aseptic revisions as a prophylaxis 30 minutes before surgery.

***Surgical procedure and decision of implant design***

The procedure was applied after tourniquet application in the supine position under spinal or general anesthesia. An anterior longitudinal incision was made, and after reaching the joint capsule, arthrotomy was performed through a medial parapatellar incision. In cases where an adequate approach could not be achieved, quadriceps snip was applied. Pin fixation was applied to strengthen the attachment of the patellar tendon, and none of the patients needed a tuberositas tibia osteotomy. Implants were removed with the help of narrow saws, osteotomy blades, gig saws, various hand tools, cement extractors and special prosthesis extractors, and then bone defects were evaluated. Femoral and tibial bone cuts were made with the help of an intramedullary guide, and a fluoroscopy was used when the joint level could not be determined exactly. The decision to use CCK or RHK was made intraoperatively. The wedges to be added were measured. First of all, stability and motion control were done with CCK implant design. If there is instability despite the insertion with a wedge and CCK design, the RHK implant design has been used. Afterwards, two different brands of original implants, Zimmer (Synthes GmbH, Oberdorf, Switzerland) or Biomet (Biomet, Warsaw, Indiana, USA) were randomly applied with antibiotic cement and their

stability was checked,

*Follow-up*

On the first postoperative day, patients were mobilized and physical therapy was initiated after x-ray control. Prophylactic antibiotic treatment was continued intravenously for 3 days. CPM (continuous passive motion) device was applied to all patients during their hospitalization and 90 degrees of knee flexion without any complication was accepted as a discharge criterion. All patients received enoxaparin sodium 40 mg/day (Clexane; Aventis, Strasbourg, France) for pulmonary embolism and deep vein thrombosis prophylaxis for a month. Followed-up periods were every 3 months in the first postoperative year and then annually.

*Statistical analysis*

The data obtained in the study were analyzed statistically using SPSS v.22 software with a confidence interval of 95%. Qualitative data were stated as frequency distribution and quantitative data were stated as mean, minimum and maximum values. Inter-observer and intra-observer reliability was assessed using the interclass coefficient. Demographic data were evaluated with the Mann-Whitney U-test. The normal distribution was examined using the Kolmogorov-Smirnov test. The relationship between WOMAC values and Likert analysis results was examined using the Spearman correlation test. The categorical variables of CCK and RHK groups were evaluated with the Chi-square test, and numeric values not showing a normal distribution were evaluated with the Mann-Whitney U test. Categorical variables of AORI subgroups were evaluated with the Chi-square test, and numeric values not showing a normal distribution were evaluated with the Mann-Whitney U test. A p-value <0.05 was considered statistically significant.

## Results

The mean age of the patients was 68.4 ± 7.27 (50-89) years, 17 patients were male and 147 were female (M/F: 1/9). The mean follow-up period was 2.8 ± 1.3 years (range;1- 6). According to the AORI classification, 34.5% of the patients were type I, 45% were type II, and 20.5% were type III (Figure 1). The reasons for revision were infection in 72 patients, wear and osteolysis in 78 patients, instability in 7 patients and others in 5 patients (Figure2). The distribution of the data of the patients is given in terms of frequency and percentage in Table 1.

CCK was applied to 87% (n = 129) of the patients, and RHK type prosthesis was applied to 13% (n = 19). There was no statistically significant difference between the age and follow-up time of the patients who underwent CCK and RHK (respectively; p=0489, p=0.844). When the prosthesis preference in revisions due to etiological factors was examined, the revision rate due to both septic and aseptic reasons was 40% in both the RHK and CCK groups, and there was no statistical difference between septic/aseptic etiology (p = 0.256). RHK implants were not required to AORI type 1, which were used in 4 patients (12%) of AORI type 2 and 15 patients (78%) of AORI type 3. While the mean preoperative WOMAC score was 38 ± 5.8 in the CCK group, it was 74 ± 9.6 postoperatively. However, the mean preoperative WOMAC score in the RHK group was 34.5 ± 3.7. while, postoperatively it was 73.6 ± 10.6. In assessing patient satisfaction, 5-Likert score was 4.2±0.6 in the CCK group, and 4.27±0.4 in the RHK group. There were no statistical differences in WOMAC and Likert analysis between CCK and RHK groups (respectively: p=0.876, p=0.962). The complications rate was %8 (n=12), periprosthetic fracture (n=8), wound infection treated with oral antibiotics (n=1), re-infection (n=1), arterial thrombosis (n=1) and drop foot (n=1). There was no statistically significant difference between the complications in patients who underwent CCK and RHK (p>0.05, Table 2).

**Table 1.** Demographic data of the patients

| | Type 1 | Type 2 | Type 3 | p value |
|---|---|---|---|---|
| Patients | 49 | 64 | 29 | |
| Age | 66.9 ± 6.9 | 69.1 ± 7.5 | 68.9 ±6.5 | 0.305 |
| CCK design | 49 | 60 | 14 | <0.001 |
| RHK design | 0 | 4 | 15 | |
| WOMAC preoperative | 38.3 ± 5. | 36.4 ± 5.7 | 39.6 ± 6.9 | 0.254 |
| WOMAC postoperative | 73.3 ± 9.1 | 74.3 ± 9.2 | 73.4 ± 12.2 | 0,997 |
| 5-Likert | 4.1 0.7 | 4.37 0.5 | 4.1 0.5 | 0.106 |

**Table 2.** Comparison of the CCK and RHK implants

| | n=148 | Range or % |
|---|---|---|
| Age | 68.4 ± 7.27 | 50-89 |
| Side (Right/Left) | 77/71 | |
| Gender (Female/Male) | 131/17 | 9.1 |
| Etiology | | |
| Septic | 58 | 38% |
| Aseptic | 75 | 53,50% |
| Instability | 7 | 5,50% |
| Others | 5 | 3% |
| Follow-up | 2.8 ± 1.3 | 1.6 |
| Subtype AO | | |
| Type 1 | 51 | 34.5% |
| Type 2 | 66 | 45% |
| Type 3 | 31 | 20.5% |
| Implant design | | |
| CCK | 129 | 87% |
| RHK | 19 | 13% |
| WOMAC preoperative | 37.8 ± 5.8 | 21-57 |
| WOMAC postoperative | 74.2 ± 9.6 | 40-95 |
| 5-Likert | 4.2 ± 0.6 | 2.5 |

**Table 3.** Comparison of the AORI subtype

| | CCK | RHK | p value |
|---|---|---|---|
| Patients | 129 | 19 | |
| Age | 68.3 ± 7.3 | 69.6 ± 6.9 | 0.489 |
| Follow-up | 2.86 0.6 | 2.82 0.4 | 0.844 |
| Etiology (Septic /Aseptic) | 48/75 | 7.Ağu | 0.256 |
| Instability | 5 | 2 | 0.184 |
| AORI 1/2/3 | 49/60/14 | 0/4/15 | <0.001* |
| WOMAC preoperative | 38 ± 5.8 | 34.5 ± 3.7 | 0.112 |
| WOMAC postoperative | 74 ± 9.6 | 73.6± 10.6 | 0,876 |
| 5-Likert | 4.2± 0.6 | 4.27 ±0.4 | 0.962 |
| Periprosthetic fracture | 7 | 1 | 0.244 |
| Wound infection | | 1 | 0.866 |
| Re-infection | 1 | | 0.866 |
| Neurovascular complication | 1 | | 0.866 |
| Arterial thrombosis | 1 | | 0.866 |

According to the AORI classification, all AORI type 1 patients were treated with CCK design, and CCK design had enough stability in 93% of the AORI type 2 and %50 of AORI type 3. There were no significant differences between subtypes functional scores (Table 3). A correlation was observed between WOMAC and 5-Likert results (p<0.001, Figure 3).




**Figure 1.** Frequency of the AORI subtype

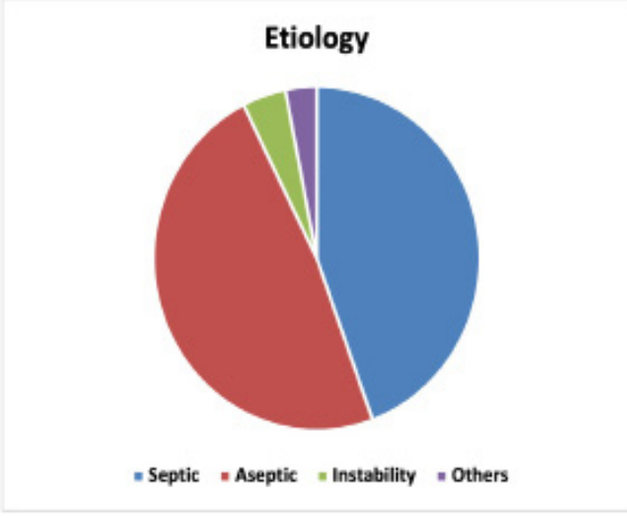


**Figure 2.** Etiology of the revision surgery

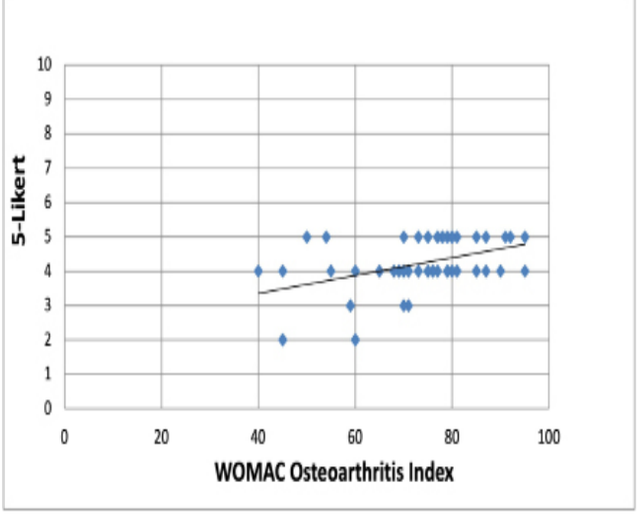


**Figure 3.** Distribution of 5-Likert and WOMAC

## Discussion

One of the most important principles of revision surgery is the selection of the most appropriate revision implant [16]. There are two different types of prostheses commonly used in revision knee surgery, CCK (constrained condylar knee) design and RHK (rotating hinged knee) design. It is still controversial which type of prosthesis is appropriate for revision surgery. Studies have shown that basically, RHK is a more constrained prosthesis and is considered to result in higher complication rates and lower survivorship compared to CCK. Therefore, CCK-type implants have gained popularity in revision surgery because they may require less bone resection and allow for future salvage-type procedures such as RHK if necessary [17,18]. In contrast, the RHK prosthesis is reported superior for patients with a severe deformity or instability [19]. There are few studies comparing these two different designs, which observed a significant difference between CCK or RHK usage rates. In this study, we demonstrated that CCK-type prosthesis design has as successful results, and RHK- type implants were rarely needed.

Several factors are effective in the selection of implants used in revision surgeries, ligament balance, bone loss, patient performance status and patient expectations [20]. However, there is no consensus on which design revision prosthesis should be used in different situations. Some authors claim that a hinged type revision prosthesis should be used in ligament insufficiency [21]. In contrast, some authors emphasize that, for cases with ligamentous insufficiency and moderate bone loss, a constrained condylar knee design is appropriate [21]. In a study evaluating implants used in revision surgery in stiff knee, it was claimed that using a rotating hinged device can provide excellent results in selected cases [13]. The literature comparing these RHK and CCK designs in the revision surgery include Vasso et. al. CCK (n:35) and RHK (n=18), Farfaelli et. al. CCK (n=50) and RHK (n=36) Bali et. al. CCK (n=19) and RHK (n=19) [20,22,23]. In our study, ligament balance was evaluated in the intraoperative period after the bone defect was replaced with a wedge. This preference reduced the need for an implant such as RHK design by up to 10%.

In a study by Shen et al., 496 patients who underwent revision knee prosthesis were examined, and adequate prosthesis design according to AORI classification was investigated [24]. They stated that, unlinked constrained prostheses displayed greater improvement in KSS when used in cases of aseptic AORI type III defects. However, patients undergoing revision for infection, may benefit from the use of linked constrained prostheses. Similarly, in our study, we found that RHK-type prostheses were used in patients with significantly reduced bone stock. In addition, we observed that CCK-type prostheses had similar results in all types of bone defects. As a result, we recommended the use of hinged prostheses in cases of excessive bone defect, but it should be kept in mind that CCK prostheses also give successful results.

*Limitation*

This study has several limitations. First, different techniques were applied to the patients such as graft, cement, structural allograft, metaphyseal cones or sleeves or augments for the

bone defects, and no standard method was specified. Second, the number of patients is insufficient to compare complication rates and short follow-up.

In conclusion, CCK design implants provide sufficient successful functional outcomes in all types of bone defects in knee revision surgery. RHK-type prostheses are rarely required and more preferable for AORI type III bone loss.

***Scientific Responsibility Statement***

*The authors declare that they are responsible for the article's scientific content including study design, data collection, analysis and interpretation, writing, some of the main line, or all of the preparation and scientific review of the contents and approval of the final version of the article.*

***Animal and human rights statement***

*All procedures performed in this study were in accordance with the ethical standards of the institutional and/or national research committee and with the 1964 Helsinki declaration and its later amendments or comparable ethical standards. No animal or human studies were carried out by the authors for this article.*

***Funding:*** *None*

***Conflict of interest***

*None of the authors received any type of financial support that could be considered potential conflict of interest regarding the manuscript or its submission.*

***References***

*1. Kurtz S, Ong K, Lau E, Mowat F, Halpern M. Projections of primary and revision hip and knee arthroplasty in the United States from 2005 to 2030. J Bone Joint Surg Am. 2007;89(4):780-5.*

*2. Güngör E, Başarır K, Binnet MS. A retrospective comparison of costs for the primary and revision total knee arthroplasty in Turkey. Acta Orthop Traumatol Turc. 2020;54(5):541-5.*

*3. Weber M, Renkawitz T, Voellner F, Craiovan B, Greimel F, Worlicek M, Grifka J, Benditz A. Revision Surgery in Total Joint Replacement Is Cost-Intensive. Biomed Res Int. 2018 25:8987104.*

*4. Kunze KN, Akram F, Fuller BC, Choi J, Sporer SM, Levine BR. Superior survivorship for posterior stabilized versus constrained condylar articulations after revision total knee arthroplasty: a retrospective, comparative analysis at short-term follow-up. J Arthroplasty. 2019;34(12): 3012-17.*

*5. Bakirhan S, Angin S, Karatosun V, Unver B, Günal I. A comparison of static and dynamic balance in patients with unilateral and bilateral total knee arthroplasty. Eklem Hastalik Cerrahisi. 2009;20(2):93-101.*

*6. Bozic KJ, Kurtz SM, Lau E, Ong K, Chiu V, Vail TP, et.al. The epidemiology of revision total knee arthroplasty in the United States. Clin Orthop Relat Res. 2010;468(1):45-51.*

*7. Mortazavi SM, Molligan J, Austin MS, Purtill JJ, Hozack WJ, Parvizi J. Failure following revision total knee arthroplasty: infection is the major cause. Int Orthop. 201;35(8):1157-64.*

*8. Kim YH, Kim JS. Revision total knee arthroplasty with use of a constrained condylar knee prosthesis. J Bone Joint Surg Am. 2009;91(6):1440-7.*

*9. Kouk S, Rathod PA, Maheshwari AV, Deshmukh AJ. Rotating hinge prosthesis for complex revision total knee arthroplasty: a review of the literature. J Clin Orthop Trauma. 2018;9(1): 29-33.*

*10. Pasquier G, Ehlinger M, Mainard D. The role of rotating hinge implants in revision total knee arthroplasty. EFORT Open Rev. 2019;4(6):269-78.*

*11. Mancino F, De Martino I, Burrofato A, De Ieso C, Saccomanno MF, Maccauro, G et. al. Satisfactory mid-term outcomes of condylar-constrained knee implants in primary total knee arthroplasty: clinical and radiological follow-up. J Orthop Traumatol. 2020;21(1):22.*

*12. Lachiewicz PF, Soileau ES. Results of a second-generation constrained condylar prosthesis in primary total knee arthroplasty. J Arthroplasty. 2011; 26(8):1228-31.*

*13. Hermans K, Vandenneucker H, Truijen J, Oosterbosch J, Bellemans J. Hinged versus CCK revision arthroplasty for the stiff total knee. Knee. 2019 ;26(1):222-7.*

*14. Yoon JR, Cheong JY, Im JT, Park PS, Park JO, Shin YS. Rotating hinge knee versus constrained condylar knee in revision total knee arthroplasty: A meta-analysis. PLoS One. 2019;14(3):e0214279.*

*15. Badawy M, Fenstad AM, Furnes O. Primary constrained and hinged total knee arthroplasty: 2-and 5-year revision risk compared with unconstrained total knee arthroplasty: a report on 401 cases from the Norwegian Arthroplasty Register 1994–2017. Acta Orthop. 2019;90(5): 467-72.*

*16. Bourne RB, Crawford HA. Principles of revision total knee arthroplasty. Orthop Clin North Am. 1998;29(2):331-7.*

*17. Guenoun B, Latargez L, Freslon M, Defossez G, Salas N, Gayet LE. Complications following rotating hinge Endo-Modell (Link) knee arthroplasty. Orthop Traumatol Surg Res. 2009;95(7):529-36.*

*18. Malcolm TL, Bederman SS, Schwarzkopf R. Outcomes of varus valgus constrained versus rotating-hinge implants in total knee arthroplasty. Orthopedics. 2016;39(1):e140-8.*

*19. Morgan H, Battista V, Leopold SS. Constraint in primary total knee arthroplasty. J Am Acad Orthop Surg. 2005;13(8):515-24.*

*20. Vasso M, Beaufils P, Schiavone Panni A. Constraint choice in revision knee arthroplasty. Int Orthop. 2013;37(7):1279-84.*

*21. Daines BK, Dennis DA. Management of bone defects in revision total knee arthroplasty. J Bone Joint Surg Am. 2012 20;94(12):1131-9.*

*22. Farfalli GL, Aponte-Tinao LA, Ayerza MA, Muscolo DL, Boland PJ, Morris CD, et.al. Comparison between constrained and semiconstrained knee allograft-prosthesis composite reconstructions. Sarcoma. 2013;2013:489652.*

*23. Bali K, Naudie DD, Howard JL, McCalden RW, MacDonald SJ, Teeter MG. Comparison of Tibial Insert Polyethylene Damage in Rotating Hinge and Highly Constrained Total Knee Arthroplasty: A Retrieval Analysis. J Arthroplasty. 2016;31(1):290-4.*

*24. Shen C, Lichstein PM, Austin MS, Sharkey PF, Parvizi J. Revision knee arthroplasty for bone loss: choosing the right degree of constraint. J Arthroplasty. 2014;29(1):127-31.*

***How to cite this article:***

***Mahmut Özdemir, Yüksel Uğur Yaradılmış, Ahmet Ateş, Ali Teoman Evren, Mustafa Caner Okkaoğlu, Murat Altay.*** *Hinged prosthesis in the knee revision surgery: Is there a great need? Ann Clin Anal Med 2022; DOI: 10.4328/ACAM.20990*