Annals of Clinical and Analytical Medicine
Original Research

Endoscopy-assisted suturectomy for craniosynostosis treatment: A single-center experience

Endoscopy-assisted suturectomy in the treatment of craniosynostosis

Harun Demirci[1], Pelin Kuzucu[2], Atilla Kazancı[1], Pınar Özışık[1]
[1] Department of Neurosurgery, Faculty of Medicine, Ankara Yıldırım Beyazıt Unıversity, Ankara
[2] Clinic of Neurosurgery, Birecik State Hospital, Şanlıurfa, Turkey

Abstract
Aim: Craniosynostosis is a clinical condition that occurs after premature fusion of fibrous tissue at the suture line. This study aimed to present the management and method of patients with craniosynostosis in our center.
Material and Methods: This study retrospectively reviewed 89 patients who underwent surgery at Ankara City Hospital Children's Hospital between 2020 and 2021. The age, gender, diagnosis, length of hospital stay, surgical duration, and the amount of needed transfusion of patients were recorded.
Results: Sagittal synostosis was determined in 45 (50.5%) patients, metopic in 32 (36%), coronal in 10 (11.3%), and lambdoid in 2 (2.2%) synostosis. Endoscopy-assisted suturectomy is a safe, easy, and comfortable surgical treatment option for craniosynostosis.
Discussion: Endoscopy-assisted suturectomy is a safe, easy, and comfortable surgical treatment option for craniosynostosis.

Keywords
Endoscopy-Assisted Suturectomy, Craniosynostosis, Sagittal Synostosis, Metopic Synostosis, Coronal Synostosis

DOI: 10.4328/ACAM.21232 Received: 2022-05-17 Accepted: 2022-06-28 Published Online: 2022-07-18
Corresponding Author: Pelin Kuzucu, Department of Neurosurgery, Birecik State Hospital, Şanlıurfa, Turkey.
E-mail: drpelinkuzucu@gmail.com P: +90 505 704 13 38
Corresponding Author ORCID ID: https://orcid.org/0000-0003-0484-3753

Introduction

Craniosynostosis is a clinical condition that occurs after early fusion of fibrous tissue at the suture line [1]. The incidence of craniosynostosis is 1 in 2500 live births. In healthy newborns, rapid brain growth in the first year of life creates a thrust on the skull bones, thus preventing suture fusion [2]. This thrust force cannot be effective in the affected area due to premature suture closure. Visual deterioration and increased intracranial pressure are observed due to growth pattern deterioration in the pathological area [3]. Vault reconstruction surgery (VRS) is traditionally used for craniosynostosis. In our country, this method can be successfully applied in a limited number of health centers. Vault modeling and fronto-orbital advancement surgery have more successful results when performed under 1 year old. However, it carries risks for the age group in the treatment target. The surgical duration, the high risk of blood loss, and the need for intensive postoperative care are the main factors in the limited number of treatment centers. Since 1990, minimally invasive endoscopy-assisted suturectomy (EAS) has been performed. Many studies have reported significant gains in surgical duration, blood loss, and hospital stay. This single-center study aimed to determine the safety of EAS surgery, which can be performed relatively easily compared to VRS and can be performed in many hospitals in our country.

Material and Methods

A retrospective review of 89 patients who underwent surgery in Ankara City Hospital Children's Hospital from 2020 to 2021 was conducted. Our study was approved by the ethics committee of Ankara Yıldırım Beyazıt University.

Patients' age at admission and treatment, gender, diagnosis, length of hospital stay, surgical duration, and amount of needed transfusion were noted. The duration of helmet use, which is a complementary postoperative treatment procedure, was determined.

Surgical Techniques

Sagittal Craniosynostosis

All patients were operated on under general anesthesia and were placed on the surgical table in the prone position using soft gel support. 2–3 cm behind the anterior fontanel and 2 cm in front of the lambda, two incision lines of 4 cm were determined, which perpendicularly cut the sagittal suture (Figure 1A,2A). The periosteum between the incision lines was dissected. A 0-degree 4-mm thick endoscopic camera was used (Karl Storz, Germany). The bone bar was removed using Kerrison rongeur, bone scissors, and ultrasonic bone cutters. Barrel osteotomies were performed behind the coronal suture and in front of the lambdoid suture, parallel to the sutures.

Metopic Craniosynostosis

All patients were operated on under general anesthesia and were placed on the surgical table in the supine position using soft gel support. A 3-cm incision was made 2 cm in front of the anterior fontanel to perpendicularly cut the metopic suture (Figure 1A,2B). Periosteal dissection was performed up to the nasion. A 0-degree 4-mm thick endoscopic camera was used (Karl Storz, Germany). A wedge-shaped bone excision was performed posteriorly at the width of the incision line and anteriorly at the width of the nasion region (approximately 0.7 mm).

Coronal Craniosynostosis

All patients were operated on under general anesthesia and were placed on the surgical table in the supine position using soft gel support. A coronal suture was determined. In the middle of the coronal suture line, a 2-cm incision line was determined to perpendicularly cut the suture (Figure 1A,2C). A periosteal dissection was performed up to the anterior fontanel and squamous suture. A 0-degree 4-mm thick endoscopic camera was used (Karl Storz, Germany). A 1-cm wide bone excision was performed from the fontanel to the squamous suture.

Ringer's lactated solution irrigation and bleeding control were achieved after the bone excision of all patients. Hemostatic agents to stop bleeding were used and the skin was subcuticularly closed.

Results

The treatment was completed in 53 patients, and 36 continue the treatment at various stages. Patients were hospitalized for preoperative preparations the day preoperatively and coronavirus disease-19 tests were studied. Surgery was delayed for 7–10 days due to positive results in 7 patients. Patients whose anesthesia preparations were completed were accepted for surgery. All patients were operated on under general anesthesia. Anesthesia preparation took an average of 23 min. Patients were followed up with bispectral index, which monitors the anesthesia.

Sagittal synostosis was determined in 45 (50.5%) patients, metopic in 32 (36%), coronal in 10 (11.3%), and lambdoid in 2 (2.2%). Of all patients, 59 (66.3%) were males and 30 (33.7%) were females. Male and female made up 27 (60%) and 18 (40%) in sagittal, 28 (87.5%) and 4 (12.5%) in metopic, 4 (40%) and 6 (60%) in coronal, and 0 and 2 (100%) in lambdoid synostoses, respectively. In coronal synostosis, 3 patients were right (30%), 6 were left (60%), and 1 patient was bicoronal (10%) (Table1).

Patients with sagittal synostosis had a mean age at hospital admission of 50 days, mean age at surgery of 94 days, mean surgical duration of 35 min, mean bleeding of 20 ml, mean

Table 1. Results during treatment by type of craniosynostosis

	Sagittal Synostosis	Metopic Synostosis	Coronal Synostosis
Ratio in cases (N:89)	50,5% (45)	36% (32)	11,3% (10)
Male/Female ratio (total: 66,3/33,7)	60/40	87,5/12,5	40/60
Mean admission age	50 days	38 days	61 days
Mean surgery age	94 days	71 days	83 days
Mean surgery time	35 minutes	40 minutes	30 minutes
Mean bleeding	20 ml	30 ml	15 ml
Mean hospital-stay	40 hours	40 hours	40 hours
Mean blood replacement	5 ml/kg	10 ml/kg	5 ml/kg
Complications	One dural injury	One dural injury	No complication Right side: 30% Left side: 60% Bi-coronal: 10%

postoperative hospital stay of 40 h, mean blood replacement of 5 ml/kg. None of the patients needed intensive care. The dural injury occurred in 1 patient, which was repaired by primary suturing. The preoperative cephalic index (medial-lateral length/anterior-posterior length) of the patients was 0.69 on average, whereas 0.83 postoperatively (Figure 1A).

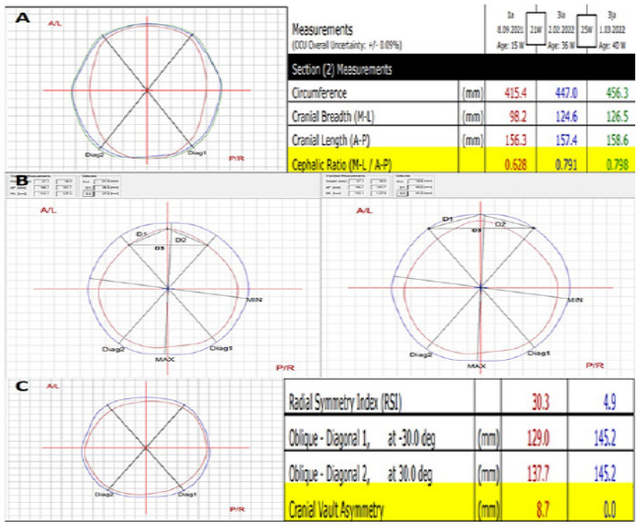

Figure 1. A: Treatment follow-up for sagittal synostosis. Red scan pre-treatment, blue scan 19 weeks postoperatively, and green scan 23 weeks postoperatively. B: Treatment follow-up for metopic synostosis. D1; distance between the midpoint and diagonal 1 contact point. D2; distance between the midpoint and diagonal 2 contact point. D3; distance between diagonal contact points. Red scan pre-treatment, blue scan post-treatment. C: Treatment follow-up for coronal synostosis. Red scan pre-treatment, blue scan 21 weeks postoperatively.

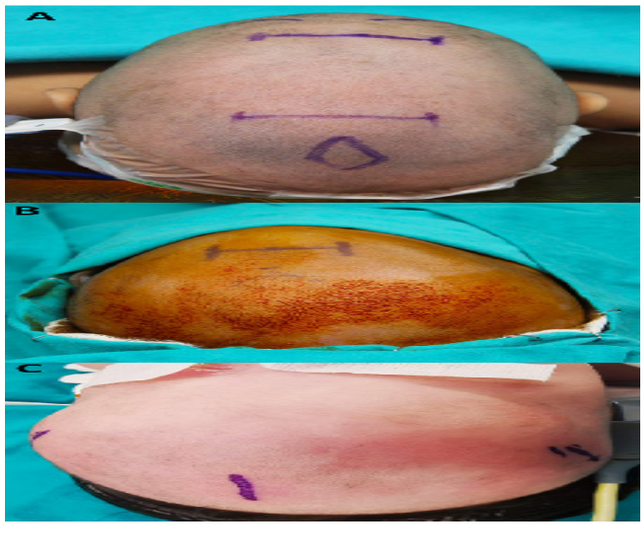

Figure 2. A: A photographic image of a patient with preoperative sagittal synostosis. Written and oral consent was obtained from the patient's family for the use of photographs. B: A photographic image of a patient with preoperative metopic synostosis. Written and oral consent was obtained from the patient's family for the use of photographs. C: A photographic image of a patient with preoperative coronal synostosis. Written and oral consent was obtained from the patient's family for the use of photographs.

The average helmet use duration postoperatively was calculated as 7.6 months. All patients were measured at 2-week intervals. Patients with metopic synostosis had a mean age at hospital admission of 38 days, mean age at surgery of 71 days, mean surgical duration of 40 min, mean bleeding of 30 ml, mean postoperative hospital stay of 40 h, and mean blood replacement of 10 ml/kg. None of the patients needed intensive care. The dural injury occurred in 1 patient, which was repaired by primary suturing. Based on the theorem "In triangles, the opposite of the large angle is the large edge," data after the comparison of the 30-degree diagonal diameter of the lines drawn between the frontal contact points and the midline with the distance between these two points, while the mean before the treatment was 1.74, the average after the treatment was obtained, which was 1.87 (Figure1B). The average helmet use duration postoperatively was calculated as 8.5 months. All patients were measured at 2-week intervals.

Patients with coronal synostosis had a mean age at hospital admission of 61 days, mean age at surgery of 83 days, mean surgical duration was 30 min, mean bleeding was 15 ml, mean postoperative hospital stay was 40 h, and mean blood replacement was 5 ml/kg. None of the patients needed intensive care. The mean diagonal asymmetry of patients preoperatively was 5.3 mm, and the mean diagonal asymmetry at the end of the treatment was 0.9 mm. (Figure 1C) The mean helmet use duration postoperatively was 8.7 months. All patients were measured at 2-week intervals.

Discussion

The emerging results of this study show that EAS is a safe and effective surgical method for patients with craniosynostosis. With the developments in technology, minimally invasive techniques have been applied more frequently in all surgical branches. EAS has become widespread in non-syndromic craniosynostoses [2, 4]. According to a multicenter retrospective study, the length of hospital stay of 933 patients treated with EAS was significantly reduced [5]. This result supports our study results, which revealed a mean postoperative hospital stay of 40 h. Vogel et al. found that the cost of EAS was less than that of VRS [6].

Some studies that use non-invasive ultrasonography revealed a reduced risk of venous embolism in EAS surgeries compared to VRS, which is compatible with the safe surgery doctrine [7, 9].

A cosmetic analysis by Tan et al. for unilateral coronal craniosynostosis revealed no significant difference between dome reconstruction surgery and EAS [10]. In our study, the diagonal diameter difference was significantly reduced.

Comparison of VRS and EAS surgery performed on metopic synostoses revealed a reduction in blood loss, surgical time, and hospital stay, in line with our study results [11, 12].

Evaluation of cosmetic results by Farber et al. revealed no significant difference between the two methods of frontal deconstruction and expansion [13]. However, an angular increase was seen in the analysis of our series.

Garber et al. showed no difference in complications between VRS and EAS surgery for sagittal synostosis [13].

Ghenbot et al. reported no significant difference in the cephalic index results at the end of the treatment [15].

Conclusion

In craniosynostosis treatment, EAS has been an alternative, as described in this and many other studies, as a safe, relatively easy, and comfortable surgery. Dome reconstruction surgery cannot be performed in many health centers due to the absence or insufficiency of pediatric intensive care units and limited anesthesia conditions. Craniosynostosis treatments are thought to be performed in many health centers with the EAS method, which is relatively easier to perform compared to dome reconstruction surgery. Considerably, with the surgical prevalence, helmet service providers will become more widespread and post-op follow-up of patients will be more comfortable for families.

Acknowledgment
We certify that the content of this manuscript, in part or in full, has not been submitted to any other journal in any form, and its publication has been approved by all co-authors. Preparation for publication of this article is partly supported by Turkish Neurosurgical Society.

Scientific Responsibility Statement
The authors declare that they are responsible for the article's scientific content including study design, data collection, analysis and interpretation, writing, some of the main line, or all of the preparation and scientific review of the contents and approval of the final version of the article.

Animal and human rights statement
All procedures performed in this study were in accordance with the ethical standards of the institutional and/or national research committee and with the 1964 Helsinki declaration and its later amendments or comparable ethical standards. No animal or human studies were carried out by the authors for this article.

Funding: *None*

Conflict of interest
None of the authors received any type of financial support that could be considered potential conflict of interest regarding the manuscript or its submission.

References

1. Cohen MM, MacLean RE, editors. Craniosynostosis: Diagnosis, Evaluation, and Management. 2nd ed., Oxford, Oxford University Press; 2000.
2. Nellhaus G. Head circumference from birth to eighteen years. Practical composite international and interracial graphs. Pediatrics. 1968;41(1):106-14.
3. Sidoti EJ, Marsh JL, Marty-Grames L, Noetzel MJ. Long-term studies of metopic synostosis: frequency of cognitive impairment and behavioral disturbances. Plast Reconstr Surg. 1996;97(2):276-81. DOI:10.1097/00006534-199602000-00002
4. Hentschel S, Steinbok P, Cochrane DD, Kestle J. Reduction of transfusion rates in the surgical correction of sagittal synostosis. J Neurosurg. 2002;97(3):503-9. DOI:10.3171/jns.2002.97.3.0503
5. Thompson DR, Zurakowski D, Haberkern CM, Stricker PA, Meier PM, Bannister C, et al. Endoscopic Versus Open Repair for Craniosynostosis in Infants Using Propensity Score Matching to Compare Outcomes: A Multicenter Study from the Pediatric Craniofacial Collaborative Group. Anesth Analg. 2018;126(3):968-75. DOI:10.1213/ANE.0000000000002454
6. Vogel TW, Woo AS, Kane AA, Patel KB, Naidoo SD, Smyth MD. A comparison of costs associated with endoscope-assisted craniectomy versus open cranial vault repair for infants with sagittal synostosis. J Neurosurg Pediatr. 2014;13(3):324-31. DOI:10.3171/2013.12.PEDS13320
7. Faberowski LW, Black S, Mickle JP. Incidence of venous air embolism during craniectomy for craniosynostosis repair. Anesthesiology. 2000;92(1):20-3. DOI:10.1097/00000542-200001000-00009
8. Shah MN, Kane AA, Petersen JD, Woo AS, Naidoo SD, Smyth MD. Endoscopically assisted versus open repair of sagittal craniosynostosis: the St. Louis Children's Hospital experience. J Neurosurg Pediatr. 2011;8(2):165-70. DOI:10.3171/2011.5.PEDS1128
9. Tobias JD, Johnson JO, Jimenez DF, Barone CM, McBride DS. Venous air embolism during endoscopic strip craniectomy for the repair of craniosynostosis in infants. Anesthesiology. 2001;95(2):340-2. DOI:10.1097/00000542-200108000-00013
10. Tan SPK, Proctor MR, Mulliken JB, Rogers GF. Early frontofacial symmetry after correction of unilateral coronal synostosis: frontoorbital advancement vs endoscopic strip craniectomy and helmet therapy. J Craniofac Surg. 2013;24(4):1190-4. DOI:10.1097/SCS.0b013e318299742e
11. Arts S, Delye H, van Lindert EJ. Intraoperative and postoperative complications in the surgical treatment of craniosynostosis: minimally invasive versus open surgical procedures. J Neurosurg Pediatr. 2018;21(2):112-18. DOI:10.3171/2017.7.PEDS17155
12. Keshavarzi S, Hayden MG, Ben-Haim S, Meltzer HS, Cohen SR, Levy ML. Variations of endoscopic and open repair of metopic craniosynostosis. J Craniofac Surg. 2009;20(5):1439-44. DOI:10.1097/SCS.0b013e3181af1555
13. Farber SJ, Nguyen DC, Skolnick GB, Naidoo SD, Smyth MD, Patel KB. Anthropometric Outcome Measures in Patients With Metopic Craniosynostosis. J Craniofac Surg. 2017;28(3):713-16. DOI:10.1097/SCS.0000000000003495
14. Garber ST, Karsy M, Kestle JRW, Siddiqi F, Spanos SP, Riva-Cambrin J. Comparing Outcomes and Cost of 3 Surgical Treatments for Sagittal Synostosis: A Retrospective Study Including Procedure-Related Cost Analysis. Neurosurgery. 2017;81(4):680-7. DOI:10.1093/neuros/nyx209
15. Ghenbot RG, Patel KB, Skolnick GB, Naidoo SD, Smyth MD, Woo AS. Effects of open and endoscopic surgery on skull growth and calvarial vault volumes in sagittal synostosis. J Craniofac Surg. 2015;26(1):161-4. DOI:10.1097/SCS.0000000000001236

How to cite this article:
Harun Demirci, Pelin Kuzucu, Atilla Kazancı, Pınar Özışık. *Endoscopy-assisted suturectomy for craniosynostosis treatment: A single-center experience. Ann Clin Anal Med 2022; DOI: 10.4328/ACAM.21232*