Annals of Clinical and Analytical Medicine
Original Research

Association between the atrial septal aneurysm and frequent premature ventricular complexes

Isa Ardahanli[1], Murat Ozmen[2], Onur Akgun[3], Davut Karakurt[4], Rafig Gurbanov[5], Olgica Mihaljevic[6]
[1] Department of Cardiology, Faculty of Medicine, Seyh Edebali University, Bilecik, Turkey
[2] Department of Cardiology, Erzurum City Hospital, Erzurum, Turkey
[3] Department of Cardiology, Ankara Training and Research Hospital, Ankara, Turkey
[4] Department of Cardiology, Ataturk State Hospital, Sinop, Turkey
[5] Department of Bioengineering, Seyh Edebali University, Bilecik, Turkey
[6] Department of Pathophysiology, Faculty of Medical Sciences, University of Kragujevac, Kragujevac, Serbia

Abstract

Aim: Atrial septal aneurysm (ASA) is a rare congenital malformation consisting of excess atrial septal tissue protruding into the right or left atrium and has been described as an association between cardiac arrhythmias. Premature ventricular contractions (PVCs), which are common in the general and patient population, are irregular heartbeats that indicate potential heart diseases. Frequent PVCs can often cause a reversible form of cardiomyopathy. Our study aimed to compare the incidence of frequent PVC with healthy volunteers after 24-hour rhythm Holter monitoring in patients diagnosed with ASA by transthoracic echocardiography (TEE).

Material and Methods: Fifty-eight patients between the ages of 18-65 who applied to our clinic and were diagnosed with ASA in TTE were included in the study. The control group was composed of 58 non-ASA volunteer participants. All participants underwent a complete physical examination and 12-lead surface electrocardiography was performed. All participants, whose clinical indications were met, underwent 24-hour rhythm Holter monitoring. The presence of PVC in more than 5% of all heartbeats in 24 hours in Holter recordings was defined as frequent PVC.

Results: The mean age in the study group was (50.68 ± 11.55) years. Age, gender, and clinical findings were similar in both groups. There was no significant difference between parameters in echocardiographic evaluation. In 24-hour rhythm Holter monitoring, the number of those who met the definition of frequent PVC was higher in the ASA group compared to the non-ASA group (n=17 (29.3%) vs. n=7, (12.1%), p<0.001).Discussion: Our study showed that frequent PVCs were significantly higher in 24-hour ambulatory ECG monitoring in ASA patients compared to the control group. We think that patients with ASA detected on TTE should be examined in terms of arrhythmia and should be aware of the risk of PVC-related cardiomyopathy.

Keywords

Atrial Septal Aneurysm, Frequent Premature Ventricular Complex, Ventricular Arrhythmia

DOI: 10.4328/ACAM.21314 Received: 2022-07-15 Accepted: 2022-08-31 Published Online: 2022-09-03
Corresponding Author: Isa Ardahanli, Pelitözü Location, Fatih Sultan Mehmet Boulevard, No:25/A, 11040, Bilecik, Turkey.
E-mail: isaardahanli@gmail.com P :+90 533 576 83 25 F: +90 228 202 33 66
Corresponding Author ORCID ID: https://orcid.org/0000-0002-9309-803X

Introduction

Premature ventricular complexes (PVCs) are the most common type of ventricular arrhythmia and are found in most healthy individuals [1,2]. In the absence of structural heart disease, PVC is considered relatively benign. However, in the case of underlying heart diseases such as previous myocardial infarction and heart failure, it may be an indicator of poor prognosis [3,4]. It is known that frequent PVCs can cause cardiomyopathy if not treated. Frequent PVC definitions may differ in the literature [5,6]. In our study, PVC was defined as more than 5% of all QRS complexes on standard 24-hour Holter monitoring.

Atrial septal aneurysm (ASA) is a redundant or saccular deformity of the atrial septum and is associated with increased mobility of atrial septal tissue. ASA is defined as more than a 10 mm extension of septal tissue (typically fossa ovalis) from the plane of the atrial septum to the right or left atrium, or a total extension of 15 mm on the right and left [7]. The prevalence of ASA is 2-3% in the general population [8,9]. The clinical significance of ASA has been associated with an increased prevalence of cryptogenic stroke and other embolic events. Another important clinical finding is that cardiac arrhythmias frequently accompany ASA. It is estimated that the wavy movements of the atrial septum caused by stretching initiate these arrhythmias. Although there are many studies in the literature investigating the relationship between ASA and arrhythmias, there is no study investigating the relationship between frequent idiopathic PVC.

In our study, we aimed to investigate the relationship between ASA and frequent idiopathic PVC with the help of 24-hour rhythm Holter monitoring and to compare it with the non-ASA control group.

Material and Methods

This study was designed as single-center, prospective and observational study. Our study was performed on fifty-eight patients aged between 18-65 years, who applied to the cardiology outpatient clinic between September 2021 and March 2022, and had ASA detected in transthoracic echocardiographic (TTE) imaging. As the control group, age and gender-matched fifty-eight non-ASA participants were included in the study. The study was carried out in accordance with the Declaration of Helsinki. Ethics committee approval was obtained from Bilecik Şeyh Edebali University (Approval number: 050.01.04-95175).

All participants in the study group underwent a complete physical examination and their medical histories were questioned. Clinical, demographic characteristics, and drug use histories were questioned. The obtained data were recorded on a worksheet. Arterial blood pressure measurements were made after at least 10 minutes of rest. Arterial hypertension was defined as repeated blood pressure measurements ≥140/90 mmHg or the use of antihypertensive drugs. Body mass indexes were calculated by measuring height and weight (BMI = kg/m2) and recorded. All participants were informed about the study and their written consent was obtained. Figure 1 shows the image of ASA in TTE.

Criteria for exclusion from the study: • Heart failure with reduced ejection fraction (LVEF ≤ 40%), and heart failure with mid-range ejection fraction (LVEF between 41% – 49%).

- History of previous cardiac surgery.
- Moderate to severe heart valve disease.
- Severe anemia (Hg< 11 gr/dL).
- Patients implanted with ICD, CRT.
- Pulmonary hypertension (sPAP >20 mm-Hg).
- History of antiarrhythmic drug use.
- Advanced chronic obstructive pulmonary disease (COPD) and cor pulmonale.
- History of previous pulmonary embolism.
- Active infection.
- Pregnancy.
- Left bundle branch block (Asynchronous contractions may be confused with arrhythmias).
- Heavy artifact on 24-hour Holter monitoring.
- Poor echogenicity and poor image quality.

Electrocardiographic and transthoracic echocardiographic evaluation

A standard 12-lead superficial ECG was taken in the supine position after rest for at least 20 minutes in the entire study population. ECG recordings were made using the Nihon Kohden (Tokyo, Japan) branded device at a paper speed of 25 mm/s and a voltage of 10 mm/mV. To avoid diurnal variations, we generally evaluated the ECG recordings at the same time (09:00-10:00 AM).

PVC was defined as a wide QRS complex (>120 ms) with abnormal morphology and discordant ST-segment and T wave changes on ECG (Figure 2). Transthoracic echocardiography was performed on all participants in the study group. Echocardiographic examinations were performed in the Department of Cardiology Echocardiography Laboratory using the EPIQ 7 echocardiography device (Philips, Amsterdam, Netherlands). All echocardiographic measurements were performed in the left lateral decubitus position as recommended by the American Society of Echocardiography. Left atrium, ascending aorta diameter, left ventricular end-systolic and end-diastolic diameters, interventricular septum, and posterior wall were measured with parasternal long-axis imaging. Left ventricular ejection fraction was measured with the modified Simpson's method. ASA was defined as a protrusion of the interatrial septum to the left or right atrium by more than 15 mm along with the cardiac cycle on apical four-chamber imaging [7].

Ambulatory 24-hours rhythm monitoring

All participants in the study group underwent 12-lead 24-hour ambulatory ECG rhythm monitoring (Cardioline S.P.A Walk 400H). Pause, ectopic beat, and all normal beats were manually verified. Artifacts and missing signals for more than 2 hours were defined as insufficient recording and repeated. Frequent VPC was defined as more than 5% of all QRS complexes on standard 24-hour Holter monitoring.

Statistical analysis

All statistical analyses were performed using GraphPad Prism 8.01 (GraphPad Software, San Diego, CA, USA) software. Continuous variables were expressed as mean ± SD and categorical variables were presented as counts and/or percentages. A comparison of parametric values between the two groups was performed through an unpaired t-test (one-tailed). Categorical variables were compared using the chi-

square test. P < 0.05 and P < 0.01 were considered as statistical significance. The receiver operator characteristic (ROC) analysis was used to select a cutoff value distinguishing common TB and VPC parameters from aberrant ones in ASA (+) and ASA (-) groups [10]. A tradeoff of sensitivity versus specificity was conceived as a ROC curve. The area under the curve (AUC) of 95% confidence was evaluated, estimating the overall ability of the test to differentiate the ASA (+) group from the control ASA (-) group.

Results

The mean age of the study population was 50.68 ± 11.55 years. The mean age of the ASA(+) and control groups was similar (respectively, 50.53 ± 11.69 years vs 50.83 ± 11.41). The gender numbers of males and females were similar in those with ASA (+). Again, gender distribution was similar in the non-ASA group. Transthoracic echocardiographic measurements of the study population did not differ significantly between the groups. Demographic and clinical characteristics and echocardiographic measurements of the groups are presented in Table 1.

During the study, no patient had a simultaneous atrial fibrillation attack or ventricular tachycardia attack in holter analysis. In the 24-hour ambulatory ECG monitoring, the total heart rate was significantly higher in the group with ASA (121396 ± 26345 (beats/day) vs. 111397 ± 19604 (beats/day), p = 0.0111). In the ASA group, the mean number of PVCs in 24 hours was statistically significantly higher than in the non-ASA group. (2345 ± 399 vs. 1129 ± 291, p=0.0078).

The number of people with frequent PVCs was significantly higher in the ASA + group (n=17 vs n=7, respectively, p <0.0001). In the ROC curve analysis, total beats and PVCs showed significant specificity in the ASA (+) group. The comparative statistical analysis of the groups is shown in Figure 3.

Table 1. Baseline demographics and echocardiographic parameters of the study population.

	ASA (+) group (58) (Mean ± SD)	ASA (-) group (58) (Mean ± SD)	p-value
Age (years)	50.53 ± 11.69	50.83 ± 11.41	.4458
SBP (mm-Hg)	127.30 ± 11.18	126.10 ± 13.53	.3008
DBP (mm-Hg)	75.52 ± 9.54	75.93 ± 10.91	.4141
Aortic diameter (mm)	33.78 ± 3.73	33.26 ± 3.53	.2225
Left atrium (mm)	36.53 ± 3.40	37.45 ± 4.04	.0955
LVDD (mm)	46.21 ± 4.72	45.84 ± 4.65	.3392
IVS (mm)	0.86 ± 0.17	0.89 ± 0.15	.1314
PW (mm)	0.88 ± 0.17	0.87 ± 0.15	.4551
LVEF (%)	62.19 ± 3.35	61.93 ± 3.36	.3396
sPAP	14.90 ± 2.26	14.33 ± 2.09	.0818
Total beats (pulse/24 hours)	121396 ± 26345	111397 ± 19604	.0111*
Total PVCs	2345 ± 399	1129 ± 291	.0078**
Frequent PVC (n, %)	17 (%29.3)	7 (%12.1)	<.0001**
Sex (female) (n, %)	30 (51.7%)	30 (51.7%)	–

SBP: systolic blood pressure; DBP: diastolic blood pressure; LVEDD: left ventricular end-diastolic diameter; IVS: interventricular septum; PW: posterior wall; LVEF: left ventricular ejection fraction; sPAP: systolic pulmonary artery pressure; PVC: premature ventricular contraction. The degree of significance was denoted as *p < 0.05 and **p < 0.01.

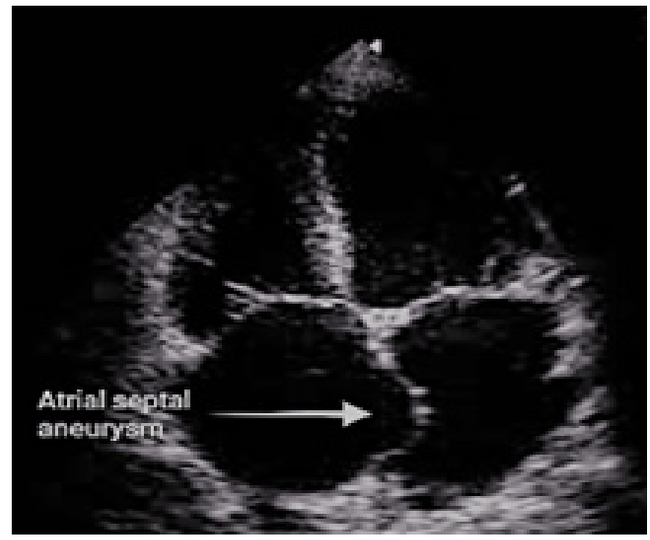

Figure 1. Transthoracic echocardiographic image of atrial septal aneurysm

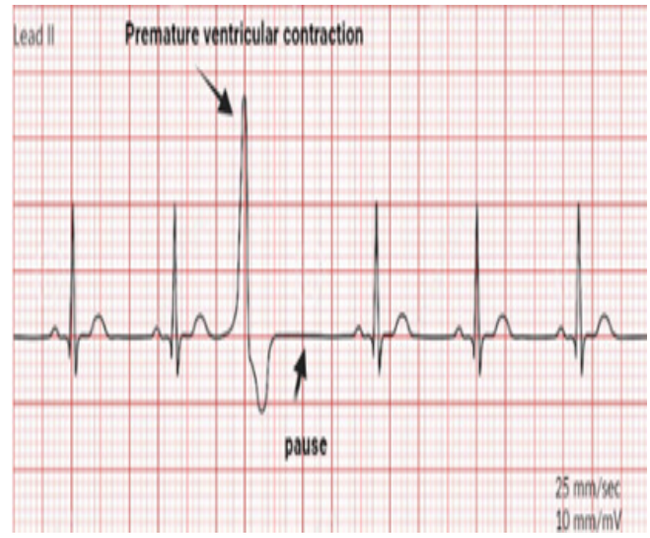

Figure 2. Premature ventricular contraction on ECG

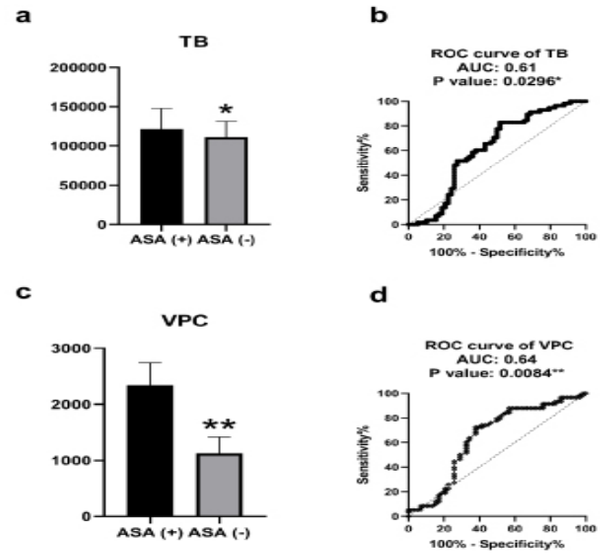

Figure 3. The comparative statistical analysis of the study groups

Discussion

The most important novel finding of this study is the statistically significantly increased frequency of idioventricular PVCs in patients with ASA compared to control subjects without ASA. To our knowledge, this is the first study in the literature to investigate the association of ASA with frequent idiopathic PVC using 24-hour rhythm Holter monitoring and compare it with healthy individuals.

PVCs are a type of ventricular arrhythmia that is very common in the general population and rarely gives symptoms unless there is underlying structural heart disease. In the case of underlying structural heart disease, it may be an indicator of poor prognosis [11]. The increase in the frequency of PVC causes cardiomyopathy and increases mortality due to all causes [12,13].

It has been reported in previous studies that ASA, which is a congenital cardiac defect and can often be diagnosed with TTE, is associated with many clinical conditions. These include atrial septal defect, patent foramen ovale, mitral valve prolapse, stroke, and cardiac arrhythmias [14-16]. The relationship between ASA and cardiac arrhythmias has been reported in some previous studies. Russo V et al. reported in their study that P wave dispersion was significantly longer in ASA patients compared to the control group and that atrial electromechanical delay may have a role in ASA [17]. Unlike our study, this study was designed only for paroxysmal supraventricular arrhythmias. Morelli et al showed increased episodes of arrhythmia during a 24-hour Holter in their study of twenty ASA patients. In the study, it was shown that all patients with ASA were accompanied by one or more of any type of arrhythmia. PVC was detected in 12 patients (60%) [18]. However, as it is known, in the 24-hour rhythm holter, rare PVC can be found in up to 75% of even normal individuals. Unlike this study, we evaluated those with frequent PVC (>5% PVC of all heartbeats). In addition, the population constituting our study group was higher in number.

In a study examining patients with paroxysmal and persistent AF, it was reported that IAS had structural anomalies at a rate of 43%, and approximately 59% of them had ASA [19]. In another recent study investigating the relationship between ASA and arrhythmia, atrial premature complexes and supraventricular tachycardia were found to be significantly increased in patients with ASA. Again in this study, it was reported that PVCs were observed significantly more. While it was approximately 5% in ASA patients, this rate was 2% in the healthy group [20]. In our study, the PVC rate was found to be higher in ASA patients. The reason for this difference may be that most of the individuals participating in the study did not use 24-hour Holter recording in the evaluation of arrhythmia. In addition, in our study, those who had PVC more than 5% of all beats in 24-hour Holter recordings (frequent PVC) were included in the study.

The pathophysiological mechanisms of cardiac arrhythmias due to structural abnormalities of the interatrial septum are not yet clearly known. However, some studies in the literature have focused on investigating the underlying mechanism. Mitrofanova et al. reported in their study in 40 postmortem patients that the interatrial septum had atypically shaped muscle fibers composed of working cardiomyocytes [21]. According to the results of this study, we can think that atypical myocytes with conduction system characteristics are located in the interatrial septum, which is effective in the development of arrhythmia. Again, it is a possible pathophysiological mechanism that can induce arrhythmogenesis by irritating the surrounding tissues as a result of the physical movement of the aneurysmatic tissue during the cardiac cycle. As a matter of fact, in a recent case report, it was reported that a large ASA protruding into the left atrium contacted the back of the left atrium along with the cardiac cycle and induced tachycardia [22]. In addition to mechanical irritation of the interatrial septum, another reason why arrhythmias are often seen together in ASA may be accompanied by genetic mutational damage.

Conclusion

As a result, we found that idiopathic frequent PVCs were more common in patients diagnosed with ASA in TTE than in the age- and the sex-matched healthy control group without ASA. We think that patients with ASA detected on echocardiography should be followed closely regarding ventricular arrhythmias. In addition, further experimental and large-scale clinical studies are required to elucidate the possible pathophysiological mechanisms of PVC being observed more frequently in ASA patients.

Limitations

Our study has some limitations. The main limitation was that the study was single-center and only TTE was used in the diagnosis of ASA. The transesophageal echocardiographic evaluation may be required in suspicious cases that cannot be detected in TTE. Another limitation was the use of only 24-hour rhythm Holter monitoring for the diagnosis of frequent PVCs due to the design of the study. With the help of electrophysiological studies, the number of patients diagnosed with frequent PVC could be higher.

Scientific Responsibility Statement

The authors declare that they are responsible for the article's scientific content including study design, data collection, analysis and interpretation, writing, some of the main line, or all of the preparation and scientific review of the contents and approval of the final version of the article.

Animal and human rights statement

All procedures performed in this study were in accordance with the ethical standards of the institutional and/or national research committee and with the 1964 Helsinki declaration and its later amendments or comparable ethical standards. No animal or human studies were carried out by the authors for this article.

Funding: *None*

Conflict of interest

None of the authors received any type of financial support that could be considered potential conflict of interest regarding the manuscript or its submission.

References

1. Markman TM, Nazarian S. Treatment of ventricular arrhythmias: What's New?. Trends Cardiovasc Med. 2019;29(5):249-61. DOI:10.1016/j.tcm.2018.09.014

2. Ng GA. Treating patients with ventricular ectopic beats. Heart. 2006;92(11):1707-12. DOI:10.1136/hrt.2005.067843

3. Kennedy HL, Whitlock JA, Sprague MK, Kennedy LJ, Buckingham TA, Goldberg RJ. Long-term follow-up of asymptomatic healthy subjects with frequent and complex ventricular ectopy. N Engl J Med. 1985;312(4):193-7. DOI:10.1056/NEJM198501243120401

4. Morshedi-Meibodi A, Evans JC, Levy D, Larson MG, Vasan RS. Clinical correlates and prognostic significance of exercise-induced ventricular premature beats in the community: the Framingham Heart Study. Circulation. 2004;109(20):2417-22. DOI:10.1161/01.CIR.0000129762.41889.41

5. Al-Khatib SM, Stevenson WG, Ackerman MJ, Bryant WJ, Callans DJ, Curtis

AB, et al. 2017 AHA/ACC/HRS Guideline for Management of Patients With Ventricular Arrhythmias and the Prevention of Sudden Cardiac Death: A Report of the American College of Cardiology/ American Heart Association Task Force on Clinical Practice Guidelines and the Heart Rhythm Society [published correction appears in J Am Coll Cardiol. 2018 Oct 2;72(14):1760]. J Am Coll Cardiol. 2018;72(14):e91-e220. DOI:10.1016/j. jacc.2017.10.054

6. Bikkina M, Larson MG, Levy D. Prognostic implications of asymptomatic ventricular arrhythmias: the Framingham Heart Study. Ann Intern Med. 1992;117(12):990-6. DOI:10.7326/0003-4819-117-12-990

7. Hanley PC, Tajik AJ, Hynes JK, Edwards WD, Reeder GS, Hagler DJ, et al. Diagnosis and classification of atrial septal aneurysm by two-dimensional echocardiography: report of 80 consecutive cases. J Am Coll Cardiol. 1985;6(6):1370-82. DOI:10.1016/s0735-1097(85)80228-x

8. Olivares-Reyes A, Chan S, Lazar EJ, Bandlamudi K, Narla V, Ong K. Atrial septal aneurysm: a new classification in two hundred five adults. J Am Soc Echocardiogr. 1997;10(6):644-56. DOI:10.1016/s0894-7317(97)70027-0

9. Sun H, Zhou C, Xu L, Xu T. A meta-analysis of the association of atrial septal abnormalities and atrial vulnerability. Medicine (Baltimore). 2021;100(35):e27165. DOI:10.1097/MD.0000000000027165

10. Ardahanlı I, Yılmaz AH, Akgün O, Gurbanov R. Evaluation of ventricular repolarization parameters in erectile dysfunction: a predictor of cardiac diseases. J Mens Health. 2022;18(3):78. DOI: 10.31083/j.jomh1803078

11. Park KM, Im SI, Lee SH, Gwag HB, Park Y, Park SJ, et al. Left Ventricular Dysfunction in Outpatients with Frequent Ventricular Premature Complexes. Tex Heart Inst J. 2022;49(1):e207265. DOI:10.14503/THIJ-20-7265

12. Čulić V. Ventricular Premature Complexes and Mortality Risk. Am J Cardiol. 2017;120(3):e79. DOI:10.1016/j.amjcard.2016.11.012

13. Refaat MM, Gharios C, Moorthy MV, Abdulhai F, Blumenthal RS, Jaffa MA, et al. Exercise-Induced Ventricular Ectopy and Cardiovascular Mortality in Asymptomatic Individuals. J Am Coll Cardiol. 2021;78(23):2267-77. DOI:10.1016/j. jacc.2021.09.1366

14. Tokunaga K, Yasaka M, Kuwashiro T, Gotoh S, Nakamura A, Takaguchi G, et al. Association between the maximal distance of atrial septal protrusion and cryptogenic stroke. Int J Stroke. 2017;12(9):941-5. DOI:10.1177/1747493016685721

15. Rigatelli G, Zuin M, Bilato C. Atrial septal aneurysm contribution to the risk of cryptogenic stroke in patients with patent foramen ovale: A brief updated systematic review and meta-analysis Trends Cardiovasc Med. 2022; DOI:10.1016/j.tcm.2022.02.006

16. Chellappan S, Soman KR, Sathe Y, Kukshal P, James A. Transesophageal Echocardiography Reveals a Missed Right Atrial Aneurysm in a Patient with Atrial Septal Defect and Mitral Valve Prolapse. J Cardiovasc Echogr. 2020;30(3):171-3. DOI:10.4103/jcecho.jcecho_20_20

17. Russo V, Rago A, Di Meo F, Papa AA, Ciardiello C, Cristiano A, et al. Atrial Septal Aneurysms and Supraventricular Arrhythmias: The Role of Atrial Electromechanical Delay. Echocardiography. 2015;32(10):1504-14. DOI:10.1111/ echo.12908

18. Morelli S, Voci P, Morabito G, Sgreccia A, De Marzio P, Marzano F, et al. Atrial septal aneurysm and cardiac arrhythmias. Int J Cardiol. 1995; 49(3):257-65. DOI:10.1016/0167- 5273(95)02317-p

19. Schernthaner C, Danmayr F, Daburger A, Eichinger J, Hammerer M, Strohmer B. High incidence of echocardiographic abnormalities of the interatrial septum in patients undergoing ablation for atrial fibrillation. Echocardiography. 2013;30(4):402-6. DOI:10.1111/echo.12067

20. Yetkin E, Ileri M, Korkmaz A, Ozturk S. Association between atrial septal aneurysm and arrhythmias. Scand Cardiovasc J. 2020;54(3):169-73. DOI:10.108 0/14017431.2019.1667525

21. Mitrofanova LB, Gorshkov AN, Lebedev DS, Mikhaylov EN. Evidence of specialized tissue in human interatrial septum: histological, immunohistochemical and ultrastructural findings. PLoS One. 2014;9(11):e113343. DOI:10.1371/ journal.pone.0113343

22. Morales R, Bokowski JW, Nguyen H, Awad SM. A Proposed Etiology for Atrial Tachyarrhythmia in Neonates with Atrial Septal Aneurysms. Pediatr Cardiol. 2019;40(1):230-3. DOI:10.1007/s00246-018-2017-2

How to cite this article:

Isa Ardahanli, Murat Ozmen, Onur Akgun, Davut Karakurt, Rafig Gurbanov, Olgica Mihaljevic. Association between the atrial septal aneurysm and frequent premature ventricular complexes. *Ann Clin Anal Med 2022; DOI: 10.4328/ ACAM.21314*