Annals of Clinical and Analytical Medicine
Original Research

Relationship between diabetic retinopathy and liver enzyme activities

Diabetic retinopathy and liver enzymes

Cenk Zeki Fikret[1], Ceylan Bal[2], Nil Irem Ucgun[3], Filiz Yildirim[4]
[1] Department of Ophthalmology, Ankara City Hospital
[2] Department of Medical Biochemistry, University of Yıldırım Beyazıt, Ankara City Hospital
[3] Department of Ophthalmology, University of Health Science, Ankara City Hospital
[4] Department of Internal Medicine, Polatlı Duatepe Government Hospital, Ankara, Turkey

Abstract

Aim: In this study, we aimed to examine the relationship between diabetic retinopathy and liver enzyme activities in patients with type 2 diabetes mellitus.

Material and Methods: Thirty-eight eyes with proliferative diabetic retinopathy were included in our study. Twenty-five eyes with idiopathic epiretinal membrane were included in the control group. There was no difference between the two groups in terms of age and gender. Undiluted vitreous samples (0.1 ml) of all patients were collected at the beginning of vitreoretinal surgery and stored at -80°C until analysis. Vitreous and serum alanine aminotransferase (ALT), aspartate aminotransferase (AST), alkaline phosphatase (ALP), and gamma glutamyl transpeptidase (GGT) levels of all patients were analyzed. Serum glucose, HbA1C, glomerular filtration rate (GFR) levels were also analyzed.

Results: Serum glucose and HbA1c levels were higher in the diabetic patient group ($p<0.001$). Serum GFR values were lower in the diabetic patient group ($p<0.005$). Vitreous AST levels were higher in the diabetic patient group ($p=0.037$). However, serum AST, ALT, ALP and GGT levels were not different between the two groups ($p>0.05$). There was a positive correlation between serum AST and vitreous AST levels ($p=0.01$). Serum GFR levels were also correlated with serum ALT levels ($p= 0.034$).

Discussion: Although serum levels of liver enzyme activities are within normal limits in patients with diabetes mellitus, an increase in vitreous AST levels may occur. AST may be an indicator of retinal damage in diabetic retinopathy.

Keywords

Diabetic Retinopathy, Alanine Aminotransferase, Aspartate Aminotransferase, Alkaline Phosphatase, Gamma-Glutamyl Transpeptidase

DOI: 10.4328/ACAM.21347 Received: 2022-08-08 Accepted: 2022-09-17 Published Online: 2022-09-21
Corresponding Author: Nil Irem Ucgun, Department of Ophthalmology, Ankara Sehir Hastanesi, Universiteler Mahallesi 1604. Cadde No: 9, Cankaya, Ankara, 06800, Turkey.
E-mail: niliremucgun@yahoo.com.tr P: +90 542 697 69 33
Corresponding Author ORCID ID: https://orcid.org/0000-0002-2665-3355

Introduction

Hyperglycemia in Diabetes Mellitus plays an important role in the pathogenesis of retinal microvascular damage. Many metabolic pathways have been implicated in vascular damage caused by hyperglycemia. Dilatation of retinal blood vessels and blood flow changes occurs in the early stages due to hyperglycemia. Pericyte loss develops secondary to pericyte apoptosis due to high glucose levels in later stages. Diabetic retinopathy is an important microangiopathic complication of diabetes mellitus [1]. However, diabetic microvascular pathologies can affect all organs and tissues in the body, such as kidney and liver.

Diabetic microangiopathy of the liver is also one of the common pathologies in diabetic individuals. Coexistence of diabetes mellitus and liver dysfunction has been reported. Hepatomegaly and increased activity in liver enzymes may occur as a result of hepatocellular glycogen accumulation. However, there are limited studies examining the role of liver dysfunction in the pathogenesis of diabetic retinopathy [2,3]. Non-alcoholic fatty liver disease (NAFLD) describes a state of fat accumulation in the liver irrelevant to excessive alcohol consumption or other causes of secondary hepatic steatosis. Obesity, diabetes and insulin resistance are often present in the etiology of NAFLD. NAFLD is present in 75% of individuals with type 2 diabetes mellitus (T2DM). It has been reported that serum levels of alanine aminotransferase (ALT), aspartate aminotransferase (AST), alkaline phosphatase (ALP), gamma glutamyl transpeptidase (GGT) are significantly increased in diabetic patients with liver dysfunction secondary to diabetes mellitus [4-6].

In this study, we aimed to examine the relationship between diabetic retinopathy and liver enzyme activities in patients with type 2 diabetes mellitus, who do not have hepatobiliary disease.

Material and Methods

Thirty-eight eyes of 38 patients with Type 2 Diabetes Mellitus who were operated for complications of proliferative diabetic retinopathy were included in our study. Twenty-five eyes of 25 patients who were non-diabetic and operated for idiopathic epiretinal membrane were included in the control group.

Undiluted vitreous fluid samples (0.1 ml) were obtained from 25 non-diabetic eyes with idiopathic epiretinal membrane and 38 proliferative diabetic retinopathy eyes at the beginning of the pars plana vitrectomy. All vitrectomies were performed by one author (NIU). Samples were stored at -80°C until analysis.

The blood samples were taken after overnight fasting. Samples are centrifuged at 3000 rpm and stored at -20°C until analysis time.

Biochemical variables including ALT, AST, ALP, GGT and glucose were analyzed photometrically on the Siemens Advia 1800 device (Siemens Healthcare, Erlangen, Germany). HbA1c is measured with capillary electrophoresis method (Sebia Capillarys 2 Flex Piercing). Glomerular filtration rate (GFR) was estimated according to the CKD-EPI formula.

Patients with the following conditions were excluded: a history of ocular trauma, intraocular surgery, ocular inflammatory diseases, glaucoma, alcohol consumption, viral hepatitis or malignancies. All participants in our study were tested for hepatitis B and hepatitis C, and individuals with positive tests were excluded from the study.

Written informed consent was obtained from all patients. This study was performed in accordance with the Declaration of Helsinki, and the Ankara City Hospital Ethics Committee approved the protocol for the study (E1-22-2614).

Statistical analysis

Descriptive statistics were calculated using SPSS version 22 (Statistical Package for the Social Sciences, Chicago, IL, USA). Coherence to the normal distribution analysis was made by using the Kolmogorov-Smirnov test. Variables with non-normal variables were presented as median (min-max). The Mann-Whitney U test was used to find the difference of the patient group from the control group. Spearman's correlation was used to find the correlation among the parameters. All results were accepted statistically significant at $p<0.05$.

Results

There was no difference between the two groups in terms of age and gender.

Patient and control group parameters are available in Table 1. Serum glucose and HbA1c parameters were higher in the diabetic patient group. GFR values were lower in the diabetic patient group. Vitreous AST levels were higher in the diabetic patient group (Figure 1). However, there was no difference between the 2 groups in terms of serum AST, ALT, ALP and GGT levels.

A positive correlation was found between serum AST and ALT levels (p=0.000). There was a positive correlation between serum AST and vitreous AST levels (p=0.01). Serum ALP levels were correlated with vitreous GGT values (p=0.03). Serum GGT levels correlated with serum ALT (p=0.047) and ALP (p=0.011) levels. Serum GFR (p=0.000) and ALT (p=0.003) levels were negatively correlated with age. Serum GFR levels were correlated with glucose (p=0.00) and HbA1c (p= 0.008). Serum GFR levels were also correlated with serum ALT levels (p= 0.034).

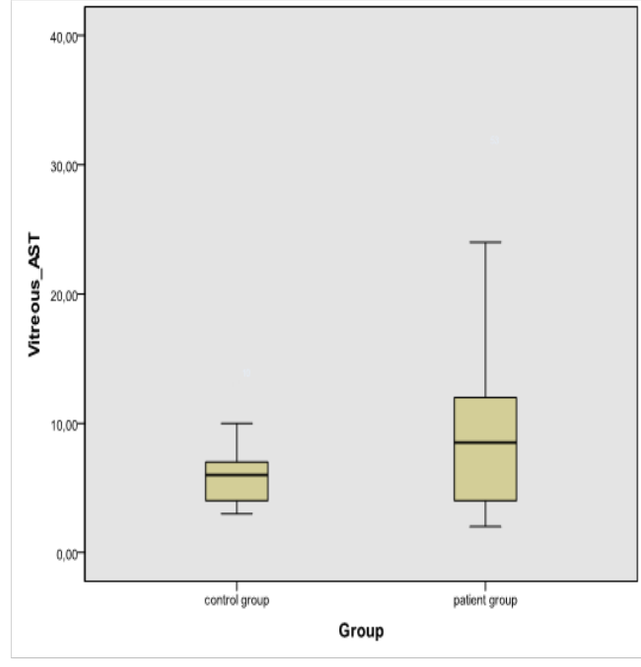

Figure 1. Distribution of vitreous AST levels in the control group and the diabetic patient group.

Table 1. Patient and control group parameters

Parameters	Control Group median (min-max) n=25	Patient Group median (min-max) n=38	p
Age	62.0 (35.0-92.0)	64.0 (36.0-77.0)	0.448
Serum Glucose (mg/dL)	94.0 (60-136)	155 (77-357)	<0.001
HbA1c (%)	5.30 (4.20-6.30)	7.85 (5.50-12.0)	<0.001
GFR (mL/min/1.73 m2)	94.0 (50.0-113)	71.5 (12.0-121)	0.005
Serum AST (IU/L)	19.0 (9.0-32.0)	16.0 (7.0-45.0)	0.325
Serum ALT(IU/L)	22.0 (11.0-45.0)	19.0 (9.0-69.0)	0.288
Serum ALP(IU/L)	88.0 (50.0-127)	76.0 (34.0-263)	0.415
Serum GGT(IU/L)	21.0 (11.0-72.0)	22.5 (12.0-321)	0.288
Vitreous AST(IU/L)	6.0 (3.0-13.0)	8.5 (2.0-31.0)	0.037
Vitreous ALT(IU/L)	1.0 (1.0-2.0)	1.0 (1.0-4.0)	0.125
VitreousALP(IU/L)	1.0 (1.0-2.0)	1.0 (1.0-6.0)	0.951
Vitreous GGT(IU/L)	1.0 (1.0-4.0)	1.0 (1.0-6.0)	0.055

Discussion

ALT, AST, ALP and GGT are commonly used diagnostic tests to evaluate liver function. Complications of diabetes may include liver dysfunction and may cause other pathologies. The effect of liver dysfunction in the pathogenesis of diabetic complications should not be underestimated.

The expression of ALP in the neurosensory retina and optic nerve head (especially choriocapillaris, small blood vessels, capillaries and pia mater) can be considered an important and hitherto unrecognized mechanism controlling blood flow. The presence of ALP in surgically excised pathological neofibrovascular tissues in eyes with proliferative diabetic retinopathy suggests that it may be effective in etiopathogenesis [7]. However, in our study, we found that serum and vitreous ALP levels were not different in diabetic patients and control groups.

GGT is an important enzyme in glutathione metabolism, which is an essential cellular antioxidant. Glutathione metabolism has effects on oxidative stress and lipid deposition in the retina. Increased levels of GGT were observed in diabetic patients [8]. Divya et al. found that the serum GGT concentration were significantly elevated in diabetic patients with retinopathy compared to the patients without retinopathy. They reported that high GGT levels may be a marker for diabetic retinopathy [9]. Arkkila et al. reported that serum GGT levels increased depending on the diabetic retinopathy stage. However, they did not detect any difference in ALT and ALP levels [3].

Mainali et. al. also reported high levels of serum aminotransferases in patients with diabetic retinopathy [10]. According to Atli et al. they did not detect a difference in serum ALT levels, but they reported that AST levels were lower in patients with proliferative diabetic retinopathy [11].

Itoh et al. reported that serum AST levels were lower in PDRP patients than in NPDR patients. They also found a negative correlation between vitreous VEGF levels and serum AST levels [12].

Osuna et al. examined the ALT, AST and GGT levels in the vitreous, and found that ALT levels increased in the vitreous of postmortem patients with heavy alcohol consumption [13].

We found that vitreous AST levels were higher in the diabetic patient group. However, there was no difference between the two groups in terms of serum AST, ALT, ALP and GGT levels.

We also found a correlation between serum GFR levels and serum ALT levels. In this situation, it can be thought that liver and kidney functions may affect each other. Mo et al. reported that ALT and AST levels increased in patients with decreased GFR levels [14]. Screening for retinal vascular changes could help in prognostication and risk-stratification of patients with diabetic kidney disease [15]. There is a relationship between diabetic retinopathy and the severity of diabetic kidney disease. The relationship between microvascular pathologies caused by diabetes in the liver and diabetic retinopathy has not yet been determined. Current studies and our knowledge of the etiopathogenesis of diabetes mellitus show that there may be a relevancy between retinal and liver pathologies.

AST is an enzyme found in the mitochondrial matrix, however, it is tightly associated with mitochondrial membranes. It is reported that AST is located in important tissues such as liver, brain and heart muscle. The increase in serum AST is due to many causes such as liver, brain, and myocardial damage [16,17]. Most of the AST activity in the retina is in the outer plexiform and photoreceptor inner segments. AST activity decreases secondary to retinal ischemia, and atrophy develops in the outer plexiform and photoreceptor inner segments of the retina [18].

Conclusion

The increase in vitreous AST levels without an increase in serum AST level, which we found in our study, suggests AST transition from damaged retinal cells to the vitreous. Further studies are needed to confirm whether AST is an indicator of retinal damage in diabetic retinopathy.

Scientific Responsibility Statement

The authors declare that they are responsible for the article's scientific content including study design, data collection, analysis and interpretation, writing, some of the main line, or all of the preparation and scientific review of the contents and approval of the final version of the article.

Animal and human rights statement

All procedures performed in this study were in accordance with the ethical standards of the institutional and/or national research committee and with the 1964 Helsinki declaration and its later amendments or comparable ethical standards. No animal or human studies were carried out by the authors for this article.

Funding: *None*

Conflict of interest

None of the authors received any type of financial support that could be considered potential conflict of interest regarding the manuscript or its submission.

References

1. Wang W, Lo ACY. Diabetic Retinopathy: Pathophysiology and Treatments. Int J Mol Sci. 2018;19(6):1816.

2. Harrison SA, Brunt EM, Goodman ZD, Di Bisceglie AM. Diabetic hepatosclerosis: diabetic microangiopathy of the liver. Arch Pathol Lab Med. 2006;130(1):27-32.

3. Arkkila PE, Koskinen PJ, Kantola IM, Rönnemaa T, Seppänen E, Viikari JS. Diabetic complications are associated with liver enzyme activities in people with type 1 diabetes. Diabetes Res Clin Pract. 2001;52(2):113-8.

4. Zhang M, Li L, Chen J, Li B, Zhan Y, Zhang C. Presence of diabetic retinopathy is lower in type 2 diabetic patients with non-alcoholic fatty liver disease. Medicine (Baltimore). 2019;98(18):e15362.

5. Zhang X, Ji X, Wang Q, Li JZ. New insight into inter-organ crosstalk contributing to the pathogenesis of non-alcoholic fatty liver disease (NAFLD). Protein Cell. 2018;9(2):164-77.

6. Lv WS, Sun RX, Gao YY, Wen JP, Pan RF, Li L, et al. Nonalcoholic fatty liver disease and microvascular complications in type 2 diabetes. World J Gastroenterol. 2013;19(20):3134-42.

7. Zeiner J, Losenkova K, Zuccarini M, Korhonen AM, Lehti K, Kauppinen A, et al. Soluble and membrane-bound adenylate kinase and nucleotidases augment ATP-mediated inflammation in diabetic retinopathy eyes with vitreous hemorrhage. J Mol Med (Berl). 2019;97(3):341-54.

8. Gasecka A, Siwik D, Gajewska M, Jaguszewski MJ, Mazurek T, Filipiak KJ, et al. Early Biomarkers of Neurodegenerative and Neurovascular Disorders in Diabetes. J Clin Med. 2020;9(9):2807.

9. Divya R, Ashok V. Evaluation of serum gamma glutamyl transferase levels as a marker of oxidative stress in type 2 diabetes patients with and without retinopathy. MedPulse Int J Physiol. 2019;9:30–4.
10. Mainali A, Uprety N, Adhikari P, Pathak UN. Serum aminotransferases level in patients with type 2 diabetes mellitus attending a tertiary care center, Kathmandu. Nepal Med Coll J. 2018; 20(4): 178-82.
11. Atlı H, Onalan E, Yakar B, Duzenci D, Dönder E. Predictive value of inflammatory and hematological data in diabetic and non-diabetic retinopathy. Eur Rev Med Pharmacol Sci. 2022;26(1):76-83.
12. Itoh K, Furuhashi M, Ida Y, Ohguro H, Watanabe M, Suzuki S, et al. Detection of significantly high vitreous concentrations of fatty acid-binding protein 4 in patients with proliferative diabetic retinopathy. Sci Rep. 2021;11(1):12382.
13. Osuna E, Pérez-Cárceles MD, Moreno M, Bedate A, Conejero J, Abenza JM, et al. Vitreous humor carbohydrate-deficient transferrin concentrations in the postmortem diagnosis of alcoholism. Forensic Sci Int. 2000;108(3):205-13.
14. Mo Z, Hu H, Du X, Huang Q, Chen P, Lai L, et al. Association of evaluated glomerular filtration rate and incident Diabetes Mellitus: A secondary retrospective analysis based on a Chinese cohort study. Front Med (Lausanne). 2022;8:724582.
15. Gupta M, Rao IR, Nagaraju SP, Bhandary SV, Gupta J, Babu GTC. Diabetic Retinopathy Is a Predictor of Progression of Diabetic Kidney Disease: A Systematic Review and Meta-Analysis. Int J Nephrol. 2022;2022:3922398.
16. Sookoian S, Pirola CJ. Liver enzymes, metabolomics and genome-wide association studies: from systems biology to the personalized medicine. World J Gastroenterol. 2015;21(3):711-25.
17. McKenna MC, Hopkins IB, Lindauer SL, Bamford P. Aspartate aminotransferase in synaptic and nonsynaptic mitochondria: differential effect of compounds that influence transient hetero-enzyme complex (metabolon) formation. Neurochem Int. 2006;48(6-7):629-36.
18. Endo S, Ishiguro S, Tamai M. Possible mechanism for the decrease of mitochondrial aspartate aminotransferase activity in ischemic and hypoxic rat retinas. Biochim Biophys Acta. 1999;1450(3):385-96.

How to cite this article:
Cenk Zeki Fikret, Ceylan Bal, Nil Irem Ucgun, Filiz Yildirim. Relationship between diabetic retinopathy and liver enzyme activities. Ann Clin Anal Med 2022; DOI: 10.4328/ACAM.21347