Annals of Clinical and Analytical Medicine
Original Research

The effect of erdosteine on ischemia-reperfusion injury in skeletal muscle of rats

Abdullah Özer[1], Ayşegül Küçük[2], Yiğit Kılıç[3], Serap Gültekin[4], Hayriye Tatlı Doğan[5], Aydan Kılıçarslan[5], Hüseyin Demirtaş[1], Barış Mardin[1], Dilek Erer[1] Tolga Tatar[1], Mustafa Arslan[6]
[1] Department of Cardiovascular Surgery, Faculty of Medicine, Gazi University, Ankara
[2] Department of Physiology, Faculty of Medicine, Kütahya Health Science University, Kütahya
[3] Department of Pediatric Cardiovascular Surgery, Dr Siyami Ersek Cardiovascular and Thoracic Surgery Training and Research Hospital, Istanbul
[4] Department of Radiology, Faculty of Medicine, Gazi University, Ankara
[5] Department of Pathology, Faculty of Medicine, Yıldırım Beyazıt University, Ankara
[6] Department of Anesthesia and Reanimation, Faculty of Medicine, Gazi University, Ankara, Turkey

Abstract

Aim: As a mucolytic agent, Erdosteine has two sulfhydryl groups. These groups function as free radical scavengers, which has protective effects against ischemia- reperfusion (IR) injury. In this study, we aimed to observe the effects of erdosteine on skeletal muscle tissue in a rat lower extremity IR injury model.
Material and Methods: A total of 18 Wistar albino rats were separated into 3 groups (n: 6); Control group (C), IR group (IR) and IR group with erdosteine (IR-E). Erdosteine administered intraperitoneally (150 mg.kg-1). Rat tissues were taken for histopathological and immunohistochemical evaluations after 2 hours of ischemia and 2 hours of reperfusion period.
Results: Blood flow measurements were significantly higher in the IR-E group than in the IR group. In the IR group, endothelial caspase 3 and 8 enzyme expression was significantly higher than C and IR-E groups. Muscle caspase 3 enzyme expression was higher in the IR group than C and IR-E groups. IR and IR-E groups showed increased inflammation, vascular congestion and myositis injury levels than the C group. Also, inflammation, vascular congestion and myositis injury showed a significant decrease in the IR-E group than IR group.
Discussion: As a result, erdosteine has a protective effect against skeletal tissue damage resulting from IR injury in rats. The results show the possibility of clinical administration of erdosteine for I/R injury of skeletal muscle tissue.

Keywords

Skeletal Muscle, Ischemia-Reperfusion, Erdosteine, Caspase 3, Blood Flow, Rat

DOI: 10.4328/ACAM.21268 Received: 2022-06-13 Accepted: 2022-07-13 Published Online: 2022-07-16
Corresponding Author: Mustafa Arslan, Department of Anesthesia and Reanimation, Faculty of Medicine, Gazi University, 06510, Ankara, Turkey.
E-mail: mustarslan@gmail.com P: +90 312 202 67 39 / + 90 533 422 85 77
Corresponding Author ORCID ID: https://orcid.org/0000-0003-4882-5063

Introduction

Ischemia-reperfusion (IR) injury is an inevitable, frequent and serious situation. If the muscle's blood supply is inadequate to meet its needs, ischemia occurs, and if the blood flow is re-established after reperfusion, the substances involved in oxidation play a critical role in the clinical outcome. Reperfusion may unexpectedly cause an increased ratio of mortality and morbidity as extended inflammation and necrotic and apoptotic events caused by reactive oxygen species (ROS) end up in organ injury and systemic complications [1-6].

Erdosteine (N-carboxymethyl)thio)acetyl-homocysteine thiolactone), which is a mucolytic agent, has two sulfhydryl groups. These groups function as free radical scavengers [7]. As a mucociliary transport increaser, erdosteine is used to treat chronic obstructive pulmonary disease. It also inhibits the effects of free radicals produced by cigarette smoke [8]. Animal researche showed that erdosteine has a protective effect against toxic by-products of oxidative stress produced during tissue injuries [9]. Inhibition of LPS-induced NF-kB activation mediates the anti-inflammatory effect of erdosteine [10].

Caspases, initially identified as a family of proteases regulating cell death, have been found to have non-apoptotic functions as well. Effectors of apoptosis are the caspases with short prodomains, caspases-3, 6, and 7. Caspases-2, 8, 9, and 10 are initiators of apoptosis. Caspase-3 and 8 enzyme activity is a good marker for ischemia-induced death pathways [11].

Our aim in this study was to investigate the effect of erdosteine on IR injury in skeletal muscle of rats.

Material and Methods

Animals and Experimental Protocol

This study was carried out in the Gazi University Physiology Laboratory with the approval of the Gazi University Ethical Committee of Experimental Animals. All employed methods were in agreement with approved basics of the Guide for the Care and Use of Laboratory Animals. The present study was undertaken with 18 albino Wistar rats weighing between 250 and 300 g and aged 10 to 12 weeks, raised under identical environmental conditions. The rats were kept at 20–21 °C with a 12:12-h light:dark photoperiod and could access food freely until 2 h before the induction of anesthesia. The 18 Wistar albino rats were randomly divided into four groups, each containing 6 rats. Median laparotomy was done under general anesthesia.

Control group: Median laparotomy was done alone without any additional surgical intervention. After 4 hours of follow-up, skelatal tissue was collected and the animals were sacrificed

IR group: Median laparotomy was performed as well. We clamped the infrarenal part of the aorta with an atraumatic clamp for 2 hours. Then we removed the clamp and allowed reperfusion for 2 more hours. Finally, rats were sacrificed after the skelatal tissue was collected.

IR group with erdosteine: Similar steps were performed, but additionally, before the ischemia period, erdosteine was given (150 mg.kg–1) intraperitoneally for 30 min. Rats were sacrificed at the end of the reperfusion period, which lasted 2 hours, after collecting skelatal tissue samples.

All the rats were given intramuscular ketamine (Ketalar; Parke-Davis; Pfizer, Inc., New York, NY, USA) at a dose of 100 mg kg–1 and xylazine hydrochloride (Alfazyne, 2%; Ege Vet, Ltd., Izmir, Turkey) and intracardiac blood samples (up to 10 ml) were obtained. At the end of reperfusion period, a histochemical and immunohistochemical evaluation of skeletal muscle tissue specimen were performed.

IAA Blood Flow Measurement

Intra-abdominal aorta (IAA) blood flow was recorded. Blood flow measurements were conducted by placing probe on the tissue with a fixed position by a laser Doppler microvascular perfusion monitor (OxyLab LDF; Oxford Optronix Limited, Oxford, UK).

Histochemical and Immunohistochemical evaluation

At the end of each experiment, one of the muscle tissue in each rat was fixed in 10% buffered formalin for 48 h, dehydrated in a graded ethanol series, cleaned in xylene, and embedded in paraffin wax and sections of 5 μm thickness were cut using a sliding microtome (Leica Microsystems, Germany). Tissue sections were stained with hematoxylin-eosin (H&E).

All the sections were performed by the same pathologist who was blinded to the study. The scoring system was used for the histopathological evaluation of the muscle tissues.

Immunohistochemical evaluation

For immunohistochemical studies, complete surface sections of 3-4 μL of poly-L-lysine- coated slides were prepared from formalin fixed paraffin embedded blocks of biopsy specimens in all of the events. The sections were left overnight at 45 degrees.

Deparaffinization, blocking, primer antibody (Caspase 3 and Caspase 8: Citrate 30 min), post-primer, polymer, DAP were used as standard antigen retrieval methods, respectively; in the Bond-maximal immunohistochemistry (Leica) device for Caspase 3 (p11, C-6, 1/400, mouse monoclonal antibody) and caspase 8 (Clone, D-8, 1/205, mouse monoclonal antibody) antibodies immunohistochemically. In the background dye Hematoxylin II for 6 min and the Blue reagent for 4 min were applied.

After Immunohistochemical staining preparations were clarified with xylene and covered with balsam they were washed in water and alcohol.

We evaluated both prevalence and intensity of stromal cells' and endothelium's cytoplasmic staining of caspase 3 and caspase 8 in immunohistochemical staining. Intensity of staining was scored as no staining - 0, mild- 1 (prevelance of staining was smaller than 50%) and severe -2 (prevelance of staining was greater than 50%).

Thymus tissue was used for caspase 8 and liver tissue was used for caspase 3 as controls. Cytoplasmic membranous staining of caspases 3 and 8 was considered positive.

Statistical Analysis

All data were processed by variance analysis using SPSS 17.0 for Windows (SPSS Inc., USA). $P < 0.05$ was considered statistically significant. The data were expressed as mean ± standard error (SE). Variance analysis and the Kruskal– Wallis test were used to evaluate the data. Mann–Whitney U tests with Bonferroni corrections were used to evaluate the variables with significance.

Results

Blood flow measured before IR was similar between groups.

Blood flow at the 10th minute after the clamp was similar in the IR and IR-E groups. Blood flow measurements were significantly higher in the IR-E group than in the IR group 10 minutes after the clamp was opened, 10 minutes before the clamp was opened and just before the sacrification (Table 1).

When the groups were compared in terms of skeletal muscle tissue inflammation, there was a significant difference between the groups (p<0.0001). Inflammation was significantly higher in the IR and IR-E groups than in group C (p<0.0001, p=0.002, respectively). In addition, inflammation was significantly lower in the IR-E group than in the IR group (p=0.010) (Table 2, Figure 1).

There was a significant difference between groups in terms of vasodilation in skeletal muscle (p=0.001). Vasodilation was significantly increased in the IR and IR-E groups than in group C (p<0.0001, p=0.002, respectively), (Table 2, Figure 1).

There was a significant difference between the groups in terms of vascular congestion in skeletal muscle (p=0.002). Vascular congestion was significantly increased in the IR and IR-E groups than in group C (p<0.0001, p=0.025, respectively). Furthermore, vascular congestion was significantly reduced in the IR-E group than in the IR group (p = 0.045) (Table 2, Figure 1).

There was a significant difference between the groups in terms of damage to skeletal muscle myocytes (p<0.0001). Myocyte damage was significantly higher in the IR and IR-E groups than in group C (p<0.0001, p=0.003, respectively). In addition, myocyte injury was significantly lower in the IR-E group than in the IR group (p=0.023) (Table 2, Figure 1).

Fibrosis and steatosis were similar between groups.

There was a significant difference between groups (skeletal muscle tissue) in terms of endothelial caspase 8 enzyme activity (p=0.036). Endothelial caspase 8 enzyme activity was significantly higher in the IR group compared to C and IR-E groups (p=0.015, p=0.045, respectively (Table 3, Figure 2).

Caspase 8 enzyme activity was similar between the groups (Table 3).

There was a significant difference between the groups (skeletal muscle tissue) in terms of caspase 3 enzyme activity (p=0.022). Caspase 3 enzyme activity was significantly higher in IR group compared to C and IR-E groups (p=0.015 p=0.015, respectively (Table 3, Figure 3).

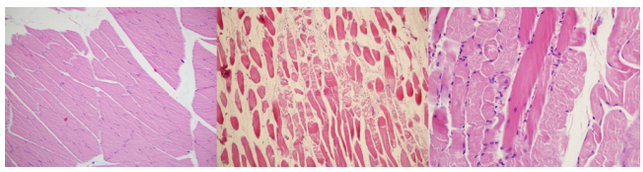

Figure 1. (Left) No inflammation or fibrosis was observed in the control group muscle tissue (H/E x 100); (Middle) Severe myocyte damage and mild inflammation in ischemia-reperfusion muscle tissue (H/E x 100); (Right) Ischemia-reperfusion-erdosteine group showed mild inflammation of muscle tissue and moderate myocyte damage (H/E x 400)

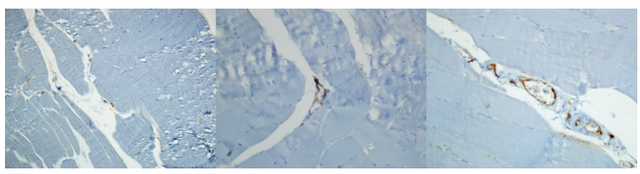

Figure 2. (Left) There was no significant staining in the control group except for the muscle endothelium (x400); (Middle) There was no positive staining of the endothelial cells in focal areas of ischemia-reperfusion group muscle tissue and no significant staining of myocytes

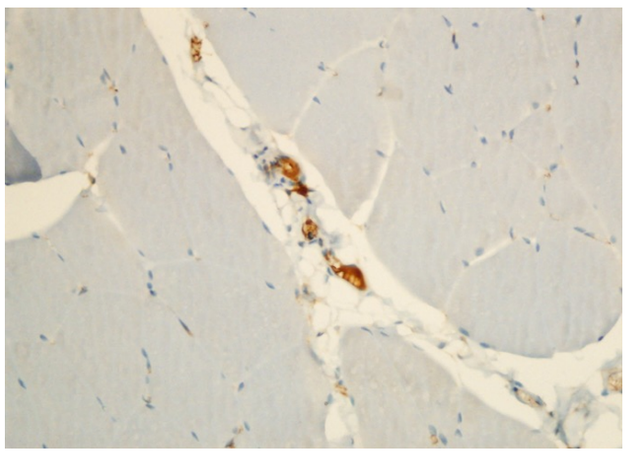

Figure 3. Ischemia-reperfusion-erdosteine group did not show positive staining in endothelial cells and showed no staining in myocytes (x400)

Table 1. Intraabdominal aorta (IAA) Blood Flow Measurement [Mean ± SE]

	Group C (n=6)	Group IR (n=6)	Group IR-E (n=6)	P**
Before IR	7125.17±769.15	6960.17±1230.79	7285.67±884.20	0.849
10 minutes after clamp	-	3931.50±1425.75	4021.00±1192.43	0.908
10 minutes before clamping	-	1914.50±529.18	3100.17±1167.05[&]	0.047
10 minutes after clamp is opened	-	5562.40±2208.09	8843.17±1356.60[&]	0.014
Before sacrification	-	4850.80±1936.22	8405.50±1692.13[&]	0.010

p**: significance level with the Kruskal-Wallis test p< 0.05; [&]p<0.05: compared with Group IR

Table 2. Histological parameters [Mean ± SE]

	Group C (n=6)	Group IR (n=6)	Group IR-E (n=6)	P**
Inflammation	0.00±0.00	1.50±0.22*	0.83±0.17*[&]	<0.0001
Fibrosis	0.00±0.00	0.00±0.00	0.00±0.00	-
Vascular dilatation	0.00±0.00	1.50±0.22*	1.05±0.21*	0.001
Vascular congestion	0.33±0.21	1.67±0.33*	1.17±0.17*[&]	0.002
Steatosis	0.00±0.00	0.17±0.17	0.00±0.00	0.391
Myocyte damage	0.00±0.00	2.00±0.37*	1.17±0.17*[&]	<0.0001

p**: significance level with the Kruskal-Wallis test p< 0.05; *p<0.05: compared with Group C [&]p<0.05: compared with Group IR

Table 3. Caspase 3 and Caspase 8 enzyme activity parameters [Mean ± SE]

	Group C (n=6)	Group IR (n=6)	Group IR-E (n=6)	P**
Caspase -3 - muscle	0.00±0.00	0.50±0.22*	0.00±0.00[&]	0.022
Caspase- 3- endothelium	1.67±0.21	2.33±0.21*	1.50±0.22[&]	0.036
Caspase -8 - muscle	0.00±0.00	0.00±0.00	0.00±0.00	-
Caspase- 8- endothelium	0.83±0.17	1.66±0.21*	1.00±0.26[&]	0.036

p**: significance level with the Kruskal-Wallis test p< 0.05; *p<0.05: compared with Group C [&]p<0.05: compared with Group IR

There was a significant difference between the groups (skeletal muscle tissue) in terms of endothelial caspase 3 enzyme activity (p=0.036). Endothelial caspase 3 enzyme activity was significantly higher in the IR group compared to C and IR-E groups (p=0.045, p=0.015, respectively (Table 3, Figure 3).

Discussion

We evaluated the effects of erdosteine, a disulphide antioxidant, [9] on skeletal muscle IR injury. Our study shows that treatment with erdosteine notably attenuates the skeletal muscle damage of rats subjected to IR injury. Erdostein has an improving effect on both the oxidative status and the histopathological changes. Erdosteine increased blood flow in the IR-E group than in the IR group 10 minutes after the clamp was opened, 10 minutes before the clamp was opened and just before the sacrification. Erdosteine has two blocked sulfhydryl groups. The free sulfhydryl group breaks the disulfide bridges of the mucus glycoproteins causing sputum viscosity to reduce [8,12]. In addition to mucolytic effects, erdosteine has free radical scavenging and antioxidant activities (cardiac toxicity, hepatic toxicity, nephrotoxicity, neurotoxicity, and bleomycin-induced lung fibrosis) [9].

However, erdosteine also has anti-inflammatory and antioxidant effects. As Jang et al. [13] offer that anti-inflammatory effect of erdosteine contributes to the inhibitory effect of erdosteine on inflammatory cytokine synthesis and ROS production. Park et al. [10] suggest that erdosteine exerts anti-inflammatory effects by inhibiting NF-kB activation in LPS-stimulated mouse macrophages. In our study, inflammation was significantly lower in the IR-E group than in the IR group.

We also found that vasodilation was significantly increased in the IR and IR-E groups than in group C, as vascular congestion was significantly reduced in the IR-E group than in the IR group. Therefore, erdosteine may be a useful therapeutic agent for preventing accompanying severe inflammation resulting in vasodilatation.

Although fibrosis and steatosis were similar between groups, myocyte injury was significantly lower in the IR-E group than in the IR group.

Caspases play an essential role in the execution of apoptosis as a member of proteolytic enzymes [14]. Some individiuals caspases are activated transiently and lead to apoptosis by affecting different stages of the signal transduction cascade. During apoptosis, after activation of initiator caspases such as caspase 8, a proteolytic cascade begins and effector caspases such as caspase-3 are activated and this leads to the cleavage of several substrates and results in morphological changes observed in apoptosis [15]. Caspases have an important role in the cell death program. Caspase activation's pharmacological blockade prevents apoptosis. Thus, organ function and survival in animal models of sepsis improve [16].

In this study, endothelial caspase 8 enzyme activity was significantly higher in the IR group compared to C and IR-E groups. Endothelial caspase 3 enzyme activity was significantly higher in the IR group compared to C and IR-E groups.

Conclusion

The present study demonstrated a possible protective effect of erdosteine in skeletal muscle IR injury on the basis of anti-apoptotic and anti-inflammatory systems, confirmed by histopathologic evaluation. The possibility of clinical application of erdosteine in IR injury of the skeletal muscle tissue is suggested by these results. A couple of dose protocols of erdosteine and different time protocols for IR should be investigated in future studies.

Scientific Responsibility Statement

The authors declare that they are responsible for the article's scientific content including study design, data collection, analysis and interpretation, writing, some of the main line, or all of the preparation and scientific review of the contents and approval of the final version of the article.

Animal and human rights statement

All procedures performed in this study were in accordance with the ethical standards of the institutional and/or national research committee and with the 1964 Helsinki declaration and its later amendments or comparable ethical standards. No animal or human studies were carried out by the authors for this article.

Funding: *None*

Conflict of interest

None of the authors received any type of financial support that could be considered potential conflict of interest regarding the manuscript or its submission.

References

1. Sirmali R, Armağan A, Öktem F, Uz E, Kirbas A, Dönmezs S, et al. Protective effects of erdosteine, vitamin E, and vitamin C on renal injury induced by the ischemia-reperfusion of the hind limbs in rats. Turk J Med Sci. 2015;45(1):33-7.

2. Duru S, Koca U, Oztekin S, Olguner C, Kar A, Coker C, et al. Antithrombin III pretreatment reduces neutrophil recruitment into the lung and skeletal muscle tissues in the rat model of bilateral lower limb and reperfusion: A pilot study. Acta Anaesthesiol Scand. 2005;49(8):1142–8.

3. Lisowska B, Siewruk K, Lisowski A. Substance P and Acute Pain in Patients Undergoing Orthopedic Surgery. PLoS One. 2016;11(1):e0146400.

4. Erer D, Özer A, Demirtaş H, Gönül II, Kara H, Arpacı H, et al. Effects of alprostadil and iloprost on renal, lung, and skeletal muscle injury following hindlimb ischemia-reperfusion injury in rats. Drug Des Devel Ther. 2016;10:2651-8.

5. Erer D, Dursun AD, Oktar GL, Iriz E, Zor MH, Elmas C, et al. The effects of iloprost on lung injury induced by skeletal muscle ischemia-reperfusion. Bratisl Med J. 2014;115(7):405-10.

6. Pantazi E, Bejaoui M, Folch-Puy E, Adam R, Roselló-Catafau J. Advances in treatment strategies for ischemia reperfusion injury. Expert Opin Pharmacother. 2016;17(2):169-79.

7. Sirmali M, Uz E, Sirmali R, Kilbaş A, Yilmaz HR, Ağaçkiran Y, et al. The effects of erdosteine on lung injury induced by the ischemia-reperfusion of the hind-limbs in rats. J Surg Res. 2008;145(2):303-7.

8. Cazzola M, Page C, Rogliani P, Calzetta L, Matera MG. Multifaceted Beneficial Effects of Erdosteine: More than a Mucolytic Agent. Drugs. 2020;80(17):1799-809.

9. Moretti M, Marchioni CF. An overview of erdosteine antioxidant activity in experimental research. Pharmacol Res. 2007;55(4):249-54.

10. Park JS, Park MY, Cho YJ, Lee JH, Yoo CG, Lee CT, et al. Anti-inflammatory Effect of Erdosteine in Lipopolysaccharide-Stimulated RAW 264.7 Cells. Inflammation. 2016;39(4):1573-81.

11. Troy CM, Akpan N, Jean YY. Regulation of caspases in the nervous system implications for functions in health and disease. Prog Mol Biol Transl Sci. 2011;99:265-305

12. Li T, Zeng W, Liu R. Effect of Erdosteine on Middle Ear Effusion in Rats by Mediating TLR4 Signaling Pathway. Biomed Res Int. 2021;2021:9968907.

13. Jang YY, Song JH, Shin YK, Han ES, Lee CS. Depressant effects of ambroxol and erdosteine on cytokine synthesis, granule enzyme release, and free radical production in rat alveolar macrophages activated by lipopolysaccharide. Pharmacol Toxicol. 2003;92(4):173-9.

14. Demiralay R, Gürsan N, Erdem H. The effects of erdosteine and N-acetylcysteine on apoptotic and antiapoptotic markers in pulmonary epithelial cells in sepsis. Eurasian J Med. 2013;45(3):167-75.

15. Pinhu L, Qin Y, Xiong B, You Y, Li J, Sooranna SR. Overexpression of Fas and FasL is associated with infectious complications and severity of experimental severe acute pancreatitis by promoting apoptosis of lymphocytes. Inflammation. 2014;37(4):1202-12.

16. Gray CC, Biron-Girard B, Wakeley ME, Chung CS, Chen Y, Quiles-Ramirez Y, et al. Negative Immune Checkpoint Protein, VISTA, Regulates the CD4+ Treg Population During Sepsis Progression to Promote Acute Sepsis Recovery and Survival. Front Immunol. 2022;13:861670.

How to cite this article:

Abdullah Özer, Ayşegül Küçük, Yiğit Kılıç, Serap Gültekin, Hayriye Tatlı Doğan, Aydan Kılıçarslan, Hüseyin Demirtaş, Barış Mardin, Dilek Erer, Tolga Tatar, Mustafa Arslan. *The effect of erdosteine on ischemia-reperfusion injury in*