Annals of Clinical and Analytical Medicine
Original Research

Management of intraoperative transesophageal echocardiography in aortic valve neocuspidization (Ozaki procedure)

TEE with Ozaki procedure

Mustafa Şimşek[1], Sena Sert[2], Türkan Kudsioğlu[1]
[1] Department of Anesthesiology and Reanimation
[2] Department of Cardiology, Istanbul Dr. Siyami Ersek Thoracic and Cardiovascular Surgery Training and Research Hospital, Istanbul, Turkey

Abstract
Aim: This study aims to evaluate the importance and results of intraoperative transesophageal echocardiography (TEE) and postoperative transthoracic echocardiography (TTE) for aortic valve functions in patients undergoing aortic valve neocuspidization (Ozaki) procedure.
Material and Methods: In this study, 50 patients with aortic insufficiency, aortic stenosis, or combined aortic pathology, who underwent aortic neocuspidization in our center between 1 January – 1 October 2021 were prospectively evaluated with intraoperative TEE as well as preoperative and postoperative TTE.
Results: None of the patients had aortic stenosis after surgery. Ten patients (%20,8) had mild, and 2 patients (%4,16) had moderate aortic insufficiency. Mean transvalvular aortic gradient was 7.96(3-16) mmHg, peak transvalvular aortic gradient was 17.04(8-30) mmHg. Peak aortic velocity was 1.66(08-2.6) m/s.
Discussion: Intraoperative TEE and postoperative TTE can help evaluate early outcomes of aortic valve neocuspidization. TTE and TEE are necessary for intraoperative and postoperative management of hemodynamics of patients.

Keywords
Aortic Valve Neocuspidization, Ozaki Procedure, Transesophageal Echocardiography

DOI: 10.4328/ACAM.21292 Received: 2022-06-27 Accepted: 2022-08-04 Published Online: 2022-08-08
Corresponding Author: Mustafa Şimşek, Department of Anesthesiology and Reanimation, Istanbul Dr. Siyami Ersek Thoracic and Cardiovascular Surgery Education and Research Hospital, Istanbul, Turkey.
E-mail: mustafasimsek73@gmail.com P: +90 505 778 99 80 F: +90 216 337 97 19
Corresponding Author ORCID ID: https://orcid.org/0000-0001-9903-5307

Introduction

Aortic valve replacement is the gold standard treatment in patients with severe aortic stenosis (AS) and aortic insufficiency (AI). Mechanical and bioprosthetic valves are frequently used for valve replacement. Mechanical valves are associated with mechanical problems in the long term and patients with mechanical valves require lifelong anti-coagulants. Additionally, mechanical valves cannot provide the physiological hemodynamics of native valves [1]. Nowadays, in suitable patients with mitral and tricuspid valve diseases, surgical repair techniques are predominantly considered. However. surgical repair of the aortic valve is rare and usually limited to aortic valve insufficiency [2,3]. In severe calcific aortic valves, surgical repair is not preferred and valve replacement appears to be the only viable option [1]. Autologous pericardium fixated with glutaraldehyde usage was first defined by Duran et al. who reported replacement of the aortic valve using autologous pericardium [4]. Similarly, Ozaki et al replaced aortic valve leaflets separately by using autologous pericardium [1]. However, the sizes of the aortic leaflets usually differ from each other. Replacing aortic leaflets separately results in more efficient aortic valve motion, more physiologic coaptation, and more stable hemodynamics [5,6]. This procedure is advantageous in AS, AI, and also in the case of a small aortic annulus or infective endocarditis [5,7]. The aortic valve and annulus can be assessed by TTE and TEE. Intraoperative TEE evaluation may provide useful information about AS/AI mechanism and grade. TEE allows evaluation of the aortic valve morphology with mid-esophageal long axis, short axis, transgastric, and deep transgastric views. In our study, we present the results of our evaluation of reconstructed aortic valves, whose functions were assessed intraoperatively with TEE and postoperatively with TTE.

Material and Methods

In our center, after obtaining ethics committee approval, 50 patients underwent aortic valve neocuspidization between January 1 and October 1, 2021 due to AS, AI, or a combined aortic valve pathology, whose intraoperative TEE and preoperative- postoperative TTE were recorded prospectively. The mean (IQR) age of the patients was 64.61 years (24-82); 22 (%44) patients were male, and 28 (%56) were female. Ten (%20) patients had combined aortic valve pathology (AS+AI), while 20 (%40) patients had aortic stenosis, and 15 (%30) had aortic insufficiency. Five (%10) patients had concomitant mitral or coronary artery disease. Preoperative TTE, intraoperative TEE, early postoperative TTE, and postoperative 30th day-TTE of the included patients were recorded.

Surgeries were performed under routine monitorization (5-lead ECG, radial artery catheterization, central vein catheterization, SpO2) and were performed under general anesthesia. Patients were administered total intravenous anesthesia (TIVA), including midazolam, fentanyl, rocuronium, and inhalation anesthetics such as sevoflurane if needed. Cardiac functions of all patients were evaluated and recorded by TEE (Vivid 7 GE Vingmed Ultrasound AS Horten, Norway) after induction. After median sternotomy, the autologous pericardium was fixated for 10 minutes in %6 glutaraldehyde; 3 mg/kg of heparin was administered targeting an efficient ACT level (≥450). Cardiopulmonary bypass (CPB) was initiated with aortic and right atrial cannulation. After cross-clamping and aortotomy, the aortic leaflets were resected. Intercommissural distance was measured using the technique defined by Ozaki et al. Leaflets were prepared using glutaraldehyde-fixated autologous pericardium. The aortic valve was then reconstructed one leaflet at a time [1]. The aortotomy sutured closed and the patients were weaned off CPB.

TEE examination was performed on the newly constructed aortic valve. The patients were transferred to the ICU after the completion of surgery. All patients were examined by TTE (Vivid 7 GE Vingmed Ultrasound AS Horten, Norway) before discharge and 30 days after discharge.

Results

Preoperative demographic data

This study included 50 patients with aortic valve pathologies, with a mean (IQR) age of 64.61 years (24-82). Twenty-two (%44) patients were male, and 28 (%56) were female. Ten (%20) patients had combined aortic valve pathology (AS+AI), while 20 (%40) patients had aortic stenosis, and 15 (%30) had aortic insufficiency. Five (%10) patients had concomitant mitral or coronary artery disease. The mean BMI of the patients was 28.7(20.9-34.9) kg/m2 (Table 1).

Preoperative echocardiographic data

The Mean LVEF of the patients was %53.75 (60-65). Forty-six (%92) of the resected aortic valves were tricuspid and 4 (%8) were bicuspid. The mean aortic annulus was 22.07 (11-32) mm,

Table 1. Preoperative patient data (n = 50)

Age (year), mean(m) (IQR)	64.61(24-82)
Sex	
Female n (%)	28 (56%)
Male n (%)	22 (44%)
BMI kg/m2, m (IQR)	28.70 (20.9-34.9)
DM, n (%)	12 (24%)
COPD, n (%)	1 (2%)
CRD, n (%)	0
Dialysis n (%)	0
CAD n (%)	10 (20%)
Active Endocarditis n (%)	1 (2%)
Angina Pectoris n (%)	13 (26%)
Dyspnea n (%)	16 (32%)
Combined Aortic Valve Pathology n (%)	10 (20%)
Pure Aortic Stenosis n (%)	20 (40%)
Pure Aortic Insufficiency n (%)	15 (30%)
Concomitant valve pathology and CAD	5(10%)
EuroScore II (%) m (IQR)	1.26 (1.0-2.14)
Preoperative Echocardiographic Data	
Ejection Fraction (%), m (IQR)	53.75 (30-65)
Tricuspid Aortic Valve n (%)	46 (92%)
Bicuspid Aortic Valve n (%)	4 (8%)
Preoperative Aortic Valve Annulus Length (mm), m (IQR)	22.07 (11-32)
Preoperative Aortic Sinus Length (mm), m (IQR)	30.11 (21-42)
Mean transvalvular aortic gradient (mmHg), m (IQR)	50.14 (12-80)
Peak transvalvular aortic gradient (mmHg), m (IQR)	79.89 (20-132)
Peak aortic valve velocity (m/s) m (IQR)	4.43 (2,50-5,70)
Effective AVA (cm^2) m (IQR)	0.81 (0,47-2,20)

m: median, IQR: interquartile range, n: number

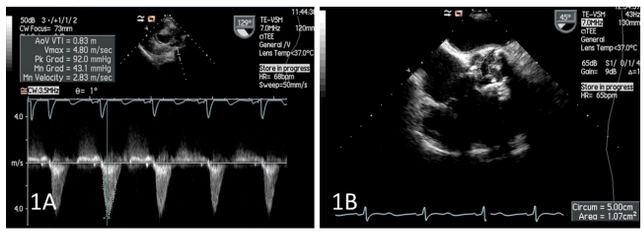

Figure 1. (A) Intraoperative TEE – Preoperative, Transvalvular mean gradient measurement via Transgastric 120o View, (B) Intraoperative TEE- Preoperative, Planimetric aortic valve area measurement Mid Esophageal 45o View.

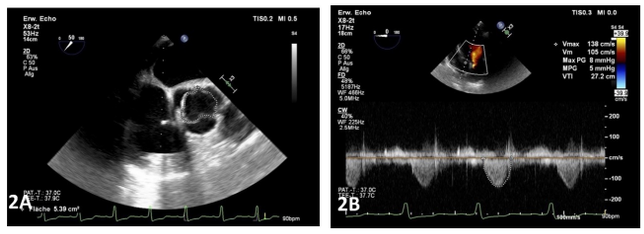

Figure 2. (A) Intraoperative TEE – Aortic Valve area measurement after Ozaki Procedure, Mid esophageal short axis 50 0 view, (B) Intraoperative TEE After Ozaki Procedure, aortic valve transvalvular mean gradient of 5 mmHg measured with Transgastric 120 o view, aortic insufficiency evaluated with continuous flow Doppler method.

Table 2. Intraoperative and postoperative data

Intraoperative data (n = 50)	
Operation time (min), m (IQR)	287.50 (167-520)
Extra-corporeal perfusion time (min), m (IQR)	190.21 (117-483)
Aortic cross clamp time (min), m (IQR)	136.86 (92-232)
Postoperative data (n = 50)	
Postoperative ICU length of stay (day), m (IQR)	1.75 (1-14)
Hospital length of stay (day), m(IQR)	8.57 (1-20)
Permanent Pacemaker n (%)	0
Postoperative AF n (%)	4 (14.3)
Postoperative MI n (%)	0
Postoperative Stroke n (%)	1 (2)
Postoperative dialysis n (%)	2 (4)
30-day mortality	**2 (4)**

n: number, min: minute, IQR: interquartile range, m: median' AF: atrial fibrillation, MI: myocardial infarction

Table 3. Postoperative Echocardiographic Results (n=48)

Postoperative LVEF (%), m (IQR)	51.73 (30-60)
Aortic stenosis n (%)	0
Aortic insufficiency n (%)	
Mild	10 (20.8)
Moderate	2 (4.16)
Severe	0
Mean Transvalvular Aortic Gradient (mmHg) m(IQR)	7.96 (3-16)
Peak Transvalvular Aortic Gradient (mmHg) m(IQR)	17.04 (8-30)
Peak Aortic Velocity (m/sn) m(IQR)	1.66 (0.8-2.6)
Reconstructed Aortic Valve Length mm	(11.2-16) 14.6
Effective Valve Area (cm^2) m(IQR)	1.75 (0.52-1.9)

n: number, IQR: interquartile range, m: median

and the mean trans-valvular aortic gradient was 50.14 (12-80) mmHg. The mean peak trans-valvular aortic gradient was 79.89 (20-132) mmHg and the mean peak aortic velocity was 4.43 (2.50-5.70) m/s. The mean aortic valve area was 0.81(0.47-2.20) cm2 (Figure 1, Table 1).

Intraoperative data

The mean operation time was 287.5 (167-520) min. The mean CPB time was 190.2 (117-483) min. The mean aortic clamp time was 136.86 (92-232) min (Table 2).

Postoperative data

Fifty patients underwent aortic valve neocuspidization. Two (%4) patients died in the ICU after surgery. One patient was lost due to vasoplegia syndrome, and the other due to multiorgan failure on the postoperative 14th day. The mean ICU length of stay (LOS) was (n=48) 1.75(1-14) days. The mean hospital LOS was 8.57 (1-20) days. None of the patients required a permanent pacemaker, while 4 (%8) patients developed postoperative atrial fibrillation (AF). No postoperative myocardial infarction was observed. One (%2) patient had postoperative hemiparesis and 2 (%4) patients required postoperative hemodialysis (Table 2).

Postoperative echocardiographic data

No additional operative mortality was observed in the early postoperative period. Forty-eight patients were followed up with TTE. The mean postoperative LVEF was 51.73 (30-60). None of the patients had aortic stenosis. Ten (%20.8) patients had mild AI, and 2 (%4.16) had moderate AI. The mean trans-valvular aortic gradient was 7.96 (3-16) mmHg. The mean peak trans-valvular aortic gradient was 17.04 (8-30) mmHg. The mean peak trans-valvular aortic velocity was 1.66 (0.8-2.6) m/s (Figures 2A-2B, Table 3).

Statistics; Continuous variables were presented as median with interquartile range (IQR), and categorical variables as numbers with percentage. Student's t-test was used to compare continuous variables, p-value of 0.05 was considered statistically significant.

Discussion

In this study, we aimed to analyze our results with intraoperative TEE, preoperative and postoperative TTE of the patients who underwent aortic valve neocuspidization in our center. We reached six conclusions in this study. First, aortic valve neocuspidization using autologous pericardium is a reliable and safe procedure with low morbidity and mortality. Second, none of the patients needed reoperation due to AI. Third, no permanent pacemaker placement was needed in our patients.

Fourth, no postoperative valve thrombosis or infective endocarditis were detected. Fifth, postoperative aortic gradients were significantly low. Finally, none of the patients had postoperative aortic stenosis. Ten (%20.8) patients had mild AI, and 2 (%4.16) had moderate AI. The mean trans-valvular aortic gradient was 7.96 (3-16) mmHg.

The mean peak trans-valvular aortic gradient was 17.04 (8-30) mmHg. The mean peak trans-valvular aortic velocity was 1.66 (08-2.6) m/s.

The Ozaki procedure is becoming more prominent for aortic valve pathologies. With the growing experience, studies on valve geometry and techniques with autologous pericardial

reconstruction are increasing, as well as reports on mid-long-term results. These studies show that the Ozaki procedure can be performed safely and perioperative mortality and morbidity are especially low in isolated aortic valve disease patients. No need for anticoagulants, no valve thrombosis complications, no permanent pacemaker requirement, and low rates of infective endocarditis are also advantages of this technique.

Aortic valve neocuspidization was developed as a standardized technique but has been improved by Ozaki since its original conception. Mild or moderate aortic insufficiency is reported as %7 in larger series after isolated Ozaki procedures. Ozaki et al. [8] reported in their study, which included 850 patients with a mean follow-up of 118 months, that there was a significant drop in aortic gradient postoperatively, and %7.3 of the patients developed moderate AI, and 15 patients required reoperation due to AI. Another study by Mourad et al. [9] showed results similar to Ozaki et al, where %7 of the patients developed moderate AI. In the study conducted by Koechline et al. [10], moderate aortic regurgitation was observed in 7%of cases, similar to the studies of Ozaki et al. In our study, 10 (%20.8) patients had mild, and 2 (4.16%) patients had moderate AI postoperatively. Ozaki et al reported a mean peak gradient of 15.2±6.3 mmHg 8 years after surgery. Mourad et al. [9] reported a mean peak gradient of 6.8±2.9 mmHg after 11 months of surgery. In our study, preoperative peak gradient dropped significantly from 50.14 (12-80) mmHg to 7.96 (3-16) mmHg postoperatively.

Most of our patients (46 patients) had tricuspid and 4 patients had bicuspid valves. The preoperative mean aortic valve area was 0.81 (0.47-2.20) and the postoperative mean aortic valve area was 1.75 (0.52-1.9).

We observed mild AI in 10 of the patients and moderate AI in 2 of the patients after surgery, but no patient required reoperation. In the study by Ozaki et al with a mean follow-up duration of 53 months and 850 patients, 15 patients needed reoperation, with a rate of 0.4 cases per 100 cases per year. The study by Mourad et al, which included 52 patients with a mean follow-up of 11 months, reported 5 patients who required a reoperation, with a rate of 10.3 reoperations/100 patients per year. In our follow-up, no patient required a reoperation, while our follow-up time was comparably shorter. On the other hand, in our series, other than isolated Ozaki procedures, 2 patients underwent concomitant CABG, 2 patients underwent concomitant mitral valve repair, and 1 patient underwent concomitant MVR with a biologic prosthesis.

Detailed preoperative echocardiography is highly important for a detailed evaluation. Intraoperative TEE grants useful information about the mechanism of insufficiency, the adequacy of surgical reconstruction, and residual valve pathology [11]. After anesthetic induction, there is sufficient time to confirm findings of preoperative echocardiography, and evaluation of LVEF, aortic and other valve functions. The cardiac anesthesiologist can perform intraoperative TEE to observe the hemodynamics, ensure myocardial protection, and manage fluid replacement more precisely. After CPB, surgical success can be evaluated with a TEE evaluation via mid-esophageal long-axis view at 120°, checking the functions of the reconstructed aortic valve and the aortic annulus width, and via the short-axis view at 40° for planimetric aortic area measurement. The long axis view can provide information on valve pathology, as well as pathologies at the left ventricular septum and the subaortic level.

Measurements of the aortic valve should be performed in the 110-140° long-axis view from leading edge to leading edge.

Transgastric 5 chamber view is essential for the evaluation of aortic insufficiency and the aortic gradient. During weaning from CPB, the fluid balance, contractility, functions of the other valves, and inotrope requirement can be assessed by TEE examination.

In conclusion, autologous pericardial aortic neocuspidization is a safe surgical procedure that eliminates the need for oral anticoagulants and provides stable hemodynamics with a reduced permanent pacemaker requirement. Perioperative TEE examination is essential for this operation to ensure surgical success and a thorough hemodynamic monitorization.

Scientific Responsibility Statement

The authors declare that they are responsible for the article's scientific content including study design, data collection, analysis and interpretation, writing, some of the main line, or all of the preparation and scientific review of the contents and approval of the final version of the article.

Animal and human rights statement

All procedures performed in this study were in accordance with the ethical standards of the institutional and/or national research committee and with the 1964 Helsinki declaration and its later amendments or comparable ethical standards. No animal or human studies were carried out by the authors for this article.

Funding: *None*

Conflict of interest

None of the authors received any type of financial support that could be considered potential conflict of interest regarding the manuscript or its submission.

References

1. Ozaki S, Kawase I, Yamashita H, Uchida S, Nozawa Y, Matsuyama T et al. Institutional report –Valves Aortic valve reconstruction using self-developed aortic valve plasty system in aortic valve disease. Interact Cardiovasc Thorac Surg. 2011; 12(4): 550-3.

2. Lansac E, Di Centa I, Raoux F, Al Attar N, Acar C, Joudinaud T, et al. A lesional classification to standardize surgical management of aortic insufficiency towards valve repair. Eur J Cardiothorac Surg. 2008; 33(5): 872– 80.

3. Doss M, Sirat S, Risteski P, Martens S, Moritz A. Pericardial patch augmentation for repair of incompetent bicuspid aortic valves at midterm. Eur J Cardiothorac Surg 2008; 33(5): 881–4.

4. Duran CMG, Gometza B, Kumar N, Gallo R, Martin-Duran R. Aortic valve replacement with freehand autologous pericardium. J Thorac Cardiovasc Surg. 1995;110(2): 511-6.

5. Ozaki S, Kawase I, Yamashita H, Uchida S, Nozawa Y, Takatoh M, et al. A total of 404 cases of aortic valve reconstruction with glutaraldehyde-treated autologous pericardium. J Thorac Cardiovasc Surg. 2014; 147(1): 301-6.

6. Doenst T, Kirov H, Moschovas A, Gonzalez-Lopez D, Safarov R, Diab M, et al. Cardiac surgery 2017 reviewed. Clin Res Cardiol. 2018; 107(12): 1087-102.

7. Sá MPBO, Perazzo ÁM, Zhigalov K, Komarov R, Kadyraliev B, Enginoev S, et al. Aortic Valve Neocuspidization with Glutaraldehyde-Treated Autologous Pericardium (Ozaki Procedure) - A Promising Surgical Technique. Braz J Cardiovasc Surg. 2019; 34(5): 610-4.

8. Ozaki S, Kawase I, Yamashita H, Uchida S, Takatoh M, Kiyohara N. Midterm outcomes after aortic valve neocuspidization with glutaraldehyde-treated autologous pericardium. J Thorac Cardiovasc Surg. 2018; 155(6): 2379-87.

9. Mourad F, Shehada SE, Lubarski J, Serrano M, Demircioglu E, Wendt D, et al. Aortic valve construction using pericardial tissue: short-term single-centre outcomes. Interact Cardiovasc Thorac Surg. 2019; 28(2): 183-90.

10. Koechlin L, Schurr U, Miazza J, Imhof S, Maurer M, Erb J, et al. Echocardiographic and Clinical Follow-up After Aortic Valve Neocuspidization Using Autologous Pericardium. World Journal of Surgery. 2020; 44(9): 3171-81

11. Vanoverschelde JL, van Dyck M, Gerber B, Vancraeynest D, Melchior J, de Meester C, et al. The role of echocardiography in aortic valve repair. Ann Cardiothorac Surg. 2013; 2(1): 65-72.

How to cite this article:

Mustafa Şimşek, Sena Sert, Türkan Kudsioğlu. *Management of intraoperative transesophageal echocardiography in aortic valve neocuspidization (Ozaki procedure). Ann Clin Anal Med 2022; DOI: 10.4328/ACAM.21292*