Annals of Clinical and Analytical Medicine
Original Research

Factors affecting mortality and morbidity in patients with sternum fracture

Sternal fractures

Yeliz Gul[1], Muharrem Cakmak[2], Siyami Aydin[2], Evrim Gul[3]
[1] Department of Radiology, Faculty of Medicine, Health Science University, Fethi Sekin Education and Research Hospital
[2] Department of Thoracic Surgery, Faculty of Medicine, Firat University
[3] Department of Emergency, Faculty of Medicine, Firat University, Elazig, Turkey

Abstract

Aim: Closed sternal fractures are deceleration injuries that occur as a result of blunt trauma. In these fractures, cardiac and great vessel injury probability is higher than that of other blunt traumas. Since they are caused by high-energy traumas, they can be accompanied by internal organ injury, chest wall injury, and head and spine traumas. Clinical findings can be very different according to other organ injuries and concomitant pathologies. In our study, we aimed to evaluate the outcomes of patients with post-traumatic sternal fracture.

Material and Methods: Files of 348 patients with sternal fractures presenting to the emergency department and thoracic surgery clinic between 2011 and 2020 were evaluated retrospectively. The patients were divided into two groups as group 1 (patients with sternal fractures and other organ injuries (non-isolated sternal fractures)) and group 2 (isolated sternal fractures).

Results: When the demographic distributions of the patients were evaluated, gender and etiological differences were not significant between the groups. In terms of concomitant pathologies, rib fracture, lung contusion, pneumothorax, and hemothorax were the most common in Group 1 patients, while skin abrasion was observed in Group 2. Concomitant organ injuries were most common in the liver and spleen in Group 1 patients, while there was no concomitant pathology in Group 2. CWIS was 2 in 252 of Group 1 patients, and the mean ISS was 20.07 ± 6.51. On the other hand, CWIS was 1 in all Group 2 patients, and the mean ISS was 7.90 ± 8.64. Group 1 ISS values were statistically significant compared to Group 2. Concomitant pathology or organ injury is the cause of increased mortality and morbidity in patients with sternum fractures.

Discussion: The chest wall injury scoring system is a guide for surgery in those patients. The injury severity score, on the other hand, increases in direct proportion to the severity of the trauma and should be considered an effective parameter for demonstrating the severity of the injury.

Keywords
Morbidity, Mortality, Trauma, Sternal Fracture

DOI: 10.4328/ACAM.21362 Received: 2022-08-17 Accepted: 2022-09-21 Published Online: 2022-09-26
Corresponding Author: Evrim Gul, Firat University Faculty of Medicine, Emergency Department, Elazig, Turkey.
E-mail: evrimgl@yahoo.com.tr P: +90 424 233 35 55 F: +90 424 233 35 55
Corresponding Author ORCID ID: https://orcid.org/0000-0001-9049-5446

Introduction

Closed Sternal fractures are deceleration injuries that occur as a result of blunt trauma. The most common cause is traffic accidents. Fractures are typically in the transverse plane and are more frequently localized in the upper-middle part. In these patients, cardiac and great vessel injury probability is higher than that of other blunt traumas. Since they are caused by high energy traumas, internal organ injury, chest wall injury, and head and spine traumas may accompany them. Clinically, the most common complaint is localized tenderness and respiratory distress with pain over the sternum. Clinical findings can be very different according to other organ injuries and concomitant pathologies [1].

The diagnosis is best made by lateral chest X-ray. Because of myocardial contusion and pericardial effusion risk, patients should be monitored with electrocardiography (ECG) and echocardiography (ECO) [1]. If there is no open fracture or excessively separated fracture ends, pain and secretion control and supine bed rest for 2-3 weeks are sufficient in the treatment. Open reduction and fixation may be required in displaced sternal fractures [2]. In our study, we aimed to evaluate the outcomes of patients with post-traumatic sternal fracture.

Material and Methods

Ethics committee approval was received for the study (approval date and number: 22.11.2021-5194). The files of 348 patients with sternal fractures presenting to the emergency department and thoracic surgery clinic between 2011 and 2020 were evaluated retrospectively.

The patients were divided into two groups as Group 1 (patients with sternal fractures and other organ injuries (non-isolated sternal fractures), n = 302) and Group 2 (isolated sternal fractures, n = 46). Age, gender, symptoms, localization of fractures, radiological findings, diagnosis and treatment methods, complications, concomitant pathologies, concomitant injuries, CWIS (increasing trauma severity from 1 to 5), ISS (>16; serious injury), mortality, and morbidity rates were recorded.

IBM SPSS Statistics Base 22.0 program (IBM Corporation, Armonk, NY, USA) was used for data analysis. Continuous variables were expressed as mean ± standard deviation (SD), while categorical variables as number-ratio. Homogeneity analysis of variances was performed using Levene's test ($p>0.05$). The Shapiro-Wilk test was used to evaluate the normal distribution ($p>0.05$). Results were evaluated with the Fisher's Exact and Mann-Whitney-U tests. $P<0.05$ was considered significant.

Results

The total number of patients was 348 and the mean age was 53.59 ± 18.50. Etiological causes were traffic accidents in 183 (53%), falls from a height in 116 (33%), and workplace accidents in 49 (14%). Of the patients, 218 (63%) were male and 130 (37%) were female (Table 1).

The most common complaints of the patients were chest pain, shortness of breath, chest wall tenderness, and ecchymosis. While the main diagnostic method was the physical examination and posteroanterior and lateral chest radiography, all patients

Table 1. Demographic distribution of patients

Demographic distribution	Total: 348	Group 1: 302	Group 2: 46	p
Mean age	53,59 ± 18,50	52,88 ± 18,23	58,02 ± 19,88	
Male	218, %63	190, %63	28, %61	0.8703 (p>0.05)
Female	130, %37	112, %37	18, %39	
Traffic accident	183, %53	161, %53	22, %48	
Falling from a height	116, %33	102, %34	14, %30	p>0.05
Workplace accidents	49, %14	39, %13	10, %22	

Table 2. Concomitant pathologies and injuries

Concomitant pathologies and injuries	Group 1: 302	Group 2: 46
Localized hematoma in the anterior mediastinum	12, %4	1, %2
Staining in the anterior mediastinum	19, %6	1, %2
Skin abrasion	29, %10	2, %4
Subcutaneous hematoma on the sternum	5, %2	1, %2
Widespread ecchymosis and bruises on the skin	27, %9	1, %2
Rib fracture	151, %50	-
Contusion	54, %18	-
Pneumothorax	43, %14	-
Hemothorax	22, %7	-
Liver grade 1 laceration	1, %0,33	-
Liver grade 2 laceration	7, %2	-
Spleen grade 1 laceration	3, %1	-
Kidney grade 1 laceration	2, %1	-
Vertebral fracture	11, %4	-
Clavicle fracture	6, %2	-
Scapula fracture	2, %1	-
Sternum fracture + rib fracture + pneumothorax	40, %13	-
Sternum fracture + rib fracture + contusion	46, %15	-
Sternum fracture + rib fracture + hemothorax	22, %7	-
Sternum fracture + rib fracture + liver grade 1 laceration	1, %0,33	-
Sternum fracture + rib fracture + liver grade 2 laceration	7, %2	-
Sternum fracture + rib fracture + spleen grade 1 laceration	3, %1	-
Sternum fracture + rib fracture + kidney grade 1 laceration	2, %1	-
Sternum fracture + rib fracture + vertebral fracture	10, %3	-
Sternum fracture + rib fracture + clavicle fracture	4, %1	-
Sternum fracture + rib fracture + scapula fracture	2, %1	-

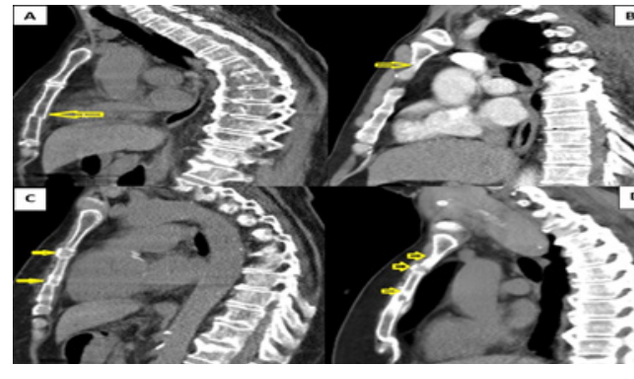

Figure 1. A; Sternum corpus fracture, B: Sternum manubrium fracture, C: Fracture of sternum corpus and the junction of the corpus and the manubrium, D: Fracture of sternum corpus, manubrium and the junction of the corpus and the manubrium.

Table 3. Patient scores with sternal fracture

Scores	Group 1: 302	Group 2: 46	p
CWIS 1	-	46, %100	
CWIS 2	252, %83	-	
CWIS 3	38, %13	-	
CWIS 4	9, %3	-	
CWIS 5	3, %1	-	
ISS	20.07 ± 6.51	7.90 ± 8.64	< 0,05

CWIS: Chest Wall Injury score, ISS: Injury severity score

with non-isolated sternal fractures underwent computed tomography for general evaluation.

All patients underwent ECG, 15% had ECO, and 3 (1%) had pericardial fluid. It was observed that pericardial fluid did not increase in the follow-ups and no intervention was required.

Fractures were found in the corpus sternium in 281 (81%) patients, in the manubrum sternium in 61 (17%), in both the corpus and the junction of the corpus and manubrium in 4 (1%), and in the manubrium, corpus, and the junction of manubrium in 2 (1%) patients (Figure 1).

When the demographic distributions of the patients were evaluated, gender and etiological differences were not significant between the groups (p>0.05).

In terms of concomitant pathologies, rib fracture, lung contusion, pneumothorax, and hemothorax were the most common in Group 1 patients, while skin abrasion was observed in Group 2. Concomitant organ injuries were most common in the liver and spleen in Group 1 patients, while there was no concomitant pathology in Group 2 (Table 2).

CWIS was 2 in 252 (83%) of Group 1 patients, and the mean ISS was 20.07 ± 6.51. On the other hand, CWIS was 1 in all Group 2 patients, and the mean ISS was 7.90 ± 8.64. Group 1 ISS values were statistically significant compared to Group 2 (p<0.05) (Table 3).

In the treatment, 216 (72%) patients in Group 1 patients underwent medical treatment, 71 (23%) underwent tube thoracostomy, 4 (1%) underwent subcutaneous hematoma evacuation, 6 (2%) underwent emergency thoracotomy (parenchymal repair + hematoma evacuation), and 5 (2%) underwent laparoscopy. On the other hand, all patients in Group 2 were given medical treatment and followed up. In Group 1, 17 (6%) patients were taken to the intensive care unit due to respiratory distress and changes in consciousness during their follow-up, and 9 (3%) of these died. In one patient who underwent hematoma evacuation, purulent discharge developed. However, no growth in the culture was observed and it improved with medical treatment. All of the patients who died had a CWIS score of 5, and the mean ISS was 25.07 ± 1.56.

The general approach in medical treatment is antibiotherapy (amoxicillin + clavulanic acid or cephalosporin group or 3rd generation antibiotics), narcotic (Tramadol) or non-narcotic analgesics (non-steroidal anti-inflammatories), mucolytic expectorants (N-acetyl cysteine group), bronchodilators, balanced fluid replacement, and in some patients, especially those with extensive contusion, fluid restriction, diuretic therapy, pentoxifylline, and steroid therapy.

Discussion

Closed sternal fractures are deceleration injuries and occur as a result of blunt traumas in the anterior thoracic region [2]. The most common cause of sternal fractures detected in less than 5% of patients with blunt thoracic trauma is motor vehicle accidents with a rate of 60-90% [3, 4]. The rate of sternal fracture in traffic accidents is 4%. The frequency of these fractures, which often occur in people sitting in the front seats due to traffic accidents, has increased in recent years, with the compulsory use of seat belts [3, 5, 6]. While seat belts have led to significant reductions in serious injuries in traffic accidents, this has created a new spectrum of injuries that are less life-threatening. Fractures are typically in the transverse plane and are more frequently localized in the upper and middle parts. It often develops as a transverse fracture in the upper or middle part of the sternum body [3]. In our study, the most common etiologic cause was traffic accident with a rate of 53%, and the most common fracture localization was corpus sterni with 81%. Sternal fractures are more common in women and the elderly. Patients generally present with localized pain in the anterior chest wall that increases with deep breathing [7, 8]. The presence of pain and tenderness over the sternum should suggest a sternal fracture. On physical examination, tenderness, ecchymosis, and crepitation at the fracture line can be detected by palpation. In our study, 218 (63%) of the patients were male and 130 (37%) were female. The most common complaints were chest pain, shortness of breath, chest wall tenderness, and ecchymosis.

Although anamnesis and physical examination findings may be instructive, the diagnosis is usually made by lateral chest X-ray [2]. In polytraumatized and painful patients and in cases where lateral radiographs cannot be taken due to the inability to position, CT can be used in the diagnosis, which can show a cardiac injury (pericardial effusion, contusion). The mortality rate in isolated sternal fractures is less than 1% [1, 8]. The risk of myocardial injury in the presence of sternal fracture is one of the first issues to be considered. ECG changes occur in 61% of sternal fractures and myocardial contusion develops in 18%. Because of the risk of myocardial contusion, ECG should be taken and, if necessary, the presence of pericardial effusion should be investigated by echocardiography [9, 10]. In our study, the main diagnostic method was physical examination findings, and postero-anterior and lateral chest radiographs. All patients underwent ECG, 15% had ECO, and 3 (1%) patients had pericardial fluid. It was observed that pericardial fluid did not increase in the follow-ups and no intervention was required. In order for a fracture to occur in the sternum, the severity of the trauma must be high. Therefore, rib fracture and long bone fractures may accompany. At least 20% of them also have serious head trauma. Due to the high force applied to the sternum, the probability of both cardiac and great vessel injury in these fractures is higher than in other blunt traumas. Serious intrathoracic injury accompanies 57% of the cases [3]. Concomitant injuries can be grouped into three main groups: internal organ injury, chest wall injury, and head and spine trauma. Rib fractures, flail chest, and sternoclavicular dislocation can be seen as chest wall injuries. As a result of internal organ injuries, pneumothorax, hemothorax, cardiac

tamponade, cardiac and pulmonary contusion, diaphragmatic and abdominal injuries may develop [2, 10]. Compression fractures of the thoracic vertebrae in addition to head, neck, and extremity injuries are other concomitant injuries. The incidence of pulmonary injury, pericardial effusion, vertebral and rib fractures increases with separated, unstable sternal fractures [6]. The risk of cardiac injury with a sternal fracture ranges from 18 to 62%. The incidence of myocardial contusion after fracture in the sternum has been reported to be 6-12% [3, 10, 11].

Chest Wall Injury Scale (CWIS) is a method that covers sternum fracture and is scored between 1 and 5 according to the status of laceration or avulsion in the soft tissue and skin. It helps to determine the treatment method according to the condition of the injury to the chest wall. In a study involving 88 patients, this scale system was reported to be a guide for the decision of surgical intervention, and mortality and morbidity increased as the scores increased [12]. In our study, CWIS elevation may be a guide for surgical treatment. However, the increase in mortality despite surgery varies according to the condition of the concomitant injuries.

Injury severity score (ISS) is a scoring system that defines the total severity of injury in persons with multiple body injuries. It is associated with mortality, morbidity, and length of hospital stay. With ISS, injuries that are not life-threatening have been shown to significantly affect mortality when combined with injuries to other organs. If the ISS is greater than 16, major trauma is present [13]. In our study, the mean ISS in Group 1 was 20.07 ± 6.51, while in Group 2, the mean ISS value was 7.90 ± 8.64. When the groups were compared in terms of ISS values, Group 1 ISS value was significantly higher than that of Group 2 ($p<0.05$).

Treatment of isolated sternal fractures consists of pain control and pulmonary hygiene. In the treatment, supine bed rest, analgesic therapy, and respiratory physiotherapy are performed in the straight position. Pain may persist for up to six weeks. Full stabilization occurs in about two months. In the treatment, if there are no open fractures or excessively separated fracture ends, pain and secretion control and supine bed rest for 2-3 weeks are sufficient [2, 3].

Open reduction and fixation may be required in severe sternal fractures. If there are no excessively split ends and open fractures, the appropriate treatment is the conservative approach. If there are severely split ends, open fractures, or separation of the ribs from the costochondral junction, open reduction and fixation of the sternum can be performed using a median incision and wire sutures. Surgical treatment indications in sternal fractures were the excessive separation of the fracture lines, the presence of fractures that cause flail chest and respiratory failure requiring mechanical ventilation, and the formation of a bad appearance due to the overlapping of the fracture lines [2, 3, 14-16]. In our study, 216 (72%) of Group 1 patients received medical treatment, 71 (23%) tube thoracostomy, 4 (1%) subcutaneous hematoma evacuation, 6 (2%) emergency thoracotomy (parenchymal repair + hematoma evacuation), and 5 (2%) laparoscopy, while all of the Group 2 patients were given medical treatment and followed up.

A total of 17 (6%) patients in Group 1 were taken to the intensive care unit due to respiratory distress and changes in consciousness during their follow-up and 9 (3%) of the patients died. In one patient who underwent hematoma evacuation, purulent discharge developed. Yet, no growth in the culture was observed and it improved with medical treatment. The general approach in medical treatment included antibiotics, narcotic or non-narcotic analgesics, mucolytic expectorants, bronchodilators, balanced fluid replacement, and even fluid restriction, diuretic therapy, pentoxifylline, and steroid therapy in some patients, especially in those with an extensive contusion.

Conclusion

Concomitant pathology or organ injury is the cause of increased mortality and morbidity in patients with sternum fractures. The Chest Wall injury scoring system is a guide for surgery in those patients. The injury severity score, on the other hand, increases in direct proportion to the severity of the trauma and should be considered an effective parameter in demonstrating the severity of the injury.

Scientific Responsibility Statement

The authors declare that they are responsible for the article's scientific content including study design, data collection, analysis and interpretation, writing, some of the main line, or all of the preparation and scientific review of the contents and approval of the final version of the article.

Animal and human rights statement

All procedures performed in this study were in accordance with the ethical standards of the institutional and/or national research committee and with the 1964 Helsinki declaration and its later amendments or comparable ethical standards. No animal or human studies were carried out by the authors for this article.

Funding: *None*

Conflict of interest

None of the authors received any type of financial support that could be considered potential conflict of interest regarding the manuscript or its submission.

References

1. Hossain M, Ramavath A, Kulangara J, Andrew JG. Current management of isolated sternal fractures in the UK: Time for evidence based practice? A cross-sectional survey and review of literature. Injury. 2010;41(5):495–8.

2. Alent J, Narducci DM, Moran B, Coris E. Sternal Injuries in Sport: A Review of the Literature. Sports Med. 2018;48(12):2715-24.

3. Turhan K, Cakan A, Ozdil A, Cagırıcı U. Traumatic sternal fractures: diagnosis and management. Aegean Medical Journal. 2010;49:107-11.

4. Oyetunji TA, Jackson HT, Obirieze AC, Moore D, Branche MJ, Greene WR, et al. Associated injuries in traumatic sternal fractures: a review of the National Trauma Data Bank. Am Surg. 2013;79(7):702-5.

5. Teixeira PG, Georgiou C, Inaba K, Dubose J, Plurad D, Chan LS, et al. Blunt cardiac trauma: lessons learned from the medical examiner. J Trauma. 2009;67(6):1259-64.

6. Knobloch K, Wagner S, Haasper C, Probst C, Krettek C, Otte D, et al. Sternal fractures occur most often in old cars to seat-belted drivers without any airbag often with concomitant spinal injuries: Clinical findings and technical collision variables among 42,055 crash victims. Ann Thorac Surg. 2006;82(2):444–50.

7. Graeber GM, Prabhakar G, Shilds TW. Blunt and penetrating injuries of the chest wall, pleura, and lungs. In: ShildsTW, LoCicer J, Poon RB, eds. General thoracic Surgery Vol. 1. Philadelphia: Lippincott Williams&Wilkins; 2005. p. 951-71.

8. Meyer DM. Hemothorax Related to Trauma. Thorac Surg Clin. 2007;17(1):47-55.

9. Jin W, Yang DM, Kim HC, Ryu KN. Diagnostic values of sonography for assessment of sternal fractures compared with conventional radiography and bone scans. J Ultrasound Med. 2006;25(10):1263-8.

10. Sybrandy KC, Cramer MJ, Burgersdijk C. Diagnosing cardiac contusion: Old wisdom and new insights. Heart. 2003;89(5):485-9.

11. Bar I, Friedman T, Rudis E, Shargal Y, Friedman M, Elami A. Isolated sternal fracture - a benign condition? Isr Med Assoc J. 2003;5(2):105-6.

12. Taylor BC, Fowler TT, French BG, Dominguez N. Clinical Outcomes of Surgical Stabilization of Flail Chest Injury. J Am Acad Orthop Surg. 2016;24:575-80.

13. Grimal Q, Naili SS, Watzky A. A high-frequency lung injury mechanism in blunt thoracic impact. J Biomech. 2005;38(6):1247-54.

14. Schulz-Drost S, Ekkernkamp A, Stengel D. Epidemiology, injury entities and treatment practice for chest wall injuries: Current scientific knowledge and

treatment recommendations. Unfallchirurg. 2018;121(8):605-14.
15. Apaydın T, Arapi B, Basaran C. Surgical reconstruction of traumatic flail chest with titanium plaques. Int J Surg Case Rep. 2018;50:72-4.
16. Dongel I, Coskun A, Ozbay S, Bayram M, Atli B. Management of thoracic trauma in emergency service: Analysis of 1139 cases. Pak J Med Sci. 2013;29(1):58-63.

How to cite this article:
Yeliz Gul, Muharrem Cakmak, Siyami Aydin, Evrim Gul. *Factors affecting mortality and morbidity in patients with sternum fracture. Ann Clin Anal Med 2022; DOI: 10.4328/ACAM.21362*