Annals of Clinical and Analytical Medicine
Original Research

Optical coherence tomography findings in patients with beta thalassemia major

Cenk Zeki Fikret[1], Filiz Yildirim[2], Nil Irem Ucgun[3], Ozlem Evren Kemer[3]
[1] Department of Ophthalmology, Ankara City Hospital
[2] Clinic of Internal Medicine, Polatlı Duatepe Goverment Hospital
[3] Department of Ophthalmology, University of Health Sciences, Ankara City Hospital, Ankara, Turkey

Abstract

Aim: In this study, we aimed to evaluate macular ganglion cell layer + (GCL+), retinal nerve fiber layer (RNFL), choroidal thickness and Hood report pathologies with swept-source optical coherence tomography (SS-OCT) in beta-thalassemia major patients.

Material and Methods: Twenty-four eyes of 24 multi and regular blood transfused beta-thalassemia major patients on chelation therapy (thalassemic group) and age- and sex- matched 25 eyes of 25 healthy individuals (control group) were included in the study. Macular GCL+, peripapillary total RNFL, and subfoveal choroidal thickness measurements were obtained in patients with beta-thalassemia major. SS-OCT images were collected from Topcon DRI OCT Triton SS-OCT (Topcon, Tokyo, Japan). Glaucoma and Hood reports were derived from Rescan 3D(H)+Line(H) mode. Choroidal thickness was measured from macular radial mode.

Results: In the thalassemic group, the mean values were 74.00±7.18 µm for macular GCL+ thickness; 122.75±11.37 µm for total RNFL; 423.08±32.64 µm for choroidal thickness; 255.50±18.48 µm for macular thickness. In the control group, the mean values were 61.84±8.04 µm for macular GCL+ thickness; 108.88±4.98 µm for total RNFL; 323.00±26.94 µm for choroidal thickness; 249.12±17.07 µm for macular thickness. GCL+, total RNFL and choroidal thickness in the thalassemic group were significantly thicker than in the control group ($p<0.001$). There was no difference between the two groups in terms of macular thickness ($p>0.05$). There was a positive correlation between choroidal thickness and ferritin levels in the thalassemic group ($r=0.630$, $p<0.01$).

Discussion: RNFL and GCL+ values are important, but we must also review the Glaucoma and Hood reports on patients with beta thalassemia major to detect ocular involvement. Choroidal thickness measurements should also be performed in these patients. The positive correlation between ferritin levels and choroidal thickness in thalassemic patients suggests that ferritin levels may be effective in ocular findings.

Keywords

Thalassemia Major, GCL, RNFL, Choroidal Thickness, OCT

DOI: 10.4328/ACAM.21028 Received: 2021-12-27 Accepted: 2022-02-10 Published Online: 2022-02-28
Corresponding Author: Filiz Yildirim, Clinic of Internal Medicine, Polatlı Duatepe Goverment Hospital, Polatlı, 06900, Ankara, Turkey.
E-mail: drfyildirim@yahoo.com P: +90 544 411 22 89 F: +90 312 243 10 12
Corresponding Author ORCID ID: https://orcid.org/0000-0002-6151-2697

Introduction

Beta-thalassemia is a hereditary blood disease with a beta chain synthesis anomaly of hemoglobin. Beta-thalassemia can either be asymptomatic or cause severe anemia. It is classified as Beta-thalassemia major, intermedia and minor. Beta-thalassemia major is also named "Cooley's Anemia" and "Mediterranean Anemia". Individuals with beta-thalassemia major are usually visible in the first two years of life. It progresses with severe anemia that requires regular red blood cell transfusion. Beta-thalassemia intermedia is a disease accompanied with milder anemia, rarely requiring red blood cell transfusion. Beta-thalassemia minor is observable in asymptomatic individuals who have the disease with mild anemia [1].

Beta-thalassemia can cause some ocular abnormalities as a result of anemia, blood transfusion, iron overload, and chelation therapy. Jafari et al. [2] detected ocular pathologies, including dry eye, cataract, color vision deficiency, visual field defects, and retinal pigment epithelium degeneration in thalassemic patients. Barteselli et al. [3] detected pseudoxanthoma elasticum-like (PXE-like) changes, which are peau d'orange, angioid streaks, pattern dystrophy-like changes, and optic disc drusen. It has been reported that increased retinal vascular tortuosity is a common finding in patients with beta-thalassemia major. Pigmentary degeneration occurs in the macula and peripheral retina secondary to desferrioxamine treatment used in patients with beta-thalassemia major. It has been reported that macular monitoring with fundus autofluorescence is useful in detecting desferrioxamine toxicity. Night blindness, visual field defects, deterioration in color vision, abnormal dark adaptation, and decreased visual acuity due to optic neuropathy have been reported after high doses of desferrioxamine treatment [4, 5].

Measurement of retinal nerve fiber layer (RNFL) and ganglion cell layer (GCL) thickness by optical coherence tomography is important for the detection of optic nerve pathologies. Some authors have reported in the literature that RNFL thicknesses are thinning or not changing in Beta-thalassemia patients [6, 7].

It is frequently reported that visual loss of function and RNFL thinning are parallel. It is widely used to follow optic nerve pathologies with RNFL, but in diseases such as optic disc edema, RNFL can be measured thick despite thinning [8, 9]. Therefore, it is necessary to evaluate GCL and RNFL together and even Hood report to detect suspected optic nerve involvement in patients. In this study, we aimed to examine the changes at Hood report parameters in macular GCL+ and RNFL in patients with beta-thalassemia major.

Material and Methods

Ankara City Hospital Ethics Committee approval (E1-1321-2020) was obtained for this study, the tenets of the Declaration of Helsinki were observed.

All data were evaluated retrospectively. All individuals included in our study were examined between May 2019 and November 2021 in Ophthalmology Department.

Twenty-four eyes of 24 multi and regular blood transfused beta-thalassemia major patients Thalassemic group on chelation therapy (thalassemic group) and age and sex-matched 25 eyes of 25 healthy individuals (control group) were included in the study. Detailed ophthalmic examination and SS-OCT analyses were performed in all beta-thalassemia major patients and healthy individuals. SS-OCT images were collected from Topcon DRI OCT Triton, SS-OCT (Topcon, Tokyo, Japan). Glaucoma, Hood report were obtained from Rescan 3D(H)+Line(H) mode. Choroidal thickness was measured in macular radial mode. Macular GCL+ (GCL+ inner plexiform layer), peripapillary total RNFL and subfoveal choroidal thickness were analyzed in both group. GCL thickness and probability maps were acquired from macular cube scans. RNFL thickness and probability maps were obtained from disk cube scans.

The exclusion criteria were retinal abnormalities, optic disc disorders, cup/disc ratio abnormalities, intraocular pressure higher than 21 mmHg, neurological disease, myopia or hyperopia >3.0 diopters, corneal abnormalities, history of ocular surgery or ocular trauma.

Statistical Analysis

Statistical analyses were performed using the program SPSS. An independent t-test and Mann-Whitney U test were used for statistical analysis of the data. A p -value less than 0.05 was considered statistically significant. The quantitative data were presented as mean± standard deviation (SD). Pearson's correlation test was utilized to evaluate the relationship between the data.

Results

The mean age was 24.42±4.60 (18-38) years in beta-thalassemia major patients, and 25.44±5.08 (19-37) years in healthy individuals (p=0.464). There were 15 females and 9 males in the thalassemic group, and 14 females and 11 males in the control group (p=0.664). There was no difference between the two groups in terms of gender and age.

Intraocular pressure in the thalassemic group was 15.08±2.16 (11-18) and 15.04±2.09 (11-19) mmHg (p=0.943) in the control group.

GCL+, total RNFL and choroidal thickness in the thalassemic group were significantly thicker than in the control group (p<0.05). Table 1 shows macular GCL+, RNFL, macular and choroidal thickness measurements, IOP, ferritin and hemoglobin levels (mean±SD) in both groups.

RNFL thickness and GCL+ Macula 6 Sector Grid thickness increased in 62.5% of our patients as observed in Patient A. There is also extreme thickening in GCL+ thickness (retinal view) in the Hood report (Figure 1). We named this view 'super normal GCL'. No retinal or optic nerve pathologies such as macular edema or vitreomacular traction syndrome were found in these patients to explain this view.

In 37.5% of our beta-thalassemia major patients, as in Patient B, RNFL and GCL+ Macula 6 Sector Grid thickness measurements were consistent with their age. Hood reports of these patients showed thinning at GCL+ thickness (Retinal view) (Figure 2). We named this view 'unsurprisingly GCL', because this appearance was as described in the literature for beta-thalassemia major patients.

Serum ferritin levels were 1570.12±253.57 ng/mL and hemoglobin levels were 9.86±1.06 (gr/dL) in the patients with beta-thalassemia major.

All patients with beta-thalassemia major were receiving

Table 1. Comparison of data of patients in thalassemia and control groups (mean±SD)

	Thalessemia group	Control group	p
Intraocular pressure (mmHg)	15.08±2.16	15.04±2.09	0.943
Ferritin (ng/mL)	1570.12±253.57	102.52±39.87	<0.001*
Hemoglobin (gr/dL)	9.86±1.06	13.64±0.78	<0.001*
Total Retinal nerve fibre layer (µm)	122.75±11.37	108.88±4.98	<0.001*
Ganglion cell layer (µm)	74.00±7.18	61.84±8.04	<0.001*
Macular thickness (µm)	255.50±18.48	249.12±17.07	0.215
Choroidal thickness (µm)	423.08±32.64	323.00±26.94	<0.001*

* p <0.05 was considered statistically significant

deferoxamine therapy as chelating agents.

Serum ferritin levels were 102.52±39.87 ng/mL and hemoglobin levels were 13.64±0.78 (gr/dL) in the control group. Ferritin levels were higher in the thalassemic group (p<0.001) and hemoglobin levels were higher in the control group (p<0.001).

A positive correlation was found between choroidal thickness and ferritin levels in the thalassemic group (r=0.630, p<0.01), (Figure 3). A negative correlation was found between choroidal thickness and age in both groups (p<0.05).

There was no correlation between serum ferritin levels and RNFL, GCL+, macular thickness in beta-thalassemia major patients.

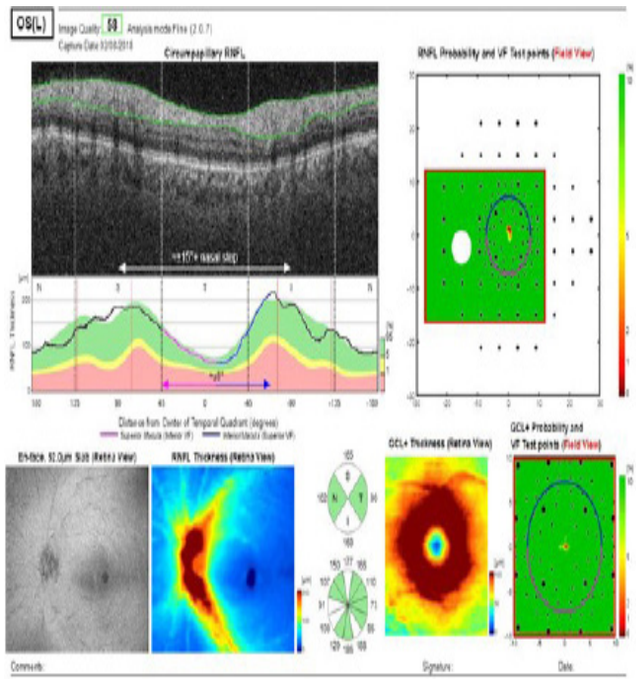

Figure 1. Glaucoma report of patient A 38 years old, female with beta-thalassemia major, intraocular pressure 16 mm Hg: Supernormal

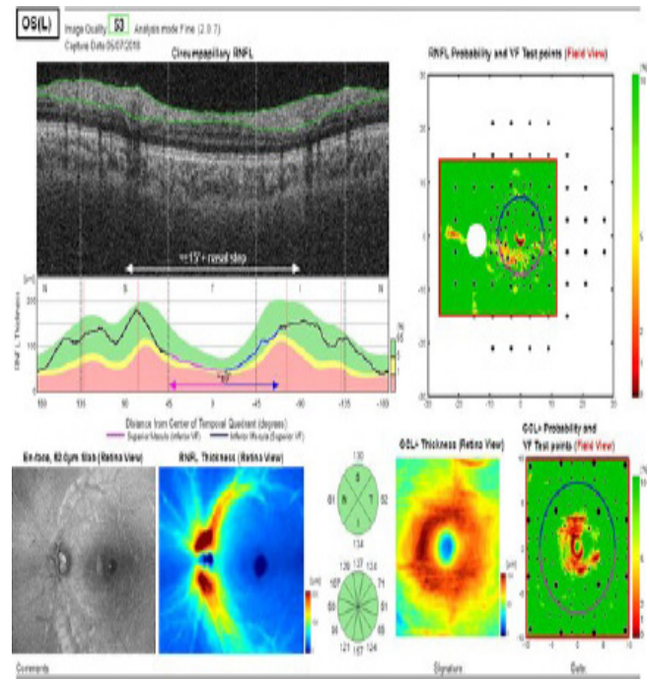

Figure 2. Hood report of patient B 21 years old, male withbeta-thalassemia major, intraocular pressure 15 mm Hg: Unsurprisingly

Table 2. Correlation between total retinal nerve fiber layer, ganglion cell layer, macular thickness, choroidal thickness values and age, intraocular pressure, ferritin, hemoglobin values in thalassemic and control groups

			Age	Intraocular pressure	Ferritin	Hemoglobin
Thalessemic group	Total retinal nerve fiber layer	r	0.323	0.264	-0.104	-0.005
		p	0.124	0.212	0.628	0.982
	Ganglion cell layer +	r	0.180	-0.098	0.368	-0.200
		p	0.400	0.649	0.077	0.350
	Macular thickness	r	0.016	-0.157	0.016	-0.106
		p	0.941	0.462	0.940	0.621
	Choroidal thickness	r	-0.495	-0.458	0.630	-0.235
		p	0.014	0.024	0.001	0.265
Control group	Total retinal nerve fiber layer	r	-0.022	0.304	-0.067	-0.021
		p	0.915	0.139	0.751	0.563
	Ganglion cell layer +	r	-0.056	-0.057	-0.043	-0.192
		p	0.789	0.788	0.838	0.359
	Macular thickness	r	0.213	-0.151	0.101	0.146
		p	0.306	0.472	0.632	0.486
	Choroidal thickness	r	-0.400	-0.313	0.207	-0.066
		p	0.048	0.128	0.321	0.755

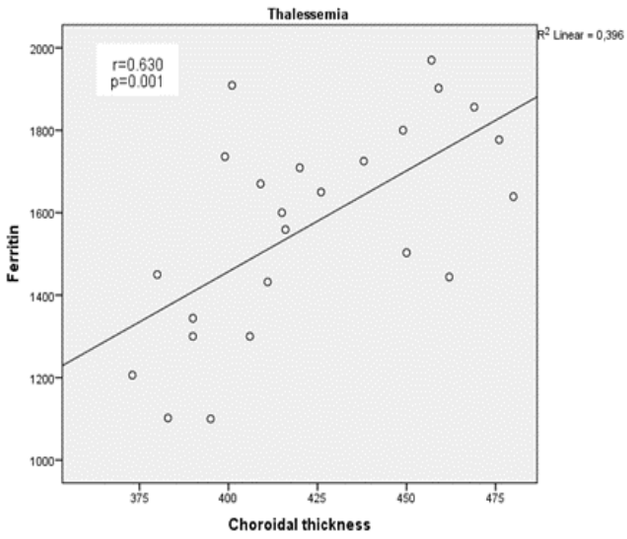

Figure 3. There was possitive correlation between ferritin levels and choroidal thickness in Thalassemia patients.

Discussion

In this study, we found that total RNFL, GCL+ and choroidal thickness were significantly thicker in patients with beta-thalassemia major compared to the control group. There was a positive correlation between choroidal thickness and ferritin levels in the thalassemic group.

Ulusoy et al. [10] did not find any difference between beta-thalassemia major patients and the control group when they measured RNFL and GCL+ thicknesses with spectral domain OCT. They found that choroidal thickness is significantly thinner in patients with beta-thalassemia major. Some authors found thinner RNFL measurements in children with beta-thalassemia major. They also reported a correlation between RNFL thickness and serum ferritin and hemoglobin levels in thalassemic patients [6, 11].

There are studies reporting choroidal thinning in pediatric thalassemic patients [12, 13]. Reinera et al. [14] investigated that blood pressure and blood volume signals can trigger parasympathetic vasodilation of the choroidal vasculature. This may be the reason why we measure the choroid thicker in patients with beta-thalassemia major.

Ocular involvement occurs in up to 85% of thalassemic patients. Retina is the most commonly affected ocular tissue. These patients receive blood transfusions as a result of severe anemia. Repeated transfusions are the cause of siderosis. Iron accumulates in the retinal pigment epithelium (RPE) and causes an increase in oxidative stress. Retinal findings are observed as degeneration of the RPE, retinal venous blood engorgement, an increase in vascular tortuosity and angioid lines. It is difficult to differentiate the etiology because similar retinal findings occur due to chelation therapy [15-18].

Disc hyperemia (12.5%) and an increase in cup-disc ratio (37.5%) are seen in thalassemic patients. Optic atrophy has been reported as a probability of 17.5%. A correlation between the cup-disc ratio and serum ferritin and hemoglobin levels has been reported in thalassemic patients [15-18]. While decreased a-wave amplitude was detected in electroretinograms of these patients, no pathology was found in the visual evoked potential (VEP) response [19].

Negi et al. [20] found that VEP values in children with thalassemia were not different from the control group. However, upon detailed examination of the patients, abnormalities were found in VEP examinations in patients with high serum ferritin levels. It has been reported that these patients may have subclinical optic sensory neuropathy. They reported that optic neuropathy seen in thalassemia patients should not always be considered as neurotoxicity to deferoxamine.

Ocular manifestations of desferrioxamine toxicity include RPE pigment changes, night blindness, centrochecal scotoma, peripheral visual field narrowing, optic disc edema, optic neuropathy and optic atrophy. Most of the ocular changes depend on the severity of thalassemia. To prevent ocular complications, it may be beneficial to lower serum iron and ferritin levels with iron-chelating agents [4, 21, 22].

The limitation of this study is that it cannot be determined whether ocular involvement is associated with the disease or iron chelating agents. The exact cause of the increases in total RNFL and GCL+ thickness in the thalassemic group cannot be distinguished. It is necessary

to measure the RNFL and GCL+ values of each patient, however, we can learn more about the patient's condition by examining glaucoma and Hood reports. It is also important to examine the GCL+ thickness (Retinal view) in the Hood reports of these patients and the

GCL+ Macula 6 Sector Grid thickness in the glaucoma report. In addition, RNFL and GCL+

probability views also facilitate diagnosis. Therefore, it is recommended that RNFL and GCL+ measurements should be performed periodically in patients with beta-thalassemia major for early diagnosis and treatment.

Conclusion

The main finding in our study is the positive correlation between choroidal thickness and ferritin levels. Increases in choroidal thickness in the thalassemic group may be secondary to

inflammation caused by increased ferritin levels. Keeping ferritin levels under control in patients with thalassemia is also important in terms of preventing ocular involvement.

Scientific Responsibility Statement

The authors declare that they are responsible for the article's scientific content including study design, data collection, analysis and interpretation, writing, some of the main line, or all of the preparation and scientific review of the contents and approval of the final version of the article.

Animal and human rights statement

All procedures performed in this study were in accordance with the ethical standards of the institutional and/or national research committee and with the 1964 Helsinki declaration and its later amendments or comparable ethical standards. No animal or human studies were carried out by the authors for this article.

Funding: *None*

Conflict of interest

None of the authors received any type of financial support that could be considered potential conflict of interest regarding the manuscript or its submission.

References

1. Galanello R, Origa R. Beta-thalassemia. Orphanet J Rare Dis. 2010; 5: 11.

2. Jafari R, Heydarian S, Karami H, Shektaei MM, Dailami KN, Amiri AA, et al. Ocular abnormalities in multi-transfused beta-thalassemia patients. Indian J Ophthalmol. 2015; 63(9): 710-5.

3. Barteselli G, Dell'arti L, Finger RP, Charbel Issa P, Marcon A, Vezzola D, et al.

The spectrum of ocular alterations in patients with beta-thalassemia syndromes suggests a pathology similar to pseudoxanthoma elasticum. Ophthalmology. 2014; 121(3): 709-18.
4. Liaska A, Petrou P, Georgakopoulos CD, Diamanti R, Papaconstantinou D, Kanakis MG, et al. β-Thalassemia and ocular implications: a systematic review. BMC Ophthalmol. 2016; 16: 102.
5. Heydarian S, Jafari R, Dailami KN, Hashemi H, Jafarzadehpour E, Heirani M, et al. Ocular abnormalities in beta thalassemia patients: prevalence, impact, and management strategies. Int Ophthalmol. 2020; 40: 511-27.
6. Uzun F, Karaca EE, Yerlikaya GY, Fındık H, Akın M. Retinal nerve fiber layer thickness in children with beta-thalassemia major. Saudi J Ophthalmol. 2017; 31: 224-8.
7. Acer S, Balcı YI, Pekel G, Ongun TT, Polat A, Çetin EN, et al. Retinal nerve fiber layer thickness and retinal vessel calibers in children with thalassemia minor retinal nerve fiber layer thickness and retinal vessel calibers in children with thalassemia minor. SAGE Open Med. 2016; 4: 1-5.
8. Hood DC, De Cuir N, Blumberg DM, Liebmann JM, Jarukasetphon R, Ritch R, et al. A single wide-field OCT protocol can provide compelling information for the diagnosis of early glaucoma. Trans Vis Sci Tech. 2016; 5: 1-15.
9. Kardon R. The role of the macula OCT scan in neuro-ophthalmology. J Neuroophthalmol. 2011; 31(4): 353-61.
10. Ulusoy MO, Turk H, Kıvanç SA. Spectral domain optical coherence tomography findings in Turkish sickle-cell disease and beta thalassemia major patients. J Curr Ophthalmol. 2019; 31(3): 275-80.
11. Aksoy A, Aslan L, Aslankurt M, Eser O, Garipardic M, Okumus S, et al. Retinal fiber layer thickness in children with thalassemia major and iron deficiency anemia. Semin Ophthalmol. 2014; 29(1): 22-6.
12. El-Shazly AAEF, Elkitkat RS, Ebeid WM, Deghedy MR. Correlation between subfoveal choroidal thickness and foveal thickness in thalassemic patients. Retina. 2016; 36: 1767-72.
13. Atifoglu HB, Kucuk B, Duru N, Altunel O, Gulhan A, Ozen M, et al. Assessing posterior ocular structures in β-thalassemia minor. Int Ophthalmol. 2018; 38: 119-25.
14. Reinera A, Fitzgeralda MEC, Del Mar N, Chunyan L. Neural control of choroidal blood flow. Prog Retin Eye Res. 2018; 64: 96-130.
15. Abdel-Malak DSM, Dabbous OAE, Saif MYS, Saif ATS. Ocular manifestations in children with β thalassemia major and visual toxicity of iron chelating agents. J Am Sci. 2012; 8: 633-7.
16. Kumble D, Sekhon PK, Devi CG. Ocular involvement in beta thalassemia major: a prospective study in an Indian cohort. Int J Contemp Pediatr. 2017; 4: 780-2.
17. Saifa AT, Saif PS, Dabous O. Fundus changes in thalassemia in Egyptian patients. Delta J Ophthalmol. 2017; 18: 20-5.
18. Bhoiwala DL, Dunaief JL. Retinal abnormalities in β-thalassemia major. Surv Ophthalmol. 2016; 61(1): 33-50.
19. Dettoraki M, Kattamis A, Ladas I, Maragkos K. Electrophysiological assessment for early detection of retinal dysfunction in β-thalassemia major patients. Graefes Arch Clin Exp Ophthalmol. 2017; 255(7):1349-58.
20. Negi B, Bhardwaj P, Sharma S, Sharma M, Thakur P. Visual evoked potential in children with thalassemia. Int J Res Rev. 2020; 7: 439-42.
21. Lakhanpal V, Schocket SS, Jiji R. Deferoxamine (Desferal)-induced toxic retinal pigmentary degeneration and presumed optic neuropathy. Ophthalmology. 1984; 91(5): 443-51.
22. Di Nicola M, Barteselli G, Dell'Arti L, Ratiglia R, Viola F. Functional and structural abnormalities in deferoxamine retinopathy: A review of the literature. Biomed Res Int. 2015; 2015: 24961.

How to cite this article:
Cenk Zeki Fikret, Filiz Yildirim, Nil Irem Ucgun, Ozlem Evren Kemer. *Optical coherence tomography findings in patients with beta thalassemia major. Ann Clin Anal Med 2022; DOI: 10.4328/ACAM.21028*