Annals of Clinical and Analytical Medicine
Original Research

Ganglion cell complex thickness and optical coherence tomography findings in stargardt macular dystrophy and retinitis pigmentosa

Ocular findings in Stargardt macular dystrophy and retinitis pigmentosa

Eşay Kıran Yenice[1], Ahmet Şengün[2]
[1] Department of Ophthalmology, University of Health Sciences, Etlik Zübeyde Hanım Maternity and Women's Health Teaching and Research Hospital
[2] Department of Ophthalmology, Faculty of Medicine, Ufuk University, Dr Rıdvan Ege Hospital, Ankara, Turkey

Abstract
Aim: In this study, we aimed to assess ganglion cell complex (GCC) thickness with spectral domain optical coherence tomography (SD-OCT) and to detect changes in retinal layers in eyes with Stargardt macular dystrophy (SMD) and retinitis pigmentosa (RP) patients.
Material and Methods: Fifty-four eyes of 27 patients with RP and 46 eyes of 23 patients with SMD were enrolled. Each subject underwent a complete ophthalmic examination before SD-OCT was obtained. Macular scans were taken with software version 6.0 of the ganglion cell analysis (GCA) algorithm. Patients were divided into 3 grades according to photoreceptor layer integrity. GCC thickness was evaluated automatically as the average, minimum and six sectors by SD-OCT, and parameters were compared between groups.
Result: The mean age was 41.66±19. 77 years in group 1 (RP patients), and 28.00±10.37 years in group 2 (SMD patients). There were no significant differences in mean age, gender distribution, intraocular pressure and spherical equivalent at imaging between the groups ($p>0.05$). The mean (±SD) GCC thicknesses were evaluated and there were no significant differences between the two groups in each segment (Mann-Whitney U, $p>0.05$), but there were significant differences between patients in each grade (Kruskal-Wallis, $p<0.05$).
Discussion: This study showed that progressive degeneration and loss of function in the outer retinal layers are accompanied by damage to the inner retinal layers in patients with RP and SMD. However, some of the ganglion cells are protected after photoreceptor cell death, which may point us to the target tissue for future treatment modalities.

Keywords
Ganglion Cell Complex, Optical Coherence Tomography, Stargardt Macular Dystrophy, Retinitis Pigmentosa, Hereditary Retinal Dystrophy

DOI: 10.4328/ACAM.21048 Received: 2022-01-10 Accepted: 2022-02-11 Published Online: 2022-02-19
Corresponding Author: Eşay Kıran Yenice, University of Health Sciences, Etlik Zübeyde Hanım Maternity and Women's Health Teaching and Research Hospital, Varlık Mahallesi, Etlik Caddesi, No:55, Keçiören, Ankara, Turkey.
E-mail: esay_kiran@hotmail.com P: +90 312 567 40 00
Corresponding Author ORCID ID: https://orcid.org/0000-0002-7164-4837

Introduction

Hereditary retinal dystrophies (HRD) are genetic diseases that occur in childhood or adolescence and cause severe visual loss [1].

Photoreceptor cell damage, progressive degeneration and loss of function in retinal pigment epithelial cells (RPE) are observed in bilateral and symmetrical in HRD [2].

There are many genes responsible for the formation of retinal dystrophies: ABCA4, ELOVL41, PROML1, VMD2, peripherin/RDS, TIMP3 and XLRS. Mutations in these genes result in different clinical forms [3].

Various diagnostic methods such as visual field tests, electroretinography (ERG), electrooculography (EOG), fundus fluorescein angiography (FFA), OCT and genetic analysis tests are performed after detailed ophthalmic examination of the diseases [1].

The Cirrus OCT (Carl Zeiss Meditec, Inc., Dublin, CA), two-dimensional cross-sectional retinal images consisting of 512 A-lines with axial resolutions of 10 mm can be obtained in 1.28 s [4]. A-scans per second, pupil dilation is necessary for optimal measurement also GCC and other retinal layer thickness. The GCC thickness comprises the retinal ganglion cell layer (GCL) and inner plexiform layer (IPL), which are directly influenced by several potentially blinding eye diseases, such as glaucoma, retinitis pigmentosa [4].

The aim of this study was to assess GCC thickness in patients with RP and SMD and to investigate whether progressive degeneration and loss of function in the outer retinal layers are accompanied by damage to the inner retinal layers with retinal dystrophy.

Material and Methods

Participants and Patient Groups

This retrospective, comparative study was approved by the Ethical Review Committee of Ufuk University and adhered to the provisions of the Declaration of Helsinki for research involving human subjects. The medical records of 50 patients with SMD and RP were enrolled. Informed consent form was taken from all patients. Patients were divided into two groups; fifty-four eyes of 27 patients with RP group 1 and forty-six eyes of 23 patients with SMD group 2.

All eyes underwent full ophthalmic evaluation, including best-corrected visual acuity (BCVA) test, slit lamp examination and fundus examination. In all cases, the disease was diagnosed by examination findings and confirmed by ERG (to rule out other potential dystrophies). Cases with cataract and media opacity, which prevent SD-OCT image, retinal edema and serous detachment, pigmentary epithelial detachment in SD-OCT, glaucoma, spherical equivalent > 6D were excluded.

After detailed ophthalmic examination, macular scans were taken with SD-OCT (Cirrus; Carl Zeiss Meditec, Dublin, CA, USA). GCC thickness (GCL and IPL) was measured automatically as average (A), minimum (Min), temporal-superior (TS), superior (S), nasal-superior (NS), nasal-inferior (NI), inferior (I), temporal-inferior (TI) segments by SD-OCT, and results were compared between groups.

Also, patients were divided into 3 grades according to the study of Aizawa et al. [5]; patients with interruption in the photoreceptor layer grade 1, patients with abnormal photoreceptor layer grade 2 and patients with normal photoreceptor layer grade 3 and GCC thickness results were compared between 3 grades.

Spectral Domain Optical Coherence Tomography

The image was obtained using an SD-OCT device (Cirrus; Carl Zeiss Meditec). Macular scanning (macular cube 512x218) was performed through a dilated pupil with the SD-OCT. The GCC analysis algorithm was used to automatically measure the macular GCA thickness. Software version 6.0 of the GCA algorithm (Carl Zeiss Meditec) was used to process the data and detect and measure macular GCIPL thickness within a 6x6x2 mm cube centered on the fovea. The following macular GCIPL thickness measurements were analyzed: A, min, and sectorial (TS, S, NS, NI, I, TI) [6].

In SD-OCT technology, light from the reference arm interferes with light reflected back from the different layers of the retina, generating spectral interference fringes. This fringe pattern is processed by a high-speed spectrometer, and then undergoes transformation to create a reflectivity profile in depth. Two-dimensional cross-sectional retinal images consisting of 512 A-lines with axial resolutions of 10 mm can be obtained in 1.28 s. For GCC measurement scan was centered 1mm temporal to the fovea. It covers a 7x7 mm area of the central macula [6]. GCC thickness parameters indicate the retinal GCL and IPL in the area above the horizontal meridian. The software analyzes the values, compares them with the device's internal normative database, and generates a color-coded significance map. An instrument provided classification is indicated in a color-coded manner: sectors classified as "within normal limits" (p>5%) are printed in green, sectors classified as "borderline" (p<5% but >1%) in yellow, and sectors classified as "outside normal limits" (p<1%) in red.

Statistics

The SPSS 21.0 program package was used for statistical analysis. Normal distribution fitting was checked with the Kolmogorov-Smirnov test. The Mann-Whitney U-test was used to compare the measured GCL parameter values between groups, respectively. The Pearson x2 test was used to evaluate systemic disease between two groups. The Kruskal-Wallis test was used to compare the measured GCL parameter values between grades, respectively. P-values of 0.05 or lower were considered to indicate statistical significance.

Results

One hundred eyes of 50 participants were examined retrospectively. Fifteen of the 27 patients were men and 12 were women in group 1 and 9 of the 23 patients were men and 14 were women in group 2. The mean (±SD) age was 41.66±19.77 years in group 1 and 28.00±10.37 years in group 2. The mean (±SD) intraocular pressure (IOP) and BCVA of the participated eyes were 14.22±2.97 mmHg and 0.49±0.34 in group 1. The corresponding values in group 2 were 13.97±3.63 mmHg and 0.31±0.26, respectively. There was no significant difference between the groups for age, gender distribution, intraocular pressure and refraction (p>0.05). Demographic and ophthalmic examination data of the participants are shown in Table 1.

One of the 27 patients had hypertension, 1 of the 27 patients

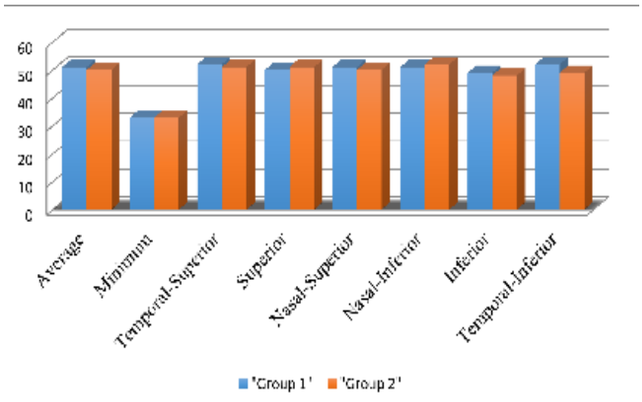

Figure 1. GCL+IPL thickness examination data of the participants

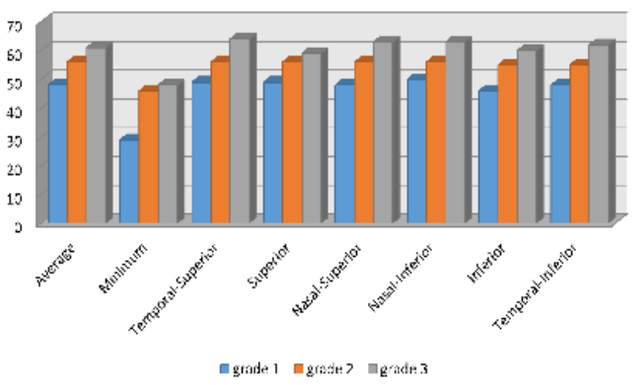

Figure 2. GCL+IPL thickness examination data in grade 1, 2, 3 patients

Table 1. Demographic and ophthalmic examination data of the participants

	Group 1	Group 2
Participants (n)	27	23
Sex (Male/Female)	15.12	9.14
Age, years (mean±SD)	41.66±19.77	28.00±10.37
Intraocular Pressure, mmHg (mean±SD)	14.22±2.97	13.97±3.63
BVCA (mean±SD)	0.49±0.34	0.31±0.26
Hypertension (%)	3,70%	4,30%
Diabetes Mellitus (%)	3,70%	4,30%
Hypertension and Diabetes Mellitus (%)	14,80%	0%

Table 2. GCL+IPL Thickness Examination Data of the participants.

Ganglion Cell Analysis Parameters (GCL+IPL) (µm, mean±SD)	Group 1 (n=27)	Group 2 (n=23)	p - Values
Average thickness	51.14±16.77	50.58±22.72	0,66*
Minimum thickness	33.00±19.89	33.54±25.25	0,54*
Temporal-superior thickness	52.85±19.16	51.28±23.88	0,68*
Superior thickness	50.18±18.75	51.06±23.34	0,70*
Nasal-superior thickness	51.94±21.37	50.45±24.47	0,67*
Nasal-inferior thickness	51.90±19.89	52.69±23.89	0,93*
Inferior thickness	49.35±16.34	48.28±22.97	0,49*
Temporal-inferior thickness	52.14±19.44	50.58±22.72	0,36*

Abbreviations: GCL, ganglion cell layer; IPL, inner plexiform layer. *Mann-Whitney U-test

had diabetes mellitus and 4 of the 27 patients had hypertension and diabetes mellitus together in group 1. On the other hand, 1 of the 23 patients had hypertension, 1 of the 23 patients had diabetes mellitus in group 2. There were no significant differences between systemic diseases and GCC thickness between the groups (Mann-Whitney U test, p>0.05).

GCC thickness was A 51.14±16.77µm, Min 33.00±19.89µm, TS 52.85±19.16µm, S 50.18±18.75µm, NS 51.94±21.37µm, NI 51.90±19.89µm, I 49.35±16.34µm and TI 52.14±19.44µm in group 1. The corresponding values in group 2 were 50.58±22.72µm, 33.54±25.25µm, 51.28±23.88µm, 51.06±23.34µm, 50.45±24.47µm, 52.69±23.89µm, 48.28±22.97µm and 49.36±25.82µm respectively. There were no significant differences between the two groups in each segment (Mann-Whitney U-test, p>0.05). The GCC thickness examination data of the groups are shown in Table 2, Figure 1.

On the other hand, when we evaluated the relationship between retinal layer integrity and GCC thickness, the average GCC thickness was 48.67±19.23µm, min 29.60±19.25µm, TS 49.47±21.27µm, S 49.07±20.40µm, NS 48.68±22.72µm, NI 50.28±21.80µm, I 46.34±18.80µm and TI 48.45±22.43µm in grade 1 patients.

GCC thickness was A 56.00±22.60µm, Min 46.66±26.81µm, TS 56.33±22.77µm, S 56.50±23.30µm, NS 56.83±22.86µm, NI 56.33±23.42µm, I 55.33±25.16µm and TI 55.16±23.97µm in grade 2 patients.

GCC thickness was A 61.86±21.17µm, Min 48.26±29.07µm, TS 64.23±21.38µm, S 56.76±23.36µm, NS 63.10±23.17µm, NI 63.13±22.66µm, I 60.13±20.99µm and TI 62.23±22.61µm in grade 3 patients.

There were significant differences between GCC thickness and grade 1, 2 and 3 patients (Kruskal-Wallis, p=0.015(A), p=0.007(Min), p=0.010(TS), p=0.028(S), p=0.021(NS), p=0.038(NI), p=0.012(I), p=0.015(TI)). GCC thickness values were highest in grade 3 patients.

At the same time, visual acuity was highest in grade 3 patients. The GCC thickness examination data in grade 1, 2, 3 patients are shown in Figure 2.

Discussion

Hereditary retinal dystrophy, one of the most common causes of genetic blindness, was first described by Donders at the beginning of the 1855s. It is possible to classify these group diseases according to genetic mutation or inheritance pattern, or to classify according to the anatomical localization of the primary lesion [7].

Retinal ganglion cells allow visual information produced by photoreceptor cells to be transmitted to the brain. Retinal ganglion cells are composed of 3 layers; retinal nerve fiber layer (RNFL), GCL and inner plexiform layer (IPL). These three layers are called GCC [6]. GCC is affected by multiple diseases such as glaucoma and macular degeneration, which cause structural changes in retina and choroid [8].

In some studies comparing age-related macular degeneration (AMD) and RP, it has been shown that although the clinical findings of the patients concern the outer retinal layers, there are functional and structural changes in the inner retinal layers in the later stages of the disease [9], and on the other hand, the

GCL is preserved in 50-75% of the eyes, and there is a positive correlation between the loss of ganglion cell neurons and the level of photoreceptors [10,11].

In some studies on human and animal eyes with retinal degeneration, it has been reported that the progression of the disease and decreased visual acuity lead to intraretinal and photoreceptor layer abnormalities [12-14], and loss of RGC was secondary to dystrophy [15].

Santos et al. analyzed macular sections of 21 eyes with RP and age-matched 19 healthy individuals histopathologically. Compared with the control group, there was a significant reduction in photoreceptor cell count in RP group. However, 30% of the GCL was preserved in the severe RP group. The results support that current treatment modalities such as retinal transplantation and retinal implantation in RP patients require ganglion cells preserved after photoreceptor cell death [16].

Similarly, in another study by Stone et al., eyes with RP and healthy individuals were compared and degeneration in ganglion cells secondary to photoreceptor cell death was analyzed by evaluating macular sections. Photoreceptor cell count was significantly lower in RP group, and transneuronal ganglion cell degeneration was observed. This study supports the hypothesis that current treatment methods, including stimulation and transplantation of photoreceptors aimed to increase visual acuity require ganglion cells [17].

In our study, there was no difference between the RP and SMD patient groups in terms of GCC thickness, but we found that the GCC thickness was higher in grade 3 patients where the photoreceptor layer integrity was not affected, but it was lower in grade 1 patients. At the same time, visual acuity was the highest in grade 3 patients.

In some studies, GCC thickness maps were obtained from OCT images of glaucomatous patients, and GCC thickness has been found to be affected in this group of patients [18].

In our study, there was no significant difference between IOP and GCC thickness.

Histopathological studies and HD-OCT studies in healthy subjects showed a linear relationship between increased age and thinning in GCT [19-21].

In our study, there was no significant difference between GCT+IPL-A, GCT+IPL-min and six sectors and age.

In systemic diseases such as hypertension and diabetes mellitus, morphological changes are seen in RGC and may result in visual loss accompanying retinopathy development. Tham et al. found that GCC is thinner in eyes with hypertensive retinopathy [22]. It is thought that the increase of retinal venous tortuosity disrupts tissue perfusion and causes degenerative changes in ganglion cells.

In our study, there was no significant difference between hypertensive and diabetes mellitus and GCC thickness.

In HRD, in which ganglion cell damage occurs after photoreceptor cell death, it is aimed to increase the level of vision with current treatment methods such as retinal prostheses [23].

It is known that retinal prostheses were developed to increase visualization of the inner retinal layers in patients with visual loss. For this purpose, there are multiple prosthetic systems and their working mechanisms. It is possible to increase visual acuity, detect different light patterns, localize objects, localize door-window, distinguish light and dark clothes and walk easily in pedestrian crossings in patients who have prosthetics [2,24]. We know that current treatment methods require the presence of the GCL. Although there are animal studies on this subject, the lack of adequate human studies limits the applicability of these treatments to humans. In the future, large studies are needed to investigate the effect of HRD on the ganglion cell layer.

Conclusion

This study showed that progressive degeneration and loss of function in the outer retinal layers are accompanied by damage to the inner retinal layers in patients with RP and SMD. However, some of the ganglion cells are protected after photoreceptor cell death, which may point us to the target tissue for future treatment modalities.

Scientific Responsibility Statement

The authors declare that they are responsible for the article's scientific content including study design, data collection, analysis and interpretation, writing, some of the main line, or all of the preparation and scientific review of the contents and approval of the final version of the article.

Animal and human rights statement

All procedures performed in this study were in accordance with the ethical standards of the institutional and/or national research committee and with the 1964 Helsinki declaration and its later amendments or comparable ethical standards. No animal or human studies were carried out by the authors for this article.

Funding: *None*

Conflict of interest

None of the authors received any type of financial support that could be considered potential conflict of interest regarding the manuscript or its submission.

References

1. Hamel CP. Cone rod dystrophies. Orphanet J Rare Dis. 2007; 2:7.

2. Ziccardi L, Cordeddu V, Gaddini L, Matteucci A, Parravano M, Malchiodi-Albedi F, et al. Gene therapy in retinal dystrophies. Int J Mol Sci. 2019; 20 (22): 5722

3. Sheremet NL, Strelnikov VV. Clinical and genetic aspects of ABCA4-associated inherited retinal diseases. Vestn Oftalmol. 2021; 137: 367-74.

4. Muftuoglu IK, Ramkumar HL, Bartsch DU, Meshi A, Gaber R, Freeman WR. Quantitative analysis of the inner retinal layer thickness in age-related macular degeneration using corrected optical coherence tomography segmentation. Retina. 2018; 38(8): 1478-84.

5. Aizawa S, Mitamura Y, Baba T, Hagiwara A, Ogata K, Yamamoto S. Correlation between visual function and photoreceptor inner/outer segment junction in patients with retinitis pigmentosa. Eye. 2009; 23(2): 304–8.

6. Cifuentes-Canorea P, Ruiz-Medrano J, Gutierrez-Bonet R, Pena-Garcia P, Saenz-Frances F, Garcia-Feijoo J, et al. Analysis of inner and outher retinal layers using spectral domain optical coherence tomography automated segmentation software in ocular hypertensive and glaucoma patients. PLoS One. 2018; 13(4). DOI: 10.1371/journal.pone.0196112

7. Inglehearn C. Molecular genetics of human retinal dystrophies. Eye. 1998; 12: 571-79.

8. Rimayanti U, Kiuchi Y, Yamane K, Latief MA, Mochizuki H, Hirata J, et al. Inner retinal layer comparisons of eyes with exudative age-related macular degeneration and eyes with age-related macular degeneration and glaucoma. Grafes Arch Clin Exp Ophthalmol. 2014; 252(4): 563-70.

9. Sustar M, Perovsek D, Cima I, Stirn-Kranjc B, Hawlina M, Brecelj J. Electroretinography and optical coherence tomography reveal abnormal post-photoreceptoral activity and altered retinal lamination patients with enhanced S-cone syndrome. Doc Ophthalmol. 2015; 130(3): 165-77.

10. Kim YK, Ha A, Na KI, Kim HJ, Jeoung JW, Park KH. Temporal relation between macular ganglion cell-inner plexiform layer loss and peripapillary retinal nerve fiber layer loss in glaucoma. Ophthalmology. 2017; 124(7): 1056-64.

11. Chua J, Tan B, Ke M, Schwarzhans F, Vass C, Wong D, et al. Diagnostic Ability of individual macular layers by spectral-domain oct in different stages of glaucoma. Ophthalmol Glaucoma. 2020; 3(5): 314-26.

12. Ryals RC, Andrews MD, Datta S, Coyner AS, Fischer CM, Wen Y, et al. Long-term characterization of retinal degeneration in Royal Collage of Surgeons rats using spectral-domain optical coherence tomography. Invest Ophthalmol Vis Sci. 2017; 58(3): 1378-86.

13. Nakamura N, Tsunoda K, Mizuno Y, Usui T, HataseT, Ueno S, et al. Clinical stages of occult macular dystrophy based on optical coherence tomographic findings. Invest Ophthalmol Vis Sci. 2019; 60(14): 4691-700.

14. Cho CS, Woo SJ, Park KH, Hwang JM. Morphologic Characteristics of the Outer

Retina in Cone Dystrophy on Spectral-domain Optical Coherence Tomography. Korean J Ophthalmol. 2013; 27 (1): 19-27.
15. García-Ayuso D, Salinas-Navarro M, Agudo M, Cuenca N, Pinilla I, Vidal-Sanz M, et al. Retinal ganglion cell numbers and delayed retinal ganglion cell death in the P23H rat retina. Exp Eye Res. 2010; 91(6): 800-10.
16. Santos A, Humayun MS, de Juan E Jr , Greenburg RJ, Marsh MJ, Klock IB, et al. Preservation of the inner retina in retinitis pigmentosa. A morphometric analysis. Arch Ophthalmol. 1997; 115 (4): 511-15.
17. Stone JL, Barlow WE, Humayun MS, Juan Jr E, Milam AH. Morphometric Analysis of macular photoreceptors and ganglion cells in retinas with retinitis pigmentosa. Arch Ophthalmol. 1992; 110 (11): 1634-9.
18. Zhang X, Dastiridou A, Francis BA, Tan O, Varma R, Greenfield DS, et al. Advanced imaging for glaucoma study group. Comparison of glaucoma progression detection by optical coherence tomography and visual field. Am J Ophthalmol. 2017; 184: 63-74.
19. Cavallotti C, Artico M, Pescosolido N, Leali FM, Feher J. Age-related changes in the human retina. Can J Ophthalmol. 2004; 39 (1): 61-8.
20. Koh VT, Tham YC, Cheung CY, Wong WL, Baskaran M, Saw SM, et al. Determinants of ganglion cell-inner plexiform layer thickness measured by high-definition optical coherence tomography. Invest Ophthalmol Vis. Sci. 2012; 53(9): 5853-9.
21. Harman A, Abrahams B, Moore S, Hoskins R. Neuronal Density in the human retinal ganglion cell layer from 16–77 Years. Anat Rec. 2000; 260 (2): 124-31.
22. Tham YC, Cheng CY, Zheng Y, Aung T, Wong TY, Cheung CY. Relationship between retinal vascular geometry with retinal nerve fiber layer and ganglion cell-inner plexiform layer in nonglaucomatous eyes. Invest Ophthalmol Vis. Sci. 2013; 54 (12): 7309-16.
23. Özmert E, Arslan U. Retinal Prostheses and Artificial Vision. Turk J Ophthalmol. 2019; 49 (4): 213-19.
24. Kootchar A, Hong J, Stewart D, Cruz L. The Argus II prosthesis facilitates reaching and grasping tasks: a case series. BMC Ophthalmology. 2014; 14: 71.

How to cite this article:
Eşay Kıran Yenice, Ahmet Şengün. *Ganglion cell complex thickness and optical coherence tomography findings in stargardt macular dystrophy and retinitis pigmentosa. Ann Clin Anal Med 2022; DOI: 10.4328/ACAM.21048*