Annals of Clinical and Analytical Medicine
Original Research

Optic nerve sheath diameter measured by point-of-care ocular ultrasound in glaucoma patients

Turgay Yılmaz Kılıc[1], Yeşim Eyler[1], Bediz Ozen[2], Berna Yuce[2], Murat Yesılaras[1], Ozge Duman Atılla[1]
[1] Department of Emergency Medicine
[2] Department of Ophthalmology, University of Health Sciences, Tepecik Training and Research Hospital, Izmir, Turkey

Abstract
Aim: In this study, we aimed to investigate the relationship of optic nerve sheath diameters measured by point-of-care ocular ultrasound between glaucoma patients with normal or high intraocular pressure and control subjects.
Material and Methods: All patients underwent a detailed ophthalmic examination for intraocular pressure measurement, anterior segment examination, and fundus examination. Optic nerve sheath diameter measurements with point-of-care ocular ultrasound were performed in B-mode with a linear probe. The ophthalmologists and emergency medicine attending physicians did not share any information about the examination findings and ultrasonographic measurements.
Results: Ninety-four glaucoma patients and 21 control subjects were included in the study. Optic nerve sheath diameters of glaucoma patients and control subjects were 4.2 mm (IQR=1.3) versus 4.3 mm (IQR=0.9) for the right eye (p=0.617), and 4.3 mm (IQR=1.1) versus 4.2 mm (IQR=1) for the left eye (p=0.728). Optic nerve sheath diameters of patients with high and those with normal intraocular pressure were 4.1mm (IQR=1.1) versus 4.2 mm (IQR=1.4) for the right eye (p=0.911), and 4.4 mm (IQR=1.4) versus 4.3 mm (IQR=1.2) for the left eye (p=0.221).
Discussion: Recent studies have reported that intracranial pressure may be effective in glaucomatous optic neuropathy. Ultrasonographic measurements of optic nerve sheath diameter for detecting elevated intracranial pressure were similar in patients with glaucoma and control subjects.

Keywords
Glaucoma, Intracranial Pressure, Optic Nerve Sheath Diameter, Ultrasound

DOI: 10.4328/ACAM.21058 Received: 2022-01-18 Accepted: 2022-02-21 Published Online: 2022-02-22
Corresponding Author: Turgay Yılmaz Kilic, Department of Emergency Medicine, University of Health Sciences, Tepecik Training and Research Hospital, Gaziler Caddesi, Yenisehir, 35120, Izmir, Turkey.
E-mail: turgayyilmaz.kilic@gmail.com P: +90 232 469 69 69 F: +90 232 459 47 88
Corresponding Author ORCID ID: https://orcid.org/0000-0002-3494-5120

Introduction

Glaucoma is a multifactorial, chronic, and progressive optic neuropathy that can cause permanent blindness [1,2]. Although high intraocular pressure (IOP) plays an important role in the development and progression of glaucoma, the mechanisms of damage to the optic nerve are not fully known.

Since the optic nerve is surrounded by cerebrospinal fluid in the subarachnoid space, it is exposed not only to IOP but also to intracranial pressure (ICP). The authors reported different opinions on the role of ICP in glaucoma patients. While some of the studies have shown that ICP is lower in glaucoma patients than in healthy individuals, other studies have reported no difference in ICP in patients with and without glaucoma [3-8].

Ultrasonographic measurement of optic nerve sheath diameter (ONSD) is a rapid and non-invasive method for detecting elevated ICP in acute settings [9-11]. In this study, we aimed to investigate the relationship of ONSDs measured by point-of-care ocular ultrasound (PoCOUS) between glaucoma patients with normal (<20 mm Hg) or high (20 mm Hg) IOP and control subjects.

Material and Methods

This prospective, cross-sectional study was conducted between November 2018 and June 2019 in a tertiary urban training and research hospital. Ethical approval was obtained prior to the study (2018/7-15). Patient consent was obtained to participate in the study.

Study Setting and Population

Patients were included in the study by convenience sampling method. Patients aged 18 years and older who were admitted to the ophthalmology clinic and underwent a detailed ophthalmological examination by two ophthalmologists, experienced in glaucoma, were included in the study.

Patients with chronic steroid use, a diagnosis of pseudotumor cerebri, intracranial mass, major head trauma, a history of traumatic brain injury, and a history of cranial surgery, those younger than 18 years old and those who did not agree to participate in the study were excluded from the study. Patients with a history of previous eye surgery, neurological disease, eye trauma, any anterior or posterior segment disease other than glaucoma, patients with optically significant cataracts, > +3 dioptric or <-5 dioptricity refractive errors, patients whose IOP could not be measured and patients whose ONSD could not be measured by PoCOUS for any reason were also excluded from the study.

The control group was selected from those who admitted to the ophthalmology clinic, had no known family history of glaucoma, and had no eye surgery, including cataracts. There were no pathological findings in the ophthalmological examinations of the control group. In this study, ONSD was measured by PoCOUS in glaucoma patients and control subjects.

Ophthalmic Examination

All patients (glaucoma patients and conrol subjects) underwent a detailed ophthalmic examination by two ophthalmologists (BY, BO) experienced in glaucoma. Intraocular pressure measurements were performed with Goldmann applanation tonometer, anterior segment examination was performed with a slit-lamp biomicroscope (Topcon; Tokyo, Japan), and fundus examination was performed with a 90 diopter lens. Intraocular pressure value of 20 mm Hg and above was considered high. Central corneal thickness (CCT) was measured using Topcon (Topcon CT-1P; Tokyo, Japan) automatic optical pachymetry. In order to avoid the diurnal variation effect, measurements were made between 9:00 and 11:00 a.m. and the median value of 3 measurements was taken. Central retinal nerve fiber layer (RNFL) thickness was measured with Spectralis optical coherence tomography (Heidelberg Spectralis; Heidelberg, Germany). Patients with previously defined characteristic optic nerve changes and visual field loss were considered glaucoma [12].

Ultrasonographic ONSD Measurement

Sonographic measurements of the ONSD were carried out by one of the two EM attending physicians (TYK, YE). Emergency medicine attending physicians participating in the study were experienced in ultrasonography and received a 4-hour theoretical and practical training on ocular ultrasonography before the study. These EM doctors also performed measurements of ONSD. To improve the competency of the sonographers, each sonographer performed ONSD measurement in predefined test patients (in 25 cases).

The sonographer who carried out the ultrasonographic measurement was blind to the diagnosis and examination of the patient. Each sonographer recorded their results on independent data collection forms and did not know each other's measurements. Before the ultrasonographic measurement, all patients were informed about the procedure and their written and verbal consents were obtained.

Optic nerve sheath diameter measurements with PoCOUS were performed in B-mode with a 10 MHz linear probe (Mindray M5; Mindray, Shenzhen, China). The measurements were made in the transverse plane, and the settings were adjusted to allow optimal visualization (frequency=7.5-10 MHz; depth=4-5 cm). With the patient supine (head of bed 0°), and the eyes closed and in the neutral position (the patients were asked to keep their eyes as steady as possible throughout the procedure), an ultrasound gel was applied on the eyelid and ultrasound imaging was performed without applying pressure on the eye. After imaging of the optic nerve sheath, 3 mm behind the optic disc was marked and ONSD measurement was carried out from the marked area (Figure 1).

The ophthalmologists and EM attending physicians did not share any information about the examination findings and ultrasonographic measurements. The first part of the patient data form (ophthalmic examination) was filled out by ophthalmologists and the second part (ONSD measurement) by the EM attending physicians. After the decision to terminate the study, all measurements were collected in a database and analyzed.

Statistical Analysis

All statistical analyses were performed by two authors (MY, ODA) using Statistical Package for the Social Sciences version 24.0. Qualitative data were expressed as number of observations and percentages (%). Quantitative data were expressed as medians (minimum-maximum) and interquartile range (IQR). The Fisher's Exact test was used for the analysis of qualitative data, and the Mann-Whitney U test was used for

the comparison of continuous variables. All statistical analyses were performed at a 95% confidence interval. A p-value less than 0.05 was considered statistically significant.

Results

Ninety-four glaucoma patients and 21 control subjects were included in the study (Figure 2).

The median age of glaucoma patients and the control group

Table 1. Intraocular pressure, ultrasonographic optic nerve sheath diameter measurements and ophthalmic examination of glaucoma patients and control group.

		Glaucoma Patients (n=94)	Control Group (n=21)	p
ONSD (mm)	Right eye	4.2 (IQR=1.3)	4.3 (IQR=0.9)	0.617
	Left eye	4.3 (IQR=1.1)	4.2 (IQR=1)	0.728
IOP (mm Hg)	Right eye	16 (IQR=4)	14 (IQR=4)	0.539
	Left eye	16 (IQR=4.3)	15 (IQR=2.5)	0.340
AL (mm)	Right eye	23.31 (IQR=1.22)	23.18 (IQR=0.46)	0.271
	Left eye	23.28 (IQR=1.23)	23.11 (IQR=0.56)	0.362
CCT (µm)	Right eye	531.5 (IQR=44)	541 (IQR=38)	0.112
	Left eye	532 (IQR=45)	550 (IQR=33)	0.168
ACD (mm)	Right eye	3.1 (IQR=0.5)	3.2 (IQR=0.4)	0.536
	Left eye	3.1 (IQR=0.5)	3.2 (IQR=0.4)	0.417
RNFL thickness (µm)	Right eye	86 (IQR=23)	104 (IQR=4)	0.000
	Left eye	86.5 (IQR=26)	101 (IQR=5)	0.000
VA	Right eye	0.7 (IQR=0.3)	0.9 (IQR=0.1)	0.000
	Left eye	0.7 (IQR=0.3)	0.9 (IQR=0.1)	0.000
C/D	Right eye	0.5 (IQR=0.3)	0.1 (IQR=0.1)	0.000
	Left eye	0.5 (IQR=0.4)	0.2 (IQR=0.1)	0.000

ONSD: Optic nerve sheath diameter; IOP: Intraocular pressure; AL: Axial length; CCT: Central corneal thickness; ACD: Anterior chamber depth; RNFL: Retinal nerve fiber layer thickness; VA: Visual acuity; C/D: Cup-to-disc ratio; IQR: Interquartile range

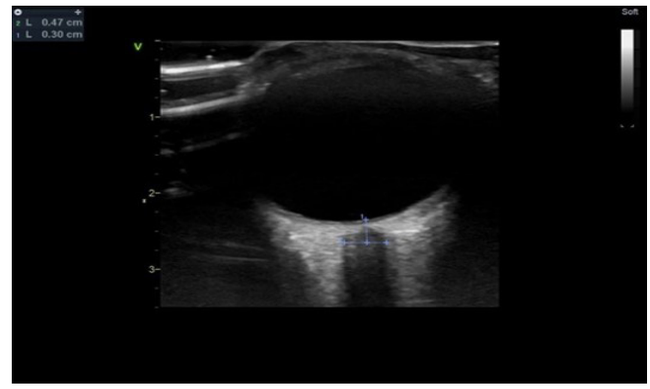

Figure 1. Measurement of optic nerve sheath diameter by ultrasound.

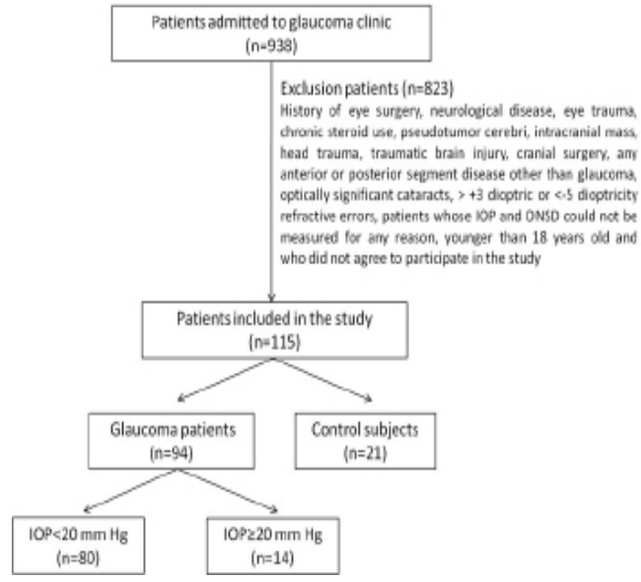

Figure 2. Flow diagram of participants in the study.

Table 2. The data of glaucoma patients with high (≥20 mm Hg) and those with normal intraocular pressure (<20 mm Hg) for the right and left eyes.

Right eye	IOP<20 mm Hg (n=80)	IOP≥20 mm Hg (n=14)	p
ONSD (mm)	4.2 (IQR=1.4)	4.1 (IQR=1.1)	0.911
AL (mm)	23.29 (IQR=1.18)	23.53 (IQR=1.58)	0.566
CCT (µm)	530.5 (IQR=42)	564 (IQR=55)	0.011
ACD (mm)	3.1 (IQR=0.5)	3.4 (IQR=0.5)	0.068
RNFL thickness (µm)	84.5 (IQR=23)	90.5 (IQR=22)	0.216
VA	0.7 (IQR=0.3)	0.65 (IQR=0.3)	0.927
C/D	0.5 (IQR=0.2)	0.4 (IQR=0.4)	0.448
Left eye	**IOB<20 mm Hg (n=81)**	**IOB≥20 mm Hg (n=13)**	**p**
ONSD (mm)	4.3 (IQR=1.2)	4.4 (IQR=1.4)	0.221
AL (mm)	23.16 (IQR=1.18)	24.01 (IQR=1.74)	0.067
CCT (µm)	530 (IQR=43)	561 (IQR=57)	0.014
ACD (mm)	3.1 (IQR=0.5)	3.3 (IQR=0.6)	0.105
RNFL thickness (µm)	87 (IQR=28)	86 (IQR=20)	0.622
VA	0.7 (IQR=0.3)	0.7 (IQR=0.3)	0.346
C/D	0.5 (IQR=0.4)	0.3 (IQR=0.4)	0.189

ONSD: Optic nerve sheath diameter; IOP: Intraocular pressure; AL: Axial length; CCT: Central corneal thickness; ACD: Anterior chamber depth; RNFL: Retinal nerve fiber layer thickness; VA: Visual acuity; C/D: Cup-to-disc ratio; IQR: Interquartile range

Table 3. Comparison of the median optic nerve sheath diameter measurement values and ophthalmic examination data for the right and left eyes.

Right eye	ONSD<5 mm (n=90)	ONSD ≥5 mm (n=25)	p
IOP (mm Hg)	16 (IQR=4)	16 (IQR=4)	0.837
AL (mm)	23.28 (IQR=1)	23.18 (IQR=0.9)	0.938
CCT (µm)	532 (IQR=42)	540 (IQR=51)	0.879
ACD (mm)	3.1 (IQR=0.5)	3.1 (IQR=0.6)	0.530
RNFL thickness (µm)	91 (IQR=22)	94 (IQR=27)	0.640
VA	0.7 (IQR=0.4)	0.8 (IQR=0.3)	0.101
C/D	0.4 (IQR=0.3)	0.4 (IQR=0.2)	0.627
Left eye	**ONSD<5 mm (n=96)**	**ONSD≥5 mm (n=19)**	**p**
IOP (mm Hg)	15 (IQR=3)	18 (IQR=3)	0.004
AL (mm)	23.22 (IQR=1.1)	23.15 (IQR=0.87)	0.786
CCT (µm)	534 (IQR=42)	543 (IQR=71)	0.743
ACD (mm)	3.1 (IQR=0.5)	3.1 (IQR=0.4)	0.862
RNFL thickness (µm)	93 (IQR=19)	89 (IQR=43)	0.192
VA	0.7 (IQR=0.3)	0.7 (IQR=0.5)	0.707
C/D	0.4 (IQR=0.3)	0.5 (IQR=0.4)	0.032

ONSD: Optic nerve sheath diameter; IOP: Intraocular pressure; AL: Axial length; CCT: Central corneal thickness; ACD: Anterior chamber depth; RNFL: Retinal nerve fiber layer thickness; VA: Visual acuity; C/D: Cup-to-disc ratio; IQR: Interquartile range

was 64 years (IQR=13 years; range=43–86 years) and 62 years (IQR=12 years; range=49–76 years), respectively (p=0.635). Fifty-four (57.4%) of the glaucoma patients and 13 (61.9%) of the control group were women. Intraocular pressure, ultrasonographic ONSD measurements and ophthalmic examination of glaucoma patients and control group are shown in Table 1. The data of glaucoma patients with high (≥20 mm Hg) and those with normal IOP (<20 mm Hg) are presented in Table 2. A comparison of ONSD and ophthalmic examination data is shown in Table 3.

Discussion

In this study, we investigated the relationship between ONSDs measured by PoCOUS in glaucoma patients with normal (<20 mm Hg) or high (≥20 mm Hg) IOP. However, we did not find a significant difference between ONSDs measured by ultrasonography in glaucoma patients with normal or high IOP. Also, there was no statistically significant difference in measured ONSDs between glaucoma patients and control subjects.

Although glaucoma is the second leading cause of blindness globally, its pathogenesis is not fully understood. However, high IOP is still considered to be the most important risk factor for glaucoma. Normally, IOP is between 10 to 20 mm Hg. The increase in IOP (> 20 mm Hg) may cause damage by disrupting the perfusion of the optic nerve. Increased IOP causes glaucomatous damage by directly damaging the nerve fibers (mechanically) or by disrupting the microcirculation in the optic nerve head (ischemic), resulting in a decrease in optic nerve diameter. Although we found that IOP values in glaucoma patients were higher than in the control group, we did not find a statistically significant difference between the two groups. However, this result should not be interpreted as IOP does not contribute to the pathogenesis of glaucoma. The most likely reasons for this result may be that some of the patients receive glaucoma treatment, or the patients in the glaucoma group are normal tension glaucoma (NTG).

Although IOP is considered the main risk factor in glaucoma, authors have recently focused on the role of the ICP in glaucomatous optic neuropathy [13]. Invasive techniques including lumbar puncture, the insertion of external ventricular drains or intraparenchymal monitors represent the gold standard in measuring ICP. Especially when repeated evaluations are required, difficulties in application, the complications such as bleeding, infection and pain, and the presence of contraindications such as coagulopathy cause non-invasive methods to be preferred over invasive methods in the evaluation of ICP. However, non-invasive gold standard ICP measurement techniques are not currently available. These non-invasive measurement techniques are based on the correlation between ICP values and physiological biomarkers. In recent years, ultrasonographic ONSD measurement has been the most studied option for screening measurements to detect elevated ICP [14]. Due to impaired autoregulation in glaucoma patients, fluctuations in ICP may affect ocular blood flow and cause damage to the optic nerve. In several studies, it has been reported that reduced ICP causes progression in glaucoma patients [3,5,13]. The authors noted that patients with NTG had lower ICP compared to primary open angle glaucoma (POAG) and healthy controls. However, Lindén et al. stated that ICP is normal in patients with NTG [6]. In this study, we did not find any difference in ultrasonographic ONSD measurements between glaucoma patients and control subjects. Although this result can be interpreted as no significant difference between the ICPs between the two groups, since the ultrasonographic ONSD measurement is known to be a sensitive indicator of ICP in acute settings, the time when measurements are made (acute vs chronic setting) should be considered. Therewithal, it should not be forgotten that effects of the drugs used by patients may also cause these results.

One of the most important factors in the evaluation of IOP is CCT [15]. However, CCT can be affected by many factors, including age, treatment and subtype of glaucoma. Intraocular pressure can be measured lower in thin corneas and higher in thicker corneas. Although CCT was found to be thinner in glaucoma patients compared to the control subjects in this study, there was no statistically significant difference.

The main limitations of our study are that the patients in the study group were not divided into subgroups (POAG, NTG), the low number of subjects in the control group, and the high number of exclusion patients. Statistical analysis was not performed between newly diagnosed glaucoma patients and patients with a known history of glaucoma. Another important limitation of our study is that ICP measurement is not performed in patients by any invasive method, such as lumbar puncture.

Conclusion

The ONSDs measured by ultrasonography in glaucoma patients and control subjects, and in glaucoma patients with normal or high IOP were similar to each other in this study. Although this result can be interpreted as no significant difference between the ICPs, the time when ONSD measurements are made (acute vs chronic setting) and the drugs used by the patients should be considered.

Acknowledgment
The authors thank the patients who participated in this study and their relatives.

Scientific Responsibility Statement
The authors declare that they are responsible for the article's scientific content including study design, data collection, analysis and interpretation, writing, some of the main line, or all of the preparation and scientific review of the contents and approval of the final version of the article.

Animal and human rights statement
All procedures performed in this study were in accordance with the ethical standards of the institutional and/or national research committee and with the 1964 Helsinki declaration and its later amendments or comparable ethical standards. No animal or human studies were carried out by the authors for this article.

Funding: *None*

Conflict of interest
None of the authors received any type of financial support that could be considered potential conflict of interest regarding the manuscript or its submission.

References
1. Fleischman D, Allingham RR. The role of cerebrospinal fluid pressure in glaucoma and other ophthalmic diseases: A review. Saudi J Ophthalmol. 2013;27(2):97-106.
2. Casson RJ, Chidlow G, Wood JPM, Crowston JG, Goldberg I. Definition of glaucoma: clinical and experimental concepts. Clin Experiment Ophthalmol. 2012;40(4):341–9.

3. Berdahl JP, Allingham RR, Johnson DH. Cerebrospinal fluid pressure is decreased in primary open angle glaucoma. Ophthalmology. 2008;115(5):763–8.
4. Berdahl JP, Fautsch MP, Stinnett SS, Allingham RR. Intracranial pressure in primary open angle glaucoma, normal tension glaucoma, and ocular hypertension: a case-control study. Invest Ophthalmol Vis Sci. 2008;49(12):5412–8.
5. Ren R, Jonas JB, Tian G, Zhen Y, Ma K, Li S, et al. Cerebrospinal fluid pressure in glaucoma: a prospective study. Ophthalmology. 2010;117(2):259–66.
6. Lindén C, Qvarlander S, Jóhannesson G, Johansson E, Östlund F, Malm J, et al. Normal-Tension Glaucoma Has Normal Intracranial Pressure: A Prospective Study of Intracranial Pressure and Intraocular Pressure in Different Body Positions. Ophthalmology. 2018;125(3):361–8.
7. Loiselle AR, de Kleine E, van Dijk P, Jansonius NM. Noninvasive intracranial pressure assessment using otoacoustic emissions: An application in glaucoma. PLoS One. 2018;13(10):e0204939.
8. Pircher A, Remonda L, Weinreb RN, Killer HE. Translaminar pressure in Caucasian normal tension glaucoma patients. Acta Ophthalmol. 2017;95(7):e524–31.
9. Hassen GW, Bruck I, Donahue J, Mason B, Sweeney B, Saabet W, et al. Accuracy of optic nerve sheath diameter measurement by emergency physicians using bedside ultrasound. J Emerg Med. 2015;48(4):450-7.
10. Komut E, Kozacı N, Sönmez BM, Yılmaz F, Komut S, Yıldırım ZN, et al. Bedside sonographic measurement of optic nerve sheath diameter as a predictor of intracranial pressure in ED. Am J Emerg Med. 2016;34(6):963-7.
11. Blaivas M, Theodoro D, Sierzenski PR. Elevated intracranial pressure detected by bedside emergency ultrasonography of the optic nerve sheath. Acad Emerg Med. 2003;10(4):376-81.
12. H D Jampel. Target pressure in glaucoma therapy. J Glaucoma. 1997;6(2):133-8.
13. Siaudvytyte L, Januleviciene I, Daveckaite A, Ragauskas A, Siesky B, Harris A. Neuroretinal rim area and ocular haemodynamic parameters in patients with normal-tension glaucoma with differing intracranial pressures. Br J Ophthalmol. 2016;100(8):1134-8.
14. Price DA, Grzybowski A, Eikenberry J, Januleviciene I, Vercellin ACV, Mathew S, et al. Review of non-invasive intracranial pressure measurement techniques for ophthalmology applications. Br J Ophthalmol. 2020;104(7):887-92.
15. Mansoori T, Balakrishna N. Effect of central corneal thickness on intraocular pressure and comparison of Topcon CT-80 non-contact tonometry with Goldmann applanation tonometry. Clin Exp Optom. 2018;101(2):206-12.

How to cite this article:
Turgay Yılmaz Kılıc, Yeşim Eyler, Bediz Ozen, Berna Yuce, Murat Yesılaras, Ozge Duman Atılla. Optic nerve sheath diameter measured by point-of-care ocular ultrasound in glaucoma patients. Ann Clin Anal Med 2022; DOI: 10.4328/ACAM.21058