Annals of Clinical and Analytical Medicine
Original Research

Inferior vena cava and pulmonary artery diameters for prognosis of Coronavirus disease

Pulmonary vascular diameters in Coronavirus disease

Mehmet Altuntaş[1], Mümin Murat Yazıcı[1], Ali Çelik[1], Kemal Panç[2], Nur Hürsoy[2]
[1] Department of Emergency Medicine
[2] Department of Radiology, Faculty of Medicine, Recep Tayyip Erdoğan University, Rize, Turkey

Abstract
Aim: In this study, we aimed to analyze the relationship between pulmonary artery (PA) and inferior vena cava (IVC) diameters in non-contrast chest computerized tomography (CT) images of patients with coronavirus disease 2019 (COVID-19) and overall survival.
Material and Methods: This retrospective study consisted of 404 consecutive patients who underwent chest CT after admission to the emergency department between May 1 and June 31, 2021. CT measurements were performed by two radiologists. The prognostic value of PA and IVC diameters, the computerized tomography severity score (CT-SS), quick sequential organ failure assessment (qSOFA), and confusion, urea, respiratory rate, blood pressure, and age ≥65 years (CURB-65) score on overall survival were examined.
Results: The median age of the participants was 62 years (49-72), and 196 (48.5%) were male. Of the 404 patients, 61 died after admission. While main-PA, left-PA, right-PA ($p < 0.001$) and IVC-transverse (IVC-Tr) ($p = 0.045$) diameters were larger and statistically significant in the patients who died (AUC; 0.686, 0.722, 0.746, and 0.581, respectively), a statistically significant difference was not detected in terms of IVC anteroposterior diameter (IVC-AP) ($p = 0.053$) and the IVC-Tr/AP ($p = 0.754$) ratio. There was a statistical difference in mortality in qSOFA, CURB-65, and CT-SS values (AUC; 0.727, 0.798, and 0.708 $p < 0.001$, respectively).
Discussion: PA diameters measured from chest CT images at admission (main-PA ≥ 26.5 mm, right-PA ≥ 22.9 mm, and left-PA ≥ 21.6 mm) and the IVC-Tr diameter (≥34.5 mm) can be used as mortality predictors for COVID-19, along with other prognostic scores.

Keywords
Emergency Department, COVID-19, Pulmonary Artery, Inferior Vena Cava, Prognosis

DOI: 10.4328/ACAM.21220 Received: 2022-05-05 Accepted: 2022-06-11 Published Online: 2022-06-22
Corresponding Author: Mehmet Altuntaş, Department of Emergency Medicine, Recep Tayyip Erdoğan University Training and Research Hospital, Rize, Turkey.
E-mail: mehmet.altuntas@erdogan.edu.tr P: +90 506 416 14 04
Corresponding Author ORCID ID: https://orcid.org/0000-0001-5624-968X

Introduction

COVID-19, which has affected millions of people and has become a global health problem, is characterized by a wide range of infectious symptoms ranging from mild to severe, including acute respiratory distress syndrome (ARDS) as its primary complication. Six to 20 percent of patients require hospitalization [1], and the mortality rate among hospitalized patients ranges from 11% to 28% [2,3].

Early and easy identification of patients who may have poor outcomes after hospital admission is important to optimize the use of resources. Various prognostic scores have been developed to determine the high risk of death in patients with community-acquired pneumonia. The pneumonia severity index; confusion, urea, respiratory rate, blood pressure, and age ≥65 years (CURB-65) score; and the quick sequential organ failure assessment (qSOFA) score are well verified as supporting the prognosis of pneumonia [4]. Many scores have proven to be useful tools for determining the prognosis in patients with suspected infection in the emergency department (ED), intensive care units, and at home [5-7]. It is well known that the severity of pulmonary parenchymal involvement in COVID-19 is also associated with a poor prognosis. Non-contrast chest computerized tomography (CT) is a useful tool for the initial evaluation of patients with suspected COVID-19 infection and offers high sensitivity for the diagnosis of the disease [8]. CT severity scores can help classify patient risk and predict short-term outcomes in patients with COVID-19 pneumonia [9, 10].

The pulmonary artery (PA) and the inferior vena cava (IVC) are venous systems that carry deoxygenated blood to the lungs. Reduction of pulmonary compliance in the presence of pneumonia results in severe hypoxemia and ARDS. It is assumed that long-term hypoxemia due to severe pneumonia may result in higher pulmonary vascular resistance and increased diameters in venous system vessels [11]. Widespread alveolar damage, PA thrombosis, and interstitial pneumonia with right ventricular (RV) expansion have been found in autopsies performed on COVID-19 patients [12]. In severe COVID-19 patients undergoing echocardiography, enlargement of the right-hand heart cavities, decreased RV function, and high PA systolic pressures have been identified [13]. While echocardiography is less preferred due to limited resources and technical and practical limitations related to the need to reduce the exposure of health workers to viral load, non-contrast chest CT is widely adopted for COVID-19 pneumonia diagnosis, monitoring, and prognosis [14]. Reference values for IVC and PA diameters, which can be easily measured with chest CT scans, have been determined for healthy people [15,16].

For these reasons, we assumed that PA and IVC diameters would be useful in classifying the risk of COVID-19 patients. We aimed to determine the prognostic estimation of severity scores and IVC and PA diameters in non-contrast chest CT images of COVID-19 patients.

Material and Methods

This was a single-centered, retrospective cohort study. Participants comprised of adult patients whose non-contrast chest CT images had been acquired after admission to the ED between May 1 and June 31, 2021, and were confirmed to have COVID-19 using a polymerase chain reaction test. The study was approved by the local ethics committee (no: 2022/326). Clinical data were demographic characteristics (gender and age), comorbidities (hypertension, diabetes, chronic lung disease, and cardiovascular disease), vital findings, tomography images, blood analysis results, and clinical outcome (survival or death) derived from the hospital information system and ED patient forms. Disease severity scores (i.e. CURB-65, qSOFA, and computerized tomography severity score [CT-SS]) and the diameters of venous system vessels (i.e. IVC and PA) were compared with patient outcomes. Incomplete data on follow-up was considered an exclusion criterion.

Chest CT Scan

All non-contrast chest CT scans were obtained using a 16-detector CT scanner (Toshiba Alexion™; Toshiba Medical Systems Corporation, Nashu, Japan). Measurements were made from 1-mm thick axial images using standard windows (i.e. lung: width 1400 HU, center 450 HU; mediastinum: width 350 HU, center 40 HU).

Chest CT Analysis

The measurements were made by two radiologists with experience in cardiothoracic imaging, who were blind to all clinical data to reduce possible analysis bias and increase the homogeneity and reliability of the data. In addition to identifying any lung involvement parameters (i.e. ground-glass opacities, consolidation, halo sign, inverted halo sign, and pleural effusion), IVC-Tr, IVC-AP, and PA diameter measurements were made. The main PA diameter was measured at its origin, proximal to the branching point. Left-PA and right-PA diameters were measured just after the main PA branching. These points are easy to identify anatomically, which makes them highly repeatable. IVC measurements were performed at the widest level before draining into the right atrium. The measurements are summarized in Figure 1.

The CT-SS was calculated for each of the two hemithoraces taking into account the scope of anatomical involvement as follows: 0 points, no involvement; 1 point, <5% involvement; 2 points, 5–25% involvement; 3 points, 26–50% involvement; 4 points, 51–75% involvement and 5 points, >%75 involvement. The resulting global CT-SS was determined as the sum of each hemithorax score. The presence of related properties, such as ground-glass opacity (GGO), fibrosis, consolidation, subpleural lines, halo sign, inverted halo sign, and pleural effusion, were also defined. The distribution of lung abnormalities was classified as mainly peripheral, central, or both peripheral and central.

Statistical Analyses

All statistical analyses were carried out using a statistics package program (Jamovi Project Computer Software, Version 1.6; Sydney, Australia). Continuous variables with normal distributions were defined by mean and standard deviations, and continuous variables that did not show normal distributions were defined by median and interquartile ranges. Categorical data were shown as frequencies (n) and percentages (%). The Shapiro-Wilk test was used to check whether the data were distributed normally. To compare continuous variables with normal and non-normal distributions, the t-test and the Mann–Whitney U test were used, respectively. A chi-squared test was

used to compare the categorical data. For all comparisons, a Type I error was considered to be 5%. To determine the cut-off levels for the main-PA, right-PA, left-PA, IVC-Tr, qSOFA, CURB-65, and CT-SS values for mortality, a receiver operating characteristic (ROC) curve was generated. Finally, sensitivity, specificity, and positive predictive and negative predictive values were calculated for the main-PA, right-PA, left-PA, IVC-Tr, qSOFA, CURB-65, and CT-SS values.

Results

A total of 404 patients were included in the study. The median age was 62 years (49–72), and 48.5% of the patients were male. In-hospital mortality was 15.1% (61 cases), and the median age of those who died was 74 years (68–81). The most common comorbid diseases were hypertension (50.2%), diabetes mellitus (28.2%), and coronary artery disease (17.6%). As expected, the patients who died were the oldest, and they had the most comorbidities. While the presence of GGO and pleural effusion in the CT-SS was statistically significant for mortality, consolidation and halo sign were not significant. The demographics, clinical characteristics, and CT-SS findings are presented in Table 1. While main-PA, left-PA, right-PA, and IVC-Tr diameters were wider and statistically significant in patients who died (AUC; 0.686, 0.722, 0.746, and 0.581, respectively), a statistically significant difference was not detected in terms of the IVC-AP (p = 0.053) diameter and the IVC -Tr/AP (p = 0.754) ratio. Among the vascular diameters, the highest specific measurement was IVC-Tr (79.88%), while the highest sensitive measurement was main-PA (78.69%). All the prognostic scoring systems, namely qSOFA, CURB-65, and CT-SS, had statistical significance for mortality (p < 0.001, AUC; 0.727, 0.798, and 0.708, respectively). The score with the highest specificity was the qSOFA (90.38%), while the most sensitive score was CURB-65 (91.79%). Comparisons of the data and ROC curves of the parameters considered to be prognostic for in-hospital mortality in COVID-19 patients are given in Table 2 and Figure 2.

Table 1. Demographic characteristics, vessel diameters, chest computerized tomography findings, and prognostic scores of patients with COVID-19.

	All patients n 404	Survivors n 343	Non-survivors n 61	p-value
Demographics				
Male sex, n (%)	196 (48.5)	154 (44.9)	42 (68.9)	<0.001
Age, median (IQR), years	62 (49-72)	60 (47-70)	74 (68-81)	<0.001
Chest CT, n (%)				
GGO	285 (70.5)	233 (67.9)	52 (85.2)	0.01
Consolidation	77 (19.1)	65 (19.0)	12 (19.7)	1.00
Halo sign	14 (3.5)	13 (3.8)	1 (1.6)	0.641
Reverse halo sign	27 (6.7)	26 (7.6)	1 (1.6)	0.152
Pleural effusion	24 (5.9)	14 (4.1)	10 (16.4)	0.001
Metrics, median (IQR), mm				
Main-PA	26.7 ± 4.1	26.3 ± 3.8	29.0 ± 4.8	<0.001
Right-PA	21.2 ± 4.0	20.8 ± 3.6	23.9 ± 4.6	<0.001
Left-PA	20.8 ± 3.7	20.3 ± 3.5	23.6 ± 3.7	<0.001
IVC-Tr	31.1 ± 5.1	30.9 ± 5.0	32.4 ± 5.5	0.045
IVC-AP	21.5 ± 4.0	21.3 ± 3.9	22.7 ± 4.5	0.053
IVC -Tr/AP	1.5 ± 0.9	1.5 ± 0.9	1.5 ± 0.2	0.754
Prognostic scores				
qSOFA, median (IQR),mm	0 (0-0)	0 (0-0)	1 (0-2)	<0.001
0	339 (83.9)	310 (90.4)	29 (47.5)	<0.001
1	42 (10.4)	29 (8.5)	13 (21.3)	
2	14 (3.5)	4 (1.2)	10 (16.4)	
3	9 (2.2)	0 (0.0)	9 (14.8)	
CURB-65, median (IQR)	0.9 ± 1.1	0.7 ± 0.9	2.0 ± 1.2	<0.001
CT-SS, median (IQR)	2.8 ± 2.4	2.5 ± 2.2	4.5 ± 2.8	<0.001

IQR: Interquartile range; CT-SS: Computerized tomography severity score; CURB-65: Confusion, Urea, Respiratory rate, Blood pressure, and age ≥65 years; GGO: Ground-glass opacity; IVC-AP: Inferior vena cava anteroposterior diameter, IVC-Tr: Inferior vena cava transverse diameter; IVC Tr/AP: The ratio of the transverse diameter of the inferior vena cava to the anteroposterior diameter, Left-PA: Left pulmonary artery diameter; Main-PA: Main pulmonary artery diameter; Right-PA: Right pulmonary artery diameter; qSOFA: quick Sequential Organ Failure Assessment

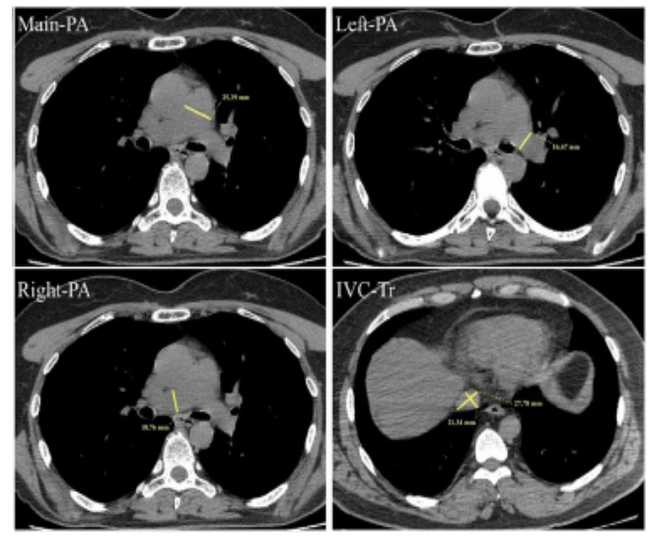

Figure 1. Pulmonary artery (PA) and inferior vena cava (IVC) measurements.

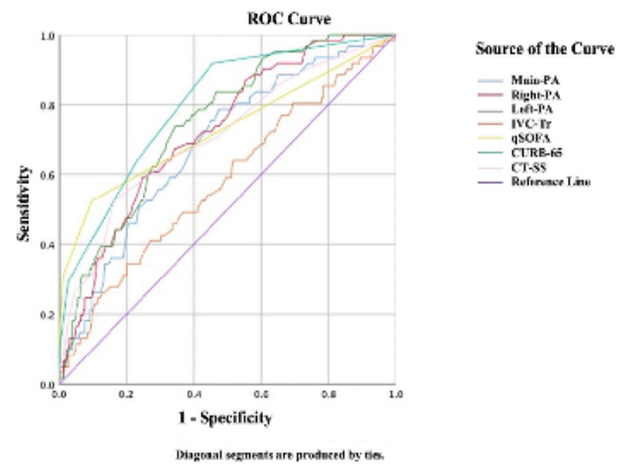

Figure 2. Receiver operating characteristic curves for vessel diameters, computerized tomography severity score (CT-SS); confusion, urea, respiratory rate, blood pressure, and age ≥65 years (CURB-65); and quick sequential organ failure assessment (qSOFA) score values for in-hospital mortality in COVID-19 patients.

Table 2. Statistical data of receiver operating characteristic curve comparisons between vessel diameters, computerized tomography severity score (CT-SS); confusion, urea, respiratory rate, blood pressure, and age ≥65 years (CURB-65); and quick sequential organ failure assessment (qSOFA) score values for in-hospital mortality in patients with COVID-19.

Metric	Main-PA	Right-PA	Left-PA	IVC-Tr	qSOFA	CURB-65	CT-SS
AUC	0.686	0.722	0.746	0.581	0.727	0.798	0.708
Cut off value	26.50	22.90	21.60	34.50	1	1	5
Sensitivity	78.69	59.02	73.77	34.43	52.46	91.79	52.46
Specificity	52.48	75.51	65.6	79.88	90.38	54.52	83.67
+PV	22.75	30.00	27.61	23.33	49.23	26.42	36.36
-PV	93.26	91.20	93.36	87.26	91.45	97.40	90.82

AUC: Area Under Curve, CT-SS: Computerized tomography severity Score; CURB-65: Confusion, Urea, Respiratory rate, Blood pressure, and age ≥65 years; IVC-Tr: Inferior vena cava transverse diameter, Main-PA: Main pulmonary artery diameter; Right-PA: Right pulmonary artery diameter; Left-PA: Left pulmonary artery diameter; PV: Predictive values, qSOFA: quick sequential organ failure assessment

Discussion

PA and IVC diameters are two easily obtained and reproducible measurements available from non-contrast chest CTs. Edwards et al.'s investigation of non-contrast chest CT measurements involving 100 normal individuals and 12 pulmonary HT patients showed an average main-PA diameter of 27.2 ± 0.6 mm [17]. The Framingham Heart Study of an asymptomatic community-based population determined that the gender-specific threshold value of main-PA from a non-contrast chest CT was 29 mm for males and 27 mm for females [16]. In another study of non-contrast chest CT scans, the enlarged PA diameter (main-PA ≥ 31 mm) had a specificity of 80–98% and a positive predictive value of 85–98% for pulmonary HT diagnosis, and these patients had a 2–3 times higher risk of mortality than normal patients [18]. Pulmonary vasoconstriction described through low angiotensin II and pulmonary small vessel thrombosis and inflammation in an autopsy series of patients with COVID-19 pneumonia support the pressure change hypothesis of pulmonary arteries [19]. Although the primary aim of the current study was not to determine a limit value as a predictor of mortality in COVID-19 patients, a cut-off value of 26.5 mm for main-PA had a sensitivity of 78.69% and a negative predictive value of 93.26% for mortality. Main-PA, left-PA, and right-PA diameters were wider and statistically significant in patients who died ($p < 0.001$ and AUC; 0.686, 0.722, and 0.746, respectively).

IVC sizes have previously been suggested as useful predictive markers of adverse cardiopulmonary events and survival [20, 21]. In a study examining the changes in IVC, aorta, and PA diameters in patients with pulmonary embolism, IVC diameters were found to be larger in the pulmonary embolism group than in the control group. ($p < 0.001$ and IVC diameter; 24 mm and 23 mm, respectively) [22]. Acute cardiac damage is a common complication in COVID-19 patients because they have an increased risk of acute coronary artery disease, cardiogenic shock, pulmonary embolism, and heart failure [12, 23]. In addition, it has been shown that the occurrence of acute cardiac events increases the risk of COVID-19-related death [24]. In an echocardiography study examining findings of RV dysfunction in COVID-19 patients, Li et al. found that the maximum and minimum diameters of IVC increased significantly in critically severe patients compared to healthy subjects ($p < 0.01$) [25]. In our measurements of IVC, IVC-Tr was slightly significant for mortality (AUC = 0.581, $p = 0.045$). IVC-Tr had a specificity of 79.88% and a negative predictive value of 87.26% for mortality at a specified cut-off value of 34.50 mm.

In the study cohort, all three prognostic scores, including qSOFA, CURB-65, and CT-SS scores, showed a statistical difference in mortality ($p < 0.001$, AUC; 0.727, 0.798, and 0.708, respectively). The highest specific score was qSOFA (90.38%), while the most sensitive score was CURB-65 (91.79%) for mortality.

The detection of enlarged PA in non-contrast chest CT may have a potential impact on patient management and treatment. COVID-19 patients can rapidly worsen with RV dysfunction and insufficient oxygenation for ventilation-perfusion incompatibility. In patients with severe pneumonia and dilated PA measurements, alveolar ventilation may be optimized to limit hypoxic vasoconstriction, and prone ventilation may be preferred to minimize positive end-expiratory pressure and hemodynamic effects. Close monitoring of pulmonary vascular resistance should be considered to optimize inotropic support and reduce RV afterload.

Limitations

The limitation of this study was the lack of right cardiac catheterization or echocardiography patient data. Although echocardiography is a widely used tool to measure PA pressure, the diagnostic accuracy is affected by heart rate, operator experience, and, especially, the presence of significant lung disease. Therefore, it is not routinely applied to all COVID-19 patients. During the active disease, we found an association between PA diameter and COVID-19 prognosis. However, we did not have knowledge of the pre-COVID-19 PA diameter, and we did not follow up on the PA diameter after the disease was treated. The lack of data on the incidence of pulmonary embolism, which can affect the diameter of the PA, was another limitation.

Conclusion

This study demonstrated that PA and IVC diameters, which are easily measured from non-contrast chest CT used for COVID-19 pneumonia assessment during hospital admission, can provide additional prognostic information along with other prognostic scores and assist clinicians with patient management.

Scientific Responsibility Statement

The authors declare that they are responsible for the article's scientific content

including study design, data collection, analysis and interpretation, writing, some of the main line, or all of the preparation and scientific review of the contents and approval of the final version of the article.

Animal and human rights statement
All procedures performed in this study were in accordance with the ethical standards of the institutional and/or national research committee and with the 1964 Helsinki declaration and its later amendments or comparable ethical standards. No animal or human studies were carried out by the authors for this article.

Funding: *None*

Conflict of interest
None of the authors received any type of financial support that could be considered potential conflict of interest regarding the manuscript or its submission.

References
1. Rosenberg ES, Dufort EM, Blog DS, Hall EW, Hoefer D, Backenson BP, et al. COVID-19 Testing, Epidemic Features, Hospital Outcomes, and Household Prevalence, New York State-March 2020. Clin Infect Dis. 2020;71(8):1953–9.
2. Zhou F, Yu T, Du R, Fan G, Liu Y, Liu Z, et al. Clinical course and risk factors for mortality of adult inpatients with COVID-19 in Wuhan, China: a retrospective cohort study. Lancet. 2020;395(10229):1054–62.
3. Chen N, Zhou M, Dong X, Qu J, Gong F, Han Y, et al. Epidemiological and clinical characteristics of 99 cases of 2019 novel coronavirus pneumonia in Wuhan, China: a descriptive study. Lancet. 2020;395(10223):507–13.
4. Kim MA, Park JS, Lee CW, Choi WI. Pneumonia severity index in viral community-acquired pneumonia in adults. PLoS ONE. 2019;14(3):e0210102.
5. Seymour CW, Liu VX, Iwashyna TJ. Assessment of Clinical Criteria for Sepsis: For the Third International Consensus Definitions for Sepsis and Septic Shock (Sepsis-3). JAMA. 2016;315(8):762-74.
6. Freund Y, Lemachatti N, Krastinova E, van Laer M, Claessens YE, Avondo A, et al. Prognostic accuracy of sepsis-3 criteria for in-hospital mortality among patients with suspected infection presenting to the emergency department. J Am Med Assoc. 2017;317(3):301–8.
7. April MD, Aguirre J, Tannenbaum LI, Moore T, Pingree A, Thaxton RE, et al. Sepsis Clinical Criteria in Emergency Department Patients Admitted to an Intensive Care Unit: An External Validation Study of Quick Sequential Organ Failure Assessment. J Emerg Med. 2017;52(5):622–31.
8. Xu B, Xing Y, Peng J, Zheng Z, Tang W, Sun Y, et al. Chest CT for detecting COVID-19: a systematic review and meta-analysis of diagnostic accuracy. Eur Radiol. 2020;30(10):5720–7.
9. Revel MP, Parkar AP, Prosch H, Silva M, Sverzellati N, Gleeson F, et al. COVID-19 patients and the radiology department – advice from the European Society of Radiology (ESR) and the European Society of Thoracic Imaging (ESTI). Eur Radiol. 2020;30(9):4903–9.
10. Simpson S, Kay FU, Abbara S, Bhalla S, Chung JH, Chung M, et al. Radiological Society of North America Expert Consensus Statement on Reporting Chest CT Findings Related to COVID-19. Endorsed by the Society of Thoracic Radiology, the American College of Radiology, and RSNA - Secondary Publication. J Thorac Imaging. 2020;35(4):219–27.
11. Yildiz M, Yadigar S, Yildiz BŞ, Aladag NB, Keskin O, Ozer RS, et al. Evaluation of the relationship between COVID-19 pneumonia severity and pulmonary artery diameter measurement. Herz. 2021;46(1):56–62.
12. Fox SE, Akmatbekov A, Harbert JL, Li G, Quincy Brown J, vander Heide RS. Pulmonary and cardiac pathology in African American patients with COVID-19: an autopsy series from New Orleans. Lancet Respir Med. 2020;8(7):681–6.
13. D'Andrea A, Scarafile R, Riegler L, Liccardo B, Crescibene F, Cocchia R, et al. Right Ventricular Function and Pulmonary Pressures as Independent Predictors of Survival in Patients With COVID-19 Pneumonia. JACC Cardiovasc Imaging. 2020;13(11):2467–8.
14. Ai T, Yang Z, Hou H, Zhan C, Chen C, Lv W, et al. Correlation of Chest CT and RT-PCR Testing for Coronavirus Disease 2019 (COVID-19) in China: A Report of 1014 Cases. Radiology. 2020;296(2):32–40.
15. Kim JH, Kim WY, Oh J, Kang H, Lim TH, Ko BS. Association of inferior vena cava diameter ratio measured on computed tomography scans with the outcome of patients with septic shock. Medicine. 2020;99(43):e22880.
16. Truong QA, Massaro JM, Rogers IS, Mahabadi AA, Kriegel MF, Fox CS, et al. Reference values for normal pulmonary artery dimensions by noncontrast cardiac computed tomography the framingham heart study. Circ Cardiovasc Imaging. 2012;5(1):147–54.
17. Edwards PD, Bull RK, Coulden R. CT measurement of main pulmonary artery diameter. Br J Radiol. 1998;71(850):1018–20.
18. Truong QA, Bhatia HS, Szymonifka J, Lavender Z, Mhs P, Waxman AB, et al. A Four-Tier Severity Classification System of Pulmonary Artery Metrics on Computed Tomography for the Diagnosis and Prognosis of Pulmonary Hypertension. J Cardiovasc Comput Tomogr. 2019;12(1):60–6.
19. Esposito A, Palmisano A, Toselli M, Vignale D, Cereda A, Rancoita PMV, et al. Chest CT–derived pulmonary artery enlargement at the admission predicts overall survival in COVID-19 patients: insight from 1461 consecutive patients in Italy. Eur Radiol. 2021;31(6):4031–41.
20. Nath J, Vacek JL, Heidenreich PA. A dilated inferior vena cava is a marker of poor survival. Am Heart J. 2006;151(3):730–5.
21. Fukui M, Takamochi K, Suzuki K, Hotta A, Ando K, Matsunaga T, et al. The maximum dimension of the inferior vena cava is a significant predictor of postoperative mortality in lung cancer patients with idiopathic interstitial pneumonia. Surg Today. 2019;49(6):467–73.
22. Gökçen E, Demir B, Savrun A, Çaltekin İ, Yıldırım G, Korkmaz H, et al. Evaluation of Inferior Vena Cava/Abdominal Aorta Diameter Index in Pulmonary Embolism. Eurasian J Emerg Med. 2020;19(2):82-8
23. Madjid M, Safavi-Naeini P, Solomon SD, Vardeny O. Potential Effects of Coronaviruses on the Cardiovascular System: A Review. JAMA Cardiol. 2020;5(7):831–40.
24. Guzik TJ, Mohiddin SA, Dimarco A, Patel V, Savvatis K, Marelli-Berg FM, et al. COVID-19 and the cardiovascular system: implications for risk assessment, diagnosis, and treatment options. Cardiovasc Res. 2020;116(10):1666–87.
25. Li YL, Zheng JB, Jin Y, Tang R, Li M, Xiu CH, et al. Acute right ventricular dysfunction in severe COVID-19 pneumonia. Rev Cardiovasc Med. 2020;21(4):635–41.

How to cite this article:
Mehmet Altuntaş, Mümin Murat Yazıcı, Ali Çelik, Kemal Panç, Nur Hürsoy. *Inferior vena cava and pulmonary artery diameters for prognosis of Coronavirus disease. Ann Clin Anal Med 2022; DOI: 10.4328/ACAM.21220*