Annals of Clinical and Analytical Medicine
Original Research

The effect of radial shortening osteotomy and the level of osteotomy line on lunate vascularization in Kienböck's disease

Radial shortening osteotomy in stage 2 and 3a Keinböch's disease

Tahsin Sami Çolak
Departmant of Orthopedics and Traumatology, Meram Faculty of Medicine, Necmettin Erbakan University, Konya, Turkey

Abstract
Aim: The aim of this study is to show the intraosseous changes in the vascularity of the lunate with magnetic resonance imaging (MRI) after radial shortening osteotomy (RSO), which is an extra-articular intervention, as well as the effect of the osteotomy level on the vascularity of the lunate.
Material and Methods: Thirty-one patients with a diagnosis of Lichtman Stage II and IIIA Kienböck who underwent RSO were analyzed retrospectively. Among these patients, 17 patients who had both preoperative and postoperative MRIs were included in the study. The mean age of the patients was 34.2. (±12.25) years. Lunate vascularity was evaluated with diffusion MRI before and after surgery. In addition, the effect of osteotomy level on the blood supply of the lunate was also examined.
Results: It was observed that RSO had a positive effect on the vascularity of the lunate radiologically and clinically (94%). Especially in patients with osteotomy level between 20-24 mm, the increase in vascularity was more evident than in other patients.
Discussion: In this study, although clinical improvement was detected in the majority of patients (94%) after RSO, only 58.9% of the patients showed increased vascularity of lunate, suggesting that the osteotomy level has an effective role in increasing the vascularity to the lunate.

Keywords
Keinböck's disease, Lunate, Radial Shortening Osteotomy, Revascularization

DOI: 10.4328/ACAM.21372 Received: 2022-08-28 Accepted: 2022-09-28 Published Online: 2022-10-11
Corresponding Author: Tahsin Sami Çolak, Departmant of Orthopedics and Traumatology, Meram Faculty of Medicine, Necmettin Erbakan University, Konya, Turkey.
E-mail: drtahsincolak@gmail.com P: +90 530 037 37 36 F: +90 332 223 00 00
Corresponding Author ORCID ID: https://orcid.org/0000-0001-7028-9397

Introduction

The etiology of Kienböck's disease is still controversial since Robert Kienböck first identified the disease [1]. Lunatum is at risk of osteonecrosis due to disruption of the venous flow network and limited collateral blood flow. In addition, the presence of negative ulnar variance accelerates the progression of the disease morphologically [2]. A number of treatment strategies have been described in the literature according to the stage of the disease [3-7].

At an early stage of the Keinböch disease treatment algorithm, decompressive methods are more recommended [6-7]. Especially in patients with negative ulnar variance in whom wrist arthrosis does not develop, radial shortening osteotomy (RSO) and radial closed-wedge osteotomy are suggested to prevent the worsening of the disease by reducing the force transmitted to the lunate. In the literature, it was reported that positive results were obtained clinically and radiologically [8-10]. Blanco et al. suggested that radial osteotomy alone even without shortening, could improve arterial blood flow and venous drainage in the wrist, and improve vascularity around the lunate and has good clinical results [11]. To the best of our knowledge, there is no study in the literature that evaluates correlation between the vascular changes in the lunate after RSO with the osteotomy level and demonstrates it radiologically with Magnetic Resonance Imaging (MRI). We think that determining the optimum osteotomy level will have a more positive effect on the blood supply of the lunate. The aim of this study is to reveal the intraosseous therapeutic effect of RSO applied as an extra-articular procedure on the vascularity of the lunate using MRI in Litchman Stage 2 and 3A Keinböch patients, and to investigate the effect of the osteotomy level on the vascularity of the lunate.

Material and Methods

In this study, 31 patients who underwent RSO for Stage 2 and 3A Kienböck's disease in our clinic between January 2012 and January 2020 were retrospectively analyzed. Our study was performed with the approval of the hospital's local ethics committee. Patients with pre- and postoperative MRI and clinical follow-up of more than 2 years were included in the study, while patients who did not meet these criteria or had other wrist pathology, had no union, and had additional wrist trauma were excluded from the study. The study included 17 patients who met the criteria. The mean age of the patients was 34.2 (18-53) years. Ten (58.8%) of these patients were male and 7 (41.2%) were female. Eight (47.1%) of these patients had stage 2 and 9 (52.9%) had stage 3A Keinböck disease. The mean follow-up time was 52.4 months (24-69). The mean negative ulnar variance was -1.8 mm (-3.4-1.0). Preoperative and postoperative MRIs were compared by an experienced independent radiologist, and vascular changes in the lunate bone were evaluated according to criteria established by Lee et al. (Table1). Radius osteotomy line levels were measured from the distal edge of the radial styloid at plain radiographs. The mean osteotomy level was calculated as 25 mm (17-58 mm). The amount of shortening was determined by calculating the negative ulnar variance preoperatively. The operations were performed by a single experienced surgeon. In the early postoperative period, the patients were followed up for 1 month using a splint. Wrist rehabilitation protocol was started after splint removal in all patients. Visual Analogue Scale (VAS) scores were recorded before and after surgery. In the follow-up, the clinical conditions of the patients were evaluated periodically by looking at the VAS score. In only one patient, the implants were removed voluntarily, although there was no additional complaint.

The data obtained from the research were transferred to the SPSS (Statistical Package for Social Sciences) v.18.0 package program for statistical analysis. The relationship between increased vascularity and VAS scores used in clinical evaluation was evaluated using correlation analysis. The t-test was used to compare preoperative and final follow-up measurements. $P<0.05$ was considered statistically significant.

Results

No complications (neurovascular injury, infection, nonunion) were observed in 17 patients during the follow-up. While clinical complaints were decreased in 94% (16/17) of the patients, an increase was observed in the complaints of 1 patient. The mean preoperative VAS score was 7.8 (6-9). The mean VAS score of the patients at the last follow-up was 2.3 (1-9) (Table 2). While significant increase in blood flow was observed in 10 (58.9%) patients, there was no increase in blood flow in 6 (35.2%) patients. Decreased lunate blood flow and increased disease stage and fragmentation were observed in 1 (5.9%) patient. In this patient, the osteotomy level was 58 mm. Although the increase in blood supply in the lunate was more prominent in patients with osteotomy level between 20-24 mm compared to

Table 1. Analysis of lunate bone changes in MRI [17].

	Classification	Description
Bone fragmentation and collapse	Progression	Progress in fragmentation and collapse
	No change	No definite change in fragmentation or collapse
	Healing	Signs of fusion or increased lunate height
Blood flow	Decrease	Contrast decrease in lunate bone
	No change	No definite change in vascularity
	Increase	Contrast enhancement in non-contrast-enhanced parts of the lunate bone

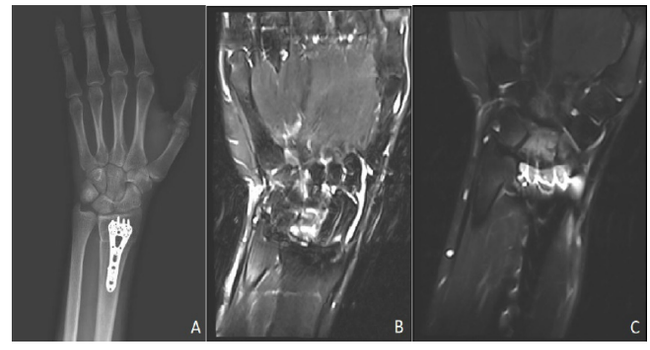

Figure 1. A: Postoperative anteroposterior wrist X ray of RSO procedure, B: Preoperative fat saturated CoronalT2 sequence wrist MRI of Kienböck's Disease, C: Postoperative fat satureted Coronal T2 sequence wrist MRI of Kienböck's Diseaase 13 months after operation.

Table 2. Preoperative and final follow-up VAS scores of the patients

Patient no	1	2	3	4	5	6	7	8	9	10	11	12	13	14	15	16	17
Preop VAS score	7	8	8	8	9	6	7	7	8	7	8	8	9	9	9	7	8
Last follow-up VAS score	1	9	2	2	2	1	1	3	2	2	1	2	2	2	2	1	3

VAS: Visual Analogue Scale

Table 3. Demographic data of patients, osteotomy levels, postoperative Litchman stage and MRI signal changes

Patient no	Sex	Age	Osteotomy level	Preop stage	Postop stage	MRI signal change
1	M	44	21mm	IIIA	IIIA	↑
2	F	26	58mm	II	IIIA	↓
3	M	39	24mm	IIIA	IIIA	↑
4	M	19	18mm	IIIA	IIIA	↔
5	M	27	24mm	II	II	↑
6	F	30	20mm	II	II	↑
7	M	53	21mm	IIIA	IIIA	↑
8	M	35	17mm	II	II	↔
9	F	46	20mm	II	II	↑
10	F	43	21mm	II	II	↑
11	F	39	22mm	IIIA	IIIA	↑
12	M	24	18mm	IIIA	IIIA	↔
13	M	30	22mm	II	II	↑
14	F	18	22mm	II	II	↑
15	M	42	32mm	IIIA	IIIA	↔
16	M	25	33mm	IIIA	IIIA	↔
17	F	42	32mm	IIIA	IIIA	↔

M: Male, F: Female; ↑: Bone marrow signal increase; ↓: Bone marrow signal decrease; ↔: No change in bone marrow signal

other patients, no statistically significant difference was found (p=0.645) (Table 3). None of the patients developed lunate collapse or wrist arthrosis (Figure 1).

Discussion

In this study, although clinical improvement was detected in the vast majority of patients (94%) after RSO, only 58.9% of the patients had increased blood supply in lunate. In patients with osteotomy level of 20-24 mm, the increase in blood supply was more evident, but there was no statistically significant difference between the increase in blood supply and the osteotomy level (p=0.645). Although our obtained outcomes are consistent with similar literature data, we think that different studies should be done to determine the optimum osteotomy level that will increase the blood flow of the lunate.

RSO is generally preferred in the treatment of Lichtman Stage 2 and 3A disease [10,12]. The aim of RSO is to reduce the load on the lunate. In addition, theoretically, it is also aimed to increase the vascularization of the lunate. There are many studies investigating vascular changes in the lunate after RSO [13-15]. Nakamura et al. reported that as a result of a 3-year follow-up of 24 patients who underwent RSO or radial wedge osteotomy, there was an increase in signal in both T1 and T2 sequences on MRI in 79.2% (19/24) of the patients [13]. On the other hand, Matsui et al. showed increased vascularity of the lunate during at least 10 years of follow-up in 7 (70%) of 10 patients who underwent radial shortening osteotomy [15]. In our study, this rate was found to be 58.9% (10/17). In addition, studies demonstrating the success of radial osteotomy have hypothesized that even only radial osteotomy without shortening improves symptoms by changing the local vascular environment [11,16].

While investigating the effect of RSO on the vascularity of lunate, no study was found in the literature in which the optimum osteotomy level was determined. Our study is unique in terms of contribution to the literature, as we also evaluated the effect of osteotomy level on blood flow. Especially in all 10 patients (100%) with an osteotomy level of 20-24mm, both clinical complaints and radiological increase in blood flow were detected, suggesting that the osteotomy level is important in the healing process.

There are studies in the literature describing lunate revascularization after RSO radiologically. Various methods such as radiography, computed tomography (CT), and MRI have been usually used to evaluate radiographic results and increase in blood flow, after RSO [17-20]. Evaluation of the lunatum with simple radiographs is not sufficient to evaluate Kienböck's disease after treatment. In this study, MRI was used to evaluate the vascularization status after RSO. Gadolinium (Gd)-MRI provides direct visualization of perfusion and is suitable for investigating the vascularity of the lunate [21]. Both preoperative and postoperative Gd-MRI showed significantly increased revascularization in the lunate in 10 (58.9%) of 17 patients. It was also observed that the perfused volume of the lunate increased significantly. This finding suggests that RSO induces an increase in vascularization as well as a decrease in the load on the lunate.

In addition to osteotomy, the absence of increase in blood supply despite shortening in all patients suggests that there are some other factors affecting blood supply. For example, Lunate types were not taken into account in the evaluation in this study. We think that different results may arise due to the fact that bone shapes with different anatomical features may affect the intraosseous pressure to which the lunate is exposed. Also, since we made the shortening amounts according to the negative ulnar variance, shortening was not performed at the same rate for each patient. We think that this situation may also affect our results.

The present study had several limitations. First, we used a retrospective method that limits the level of evidence. Secondly, the number of our patients was not sufficient to allow subgroup analysis in terms of parameters that may affect the results such as age, gender and smoking. However, as the number of cases increases, comparative studies with the control group who only underwent osteotomy without radial shortening may reveal the

effect of shortening on blood supply more clearly.

Conclusion

The results of RSO performed in patients with negative ulnar variance in Stage 2 and Stage 3A Keinböch disease are clinically and radiologically satisfactory. The radiological increase in blood flow and the fact that the disease stage has not progressed, especially in all patients (100%) with an osteotomy level of 20-24 mm, shows that the osteotomy level has an important role in the healing process. However, it is obvious that multicenter clinical studies should be conducted to determine the optimum osteotomy level.

Scientific Responsibility Statement

The authors declare that they are responsible for the article's scientific content including study design, data collection, analysis and interpretation, writing, some of the main line, or all of the preparation and scientific review of the contents and approval of the final version of the article.

Animal and human rights statement

All procedures performed in this study were in accordance with the ethical standards of the institutional and/or national research committee and with the 1964 Helsinki declaration and its later amendments or comparable ethical standards. No animal or human studies were carried out by the authors for this article.

Funding: *None*

Conflict of interest

None of the authors received any type of financial support that could be considered potential conflict of interest regarding the manuscript or its submission.

References

1. Camus EJ, Van Overstraeten L. Kienböck's disease in 2021. Orthop Traumatol Surg Res. 2022;108(1S):103161.

2. Goeminne S, Degreef I, De Smet L. Negative ulnar variance has prognostic value in progression of Kienböck's disease. Acta Orthop Belg. 2010;76(1):38-41.

3. Kirkeby L, von Varfalva Palffy L, Hansen TB. Long-term results after vascularised bone graft as treatment of Kienböck disease. J Plast Surg Hand Surg. 2014;48(1):21-3.

4. Moritomo H, Murase T, Yoshikawa H. Operative technique of a new decompression procedure for Kienböck disease: partial capitate shortening. Tech Hand Up Extrem Surg. 2004;8(2):110-5.

5. Stahl S, Stahl AS, Meisner C, Hentschel PJH, Valina S, Luz O, et al. Critical analysis of causality between negative ulnar variance and Kienböck disease. Plast Reconstr Surg. 2013;132(4):899-909.

6. Lichtman DM, Lesley NE, Simmons SP. The classification and treatment of Kienbock's disease: the state of the art and a look at the future. J Hand Surg Eur Vol. 2010;35(7):549-54.

7. Lichtman DM, Pientka WF 2nd, Bain GI. Kienböck Disease: A New Algorithm for the 21st Century. J Wrist Surg. 2017;6(1):2-10.

8. Watanabe T, Takahara M, Tsuchida H, Yamahara S, Kikuchi N, Ogino T. Long-term follow-up of radial shortening osteotomy for Kienbock disease. J Bone Joint Surg Am. 2008;90(8):1705-11.

9. Viljakka T, Tallroth K, Vastamäki M. Long-term outcome (20 to 33 years) of radial shortening osteotomy for Kienböck's lunatomalacia. J Hand Surg Eur Vol. 2014;39(7):761-9.

10. Kolovich GP, Kalu CM, Ruff ME. Current Trends in Treatment of Kienböck Disease: A Survey of Hand Surgeons. Hand (N Y). 2016;11(1):113-8.

11. Blanco RH, Blanco FR. Osteotomy of the radius without shortening for Kienböck disease: a 10-year follow-up. J Hand Surg Am. 2012;37(11):2221-5.

12. Danoff JR, Cuellar DO, Jane O, Strauch RJ. The Management of Kienböck Disease: A Survey of the ASSH Membership. J Wrist Surg. 2015;4(1):43-8.

13. Nakamura R, Watanabe K, Tsunoda K, Miura T. Radial osteotomy for Kienböck's disease evaluated by magnetic resonance imaging. 24 cases followed for 1-3 years. Acta Orthop Scand. 1993;64(2):207-11.

14. Camus EJ, Van Overstraeten L. Surgical technique of a radial wedge "camembert" osteotomy in Kienböck disease. Tech Hand Up Extrem Surg. 2012 ;16(2):75-9.

15. Matsui Y, Funakoshi T, Motomiya M, Urita A, Minami M, Iwasaki N. Radial shortening osteotomy for Kienböck disease: minimum 10-year follow-up. J Hand Surg Am. 2014; 39(4):679-85.

16. Illarramendi AA, Schulz C, De Carli P. The surgical treatment of Kienböck's disease by radius and ulna metaphyseal core decompression. J Hand Surg Am. 2001 ;26(2):252-60.

17. Lee JH, Kim J, Hwang JS, Baek GH. Improvement in lunate perfusion after radial closing-wedge osteotomy in patients with Kienböck's disease. Hand Surg Rehabil. 2021;40(5):588-594.

18. Unal KO, Bingol O, Korucu A, Kilic E, Ozdemir G, Akinci M. Medium-term clinical and radiological results of surgically treated stage 3A Kienböck's disease. Hand Surg Rehabil. 2021;40(6):737-43.

19. Shin YH, Kim J, Gong HS, Rhee SH, Cho MJ, Baek GH. Clinical Outcome of Lateral Wedge Osteotomy of the Radius in Advanced Stages of Kienböck's Disease. Clin Orthop Surg. 2017;9(3):355-62.

20. Shin YH, Kim JK, Han M, Lee TK, Yoon JO. Comparison of Long-Term Outcomes of Radial Osteotomy and Nonoperative Treatment for Kienböck Disease: A Systematic Review. J Bone Joint Surg Am. 2018 18;100(14):1231-40.

21. Arnaiz J, Piedra T, Cerezal L, Ward J, Thompson A, Vidal JA, et al. Imaging of Kienböck disease. AJR Am J Roentgenol. 2014;203(1):131-9.

How to cite this article:

Tahsin Sami Çolak*. The effect of radial shortening osteotomy and the level of osteotomy line on lunate vascularization in Kienböck's disease. Ann Clin Anal Med 2022; DOI: 10.4328/ACAM.21372*