This work is licensed under a Creative Commons Attribution-NonCommercial 4.0 International License (CC BY-NC 4.0). To view a copy of the license, visit **https://creativecommons.org/licenses/by-nc/4.0/**

Annals of Clinical and Analytical Medicine
Original Research

Evaluation of clinical and radiographic features of impacted premolar teeth in the central black sea region

Sefa Çolak[1], Aras Erdil[2], Ahmet Altan[3]

[1]Department of Oral and Maxillofacial Surgery, Faculty of Dentistry, Tokat Gaziosmanpaşa University, Tokat, Türkiye.
[2]Department of Oral and Maxillofacial Surgery, Faculty of Dentistry, Uşak University, Uşak, Türkiye.
[3]Department of Oral and Maxillofacial Surgery, Faculty of Dentistry, Necmettin Erbakan University, Konya, Türkiye.

Abstract

Aim: The aim of this study was to evaluate the clinical and radiographic features, associated pathologies and treatment planning of impacted premolar teeth among a specific population.

Methods: Patients who applied to an oral and maxillofacial surgery clinic with the complaint of impacted premolars between 2017 and 2022 were included in this retrospective study. Demographic data, panoramic radiographs, treatments and associated pathologies of 83 patients included in the study were recorded. Impacted premolars were classified according to depth and angulation.

Results: A total of 63 teeth were observed in 51 female patients and a total of 45 teeth were observed in 32 male patients. Of 108 impacted premolars, 32 teeth were detected in the maxilla and 76 in the mandible. The impaction depth classification revealed that 44 of 108 teeth were in Class 1, 58 of them were in Class 2, and 6 of them were in Class 3. Angulation classification revealed that 43 teeth were vertically located, 41 were mesioangular, 13 teeth were horizontally located, nine teeth were distoangular, one was buccolingual, and one was located ectopically regarding the associated pathologies, of the 108 impacted premolars, dentigerous cysts were observed with 13 teeth, odontomas with four teeth, persistent primary teeth with four teeth, and root resorption in the adjacent teeth with two teeth.

Conclusion: Mandibular and maxillary second premolars tend to be impacted at a higher rate than first premolars. Orthodontic treatment procedures can be applied in cases where the amount of impaction is less and severe angulation is not observed.

Keywords

dentigerous cyst, impacted teeth, premolars, surgical removal

DOI: 10.4328/ACAM.21620 Ann Clin Anal Med 2023;14(5):459-463
Received: 27.01.2023 Accepted: 02.03.2023 Published Online: 11.03.2023 Printed: 01.05.2023
Corresponding Author: Sefa Çolak, Department of Oral and Maxillofacial Surgery, Faculty of Dentistry, Tokat Gaziosmanpaşa University, Tokat, Türkiye.
E-mail: dr.sefacolak@gmail.com **P.:** +90 356 212 42 22
Corresponding Author ORCID: https://orcid.org/0000-0002-0807-9089

Introduction

Impacted teeth are those that remain entirely or partially impacted in jaw bones or mucous membranes for two years or more from the eruption.[1,2]

Various local factors such as facial growth deficiencies, eruption problems due to adjacent teeth, insufficient maxillomandibular growth, trauma, early physical maturation, persistent primary teeth, early loss of primary teeth, excessive mineralization in jaw bones, chronic inflammation in adjacent mucosal tissues, genetic factors, and diseases like rickets, anemia, congenital syphilis, tuberculosis, endocrine disorders, and various syndromes may cause impaction.[3,4] Failure to determine treatment plans at appropriate time intervals may result in the impaction of canines, premolars, or second molars, which erupt later than others.

An impacted tooth can cause pulpal diseases, periapical and periodontal pathologies, temporomandibular joint problems, facial infections, cystic lesions, and odontogenic tumors.[5] Diagnosis and treatment can be challenging for clinicians. Also, management of impacted teeth is aesthetically and functionally essential for patients.[5]

Conventional radiographs are routinely performed methods for determining the localization of impacted teeth. Panoramic, occlusal, anteroposterior, and lateral cephalometric radiographs are conventional radiographs that provide localization of impacted teeth in two dimensions.[4] Panoramic radiographs are widely preferred in routine clinical use because of their economical and practical features, which can give an idea about dental arches and surrounding anatomical structures. Also, computed tomography (CT) or cone-beam computed tomography (CBCT) have become widely adopted techniques in recent years to accurately determine the localization of the impacted tooth in all three dimensions.[6,7]

Mandibular third molars have the highest impaction rates, followed by maxillary third molars, maxillary canines, mandibular canines, premolars, and central incisors.[8-10] Various impaction patterns can be observed regarding the vertical axis of adjacent teeth, such as vertical, mesioangular, horizontal, buccolingual, distoangular, inverted, and ectopic. Also, impaction level relative to the occlusal plane can be at different depths from the level of the cementoenamel junction (CEJ) of adjacent teeth, to be positioned inferior to the apical third of adjacent roots.[10]

The impacted premolar teeth, although rarer, can cause local problems such as aesthetic problems, mastication disorders, oral hygiene problems, pathologies arising from follicular tissues, and root resorption or caries on adjacent teeth. In the literature, studies on impacted premolar teeth, except for the study of Şimşek-Kaya et al.[11] are generally observed as case reports.[12-14] This study aims to determine the prevalence, impaction patterns, related pathologies, and management strategies of impacted premolar teeth among a particular population.

Materials and Methods

Ethical approval for the current study was obtained from Tokat Gaziosmanpaşa University Clinical Research Ethics Committee (Decision No: 22-KAEK-147) and was carried out in accordance with the Helsinki Declaration of Ethical Principles for Medical Research Involving Human Subjects. Due to a retrospectively conducted database search, 94 patients who applied or were referred to Tokat Gaziosmanpaşa University, Department of Oral and Maxillofacial Surgery with the complaint of impacted premolars between 01.01.2017 and 15.08.2022 were included. Patients older than 12 years of age and with impacted teeth two years or more past the time they should have erupted were included in the study. Patients with genetic diseases (n = 2), insufficient demographic data (n = 4), radiographic distortions (n = 1), and patients under 12 years of age (n = 4) were excluded. Consequently, a total of 83 patients were included.

All panoramic radiographs were obtained with Morita Veraviewepocs 2D (Kyoto, Japan) at 70 kVp and 10 mA for 9 seconds. Panoramic radiographs were evaluated independently and blindly at different times by two oral and maxillofacial surgeons (SÇ and AE). The number of impacted maxillary and mandibular premolar teeth, their localization, angulation, and the presence of associated pathologies were recorded and categorized by the researchers. In addition, demographic data and management methods were recorded. Impacted premolars were categorized according to their depth and angulation using a classification system similar to the Pell & Gregory and Winter third molar classification.[10]

Regarding the depth of impaction, the premolars were grouped under three classes;

Class 1:
The most superior occlusal point of the impacted tooth is between the occlusal surface of the adjacent premolar or molar tooth and the CEJ.

Class 2:
The most superior occlusal point of the impacted tooth is between the CEJ of the adjacent premolar or molar tooth and the apex.

Class 3:
The most superior occlusal point of the impacted tooth is located below the apex of the adjacent premolar or molar tooth.

Regarding the angulation, the impacted premolars were classified relative to the long axes of the adjacent teeth as Vertical (0°-10°), Mesioangular (10°-70°), Distoangular (10°-70°), Horizontal (>71°), Inverted or Buccolingual, and Ectopic.

Ethical Approval

This study was approved by the Clinical Research Ethics Committee of Tokat Gaziosmanpaşa University, Faculty of Medicine (Date: 15.08.2022, Decision No: 22-KAEK-147).

Statistical Analysis

SPSS 19 (IBM SPSS Statistics 19, SPSS inc., an IBM Co., Somers, NY) program was used to analyze the obtained data statistically. The Shapiro-Wilk test was utilized to verify the normality of the data. Descriptive analyses were reported as mean ± standard deviation. Pearson's chi-square test was performed to determine the association between categorical variables (such as gender, angulation, associated pathologies, e.g.) and the outcome variables. The relationship between age, number of impacted teeth, and applied treatment methods were analyzed using the Mann-Whitney U test or Kruskal-Wallis test followed by the post-hoc Dunn's test. The P values below $P < .05$ were interpreted as significant.

Reporting Guidelines

This study was reported in accordance with the STROBE guideline.

Results

The study population consisted of 83 patients (32 M [38.55%], 51 F [41.45%]). The mean age of males was 24.21 ± 11.73 years (min = 12, max = 72), the mean age of females was 26.37 ± 13.77 (min = 13, max = 73), and the mean age of the study population was 25,54 ± 12.98 years (min = 12, max = 73). The distribution of impacted premolars due to gender was examined, and 63 teeth (58.33%) were observed in 51 females, and 45 teeth (41.66%) were observed in 32 male patients. It was observed that the data were not normally distributed. According to the results of the Mann-Whitney U test, no significant relationship was found between gender and the number of impacted teeth (P = .24). Of 108 impacted premolars, 32 teeth were detected in the maxilla

and 76 in the mandible. Of the 83 patients, 63 had one impacted premolar, 16 had two impacted premolars, three had three impacted premolars, and one had four impacted premolars. The impaction depth classification revealed that 44 of 108 teeth were in Class 1 (40.74%), 58 of them were in Class 2 (53.70%), and 6 of them were in Class 3 (5.55%). In the examination made according to the depth of the impacted teeth, it was seen that the data were normally distributed as a result of the Shapiro-Wilk test. According to the results of the chi-square test, there was no significant difference between class 1, class 2 and class 3 impacted teeth (P = .620).

Table 1. Distribution of Impacted Premolar Teeth by Depth Classification and Related Variables

Variables	Depth of Impaction			Total
	Class 1	Class 2	Class 3	
Gender				
Female	28	31	4	63
Male	16	27	2	45
Total	44	58	6	108
Impacted Tooth				
14	0	3	0	3
15	6	7	1	14
24	0	2	0	2
25	4	8	1	13
34	2	3	0	5
35	15	21	2	38
44	1	1	1	3
45	16	13	1	30
Total	44	58	6	108
Angulation				
Mesioangular	22	18	1	41
Distoangular	2	6	1	9
Vertical	17	24	2	43
Horizontal	3	9	1	13
Buccolingual	0	1	0	1
Ectopic	0	0	1	1
Total	44	58	6	108
Associated Pathologies				
Root resorption	0	2	0	2
Dentingerous cyst	3	8	2	13
Odontoma	1	2	1	4
Persistent primary tooth	1	2	1	4

Regarding the frequency of impaction, it was observed that the lower left second premolars were the highest (38 teeth), followed by lower right second premolars (30 teeth), upper right second premolars (14 teeth), upper left second premolars (13 teeth), and lower left first premolars (5 teeth). The least impacted teeth were upper right first premolars (3 teeth), lower right first premolars (3 teeth), and upper left first premolars (2 teeth) (Table 1). The angulation classification revealed that 43 teeth were vertically located, 41 were mesioangular, 13 teeth were horizontally located, nine teeth were distoangular, one was buccolingual, and one was ectopically located (Table 2) (Figure 2). When the angulations of the impacted premolar teeth were examined, no significant difference was found with the chi-square test (P = .171). Regarding the associated pathologies, of the 108 impacted premolars, dentigerous cysts were observed with 13 teeth, odontomas with four teeth, persistent primary teeth with four teeth, and root resorption in the adjacent teeth with two teeth (Table 1) (Figure 1).

Among the treatment methods applied to 83 patients, 95 impacted teeth were surgically removed, ten impacted teeth were surgically exposed with orthodontic intervention, and three impacted teeth were followed-up clinically and radiologically. Indications in patients who underwent surgical removal were observed as space-saving in orthodontic treatment, prosthetic applications, presence of associated pathologies, and at the request of patients (Table 3). When the age of the patients and the depth of the impacted teeth and the treatments applied were compared, it was observed that the data were not normally distributed with the Shapiro-Wilk test and the Kruskal-Wallis test was applied. There was no significant difference between age and depth (P = .136).



Figure 1. *A Case Sample Demonstrating Root Resorption in a Mandibular First Molar and Impacted Lower Left Second Premolar*

Table 2. Classification of Impacted Premolar Teeth Due to Angulation

Tooth Number	Angulation						Total
	Mesioangular	Distoangular	Vertical	Horizontal	Buccolingual	Ectopic	
14	2	0	1	0	0	0	3
15	5	0	7	1	1	0	14
24	2	0	0	0	0	0	2
25	3	2	6	2	0	0	13
34	0	0	5	0	0	0	5
35	19	4	13	2	0	0	38
44	1	0	2	0	0	0	3
45	9	3	9	8	0	1	30
Total	41	9	43	13	1	1	108

Table 3. The Treatments Applied

Tooth Number	Extraction			Follow-up			Orthodontic Intervention			Total
	Class 1	Class 2	Class 3	Class 1	Class 2	Class 3	Class 1	Class 2	Class 3	
14	0	3	0	0	0	0	0	0	0	3
15	6	6	1	0	1	0	0	0	0	14
24	0	2	0	0	0	0	0	0	0	2
25	4	8	1	0	0	0	0	0	0	13
34	1	2	0	0	1	0	1	0	0	5
35	14	16	2	0	1	0	1	4	0	38
44	1	1	1	0	0	0	0	0	0	3
45	13	12	1	0	0	0	3	1	0	30
Total	39	50	6	0	3	0	5	5	0	108

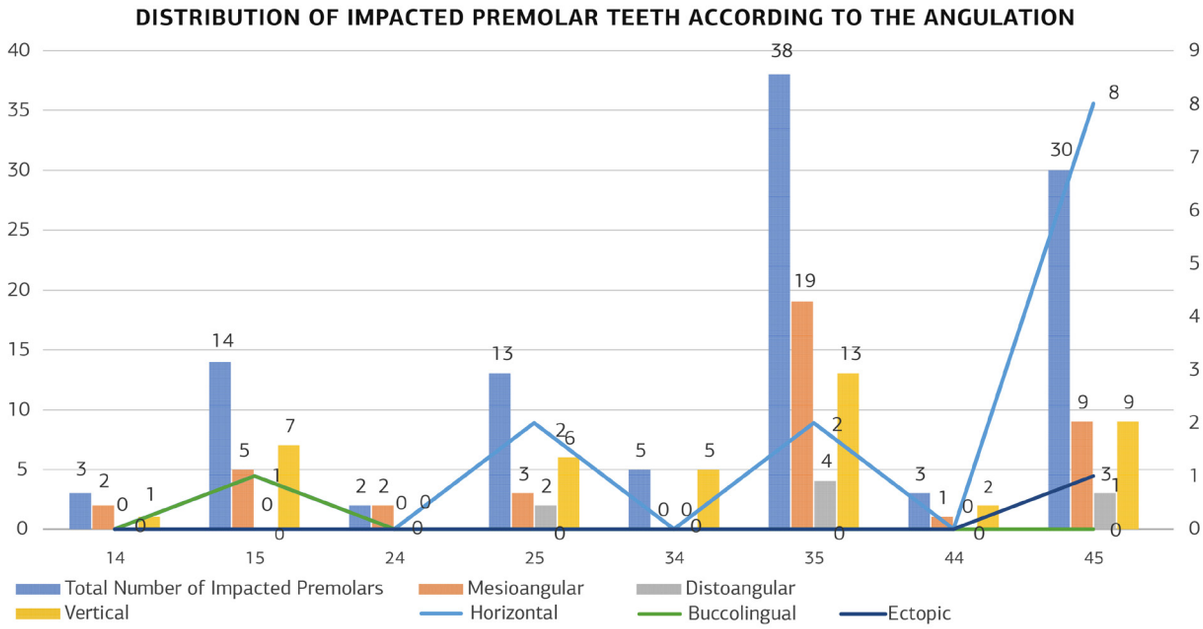

Figure 2. *Distribution of Impacted Premolar Teeth by Angulation*

A significant difference was observed between age and treatment option ($P < .001$). In the comparison between the groups, it was determined that the patients who underwent extraction according to the Dunn Post-hoc test were significantly older than the patients who underwent orthodontic procedures ($P < .001$). All invasive treatment applications were performed under local anesthesia with intraoral approaches.

Discussion

Impacted teeth usually follow an asymptomatic clinical course. Therefore, fewer patients seek treatment than the current population. In most cases, impacted teeth are noticed during routine clinical or radiological examinations. Consequently, it is essential to inform patients about this phenomenon, frequently observed in daily clinical practice, and to emphasize early diagnosis-treatment planning.[9]

The distribution of impacted premolars in the current study revealed that the most impacted teeth out of 108 impacted premolars are mandibular second premolars (68 teeth), maxillary second premolars (27 teeth), mandibular first premolars (8 teeth), and maxillary first premolars (5 teeth). The results are consistent with the study of Şimşek-Kaya et al.[11] This result suggests that the incidence of impaction between premolar teeth is highest in mandibular second premolars. Maxillary second premolars follow mandibular second premolars. Later eruption of mandibular and maxillary second premolars than the first premolars may be effective at the higher incidence of impaction.[15,16]

When the depth classifications and angulations of the impacted premolar teeth were evaluated, 44 teeth (28 females, 16 males) were at the level of class 1, 58 teeth were at the level of class 2 (31 females, 27 males), and six teeth were at the level of class 3 (4 females, 2 males). Also, regarding the results of the current study, the most impacted premolars were observed in the vertical position, as reported by Şimşek-Kaya et al.[11]

The most common complications associated with untreated impacted teeth in the current literature are retention of primary teeth, migration of adjacent teeth, pathologies of odontogenic origin, root resorption in adjacent teeth, alveolar bone loss, ankylosis, orthodontic disorders, pain, infected cysts, and odontogenic tumors.[2,9] Likewise, of the 108 impacted teeth included in the study, 23 (21.29%) were associated with dentigerous cysts, odontomas, root resorption in the adjacent teeth, and persistent primary teeth, as indicated in previous studies.[11]

Treatment applications for impacted premolar teeth were grouped under three options: surgical extraction, orthodontic traction, and follow-up. The outcomes revealed that 95 impacted premolars, 4 primary and 2 permanent teeth with root resorption were surgically extracted. Surgical exposure with orthodontic traction was performed in 10 patients, clinical and radiological follow-ups were performed in 3 patients. Although spontaneous

eruption of the impacted tooth is observed in appropriate cases after the surgical exposure of impacted teeth, orthodontic traction provides more precise results, especially in deep impactions with angulation. Various studies on the eruption tendency of impacted third molars have supported the conclusion that the planned extractions of premolars positively affect the proper eruption of third molars.[17,18] However, in another study, it was mentioned that the alterations in the angulation of the impacted third molars progressed independently of the extractions of premolars and that even premolar extractions for this purpose caused further occlusion problems.[19] In the current study, premolar extractions were performed only with indications for the treatment of impacted premolar teeth.

In the current study, dentigerous cysts accompanied 13 of 95 impacted premolars that underwent surgical extraction. In the treatment of dentigerous cysts, the excision of the follicular origin lesion and the extraction of the related impacted tooth is performed to prevent the recurrence of the cystic lesions. In some impacted teeth that are aesthetically and functionally essential, excision of the cystic lesion and orthodontic traction of the impacted tooth can also be considered. Apart from this, a similar treatment approach was adopted in 4 odontomas associated with impacted premolars. Also, surgical extractions of 2 impacted premolars, which caused root resorption in the adjacent teeth, were performed with the affected permanent teeth.

Factors such as the need for extraoral approaches, a large amount of alveolar bone loss, and the risk of damage to adjacent teeth or anatomical structures (inferior alveolar nerve, mental nerve, nasal floor, and maxillary sinus, e.g.) in the extraction of impacted premolars affect the surgical difficulty and the clinical decision to be made. In particular, the extraoral approach risks functional problems such as facial nerve damage and cosmetic problems such as scar tissue on the skin.[20] As a result, regular follow-up of impacted teeth, predominantly asymptomatic and not associated with any pathology, can provide more positive results with clinical profit-loss assessment. In this context, it was decided to observe 3 impacted premolars with regular clinical and radiological follow-ups in the current study.

Limitations

The use of panoramic radiographs without three-dimensional imaging may have restricted the precise assessment of impacted premolars and associated pathologies.

Conclusion

To conclude, mandibular and maxillary second premolars tend to be impacted at a higher rate than first premolars. The outcomes of the current study indicated that clinical and radiological follow-up is an acceptable alternative in the absence of pathologies of odontogenic origin, mainly in premolar teeth with deep impaction or in close relation with vital structures. In the presence of associated pathologies, radical treatments such as surgical extraction can be prioritized. Orthodontic treatment procedures can be applied especially in cases such as with a depth of class 1, where the amount of impaction is nominal and severe angulation is not observed.

Declarations

Animal and Human Rights Statement

All procedures performed in this study were in accordance with the ethical standards of the institutional and/or national research committee and with the 1964 Helsinki Declaration and its later amendments or comparable ethical standards.

Informed Consent

Informed consent was waived due to the retrospective nature of the study.

Data Availability

The datasets used and/or analyzed during the current study are not publicly available due to patient privacy reasons but are available from the corresponding author on reasonable request.

Conflict of Interest

The authors declare that there is no conflict of interest.

Funding

None.

Abbreviations

CBCT: Cone-beam computed tomography
CEJ: Cementoenamel junction
CT: Computed tomography
SPSS: Statistical package for the social sciences

References

1. *Al-Zoubi H, Alharbi AA, Ferguson DJ, Zafar MS. Frequency of impacted teeth and categorization of impacted canines: a retrospective radiographic study using orthopantomograms. Eur J Dent. 2017;11(1):117-121. doi:10.4103/ejd.ejd_308_16*

2. *Sarica I, Derindag G, Kurtuldu E, Naralan ME, Caglayan F. A retrospective study: do all impacted teeth cause pathology? Niger J Clin Pract. 2019;22(4):527-533. doi:10.4103/njcp.njcp_563_18*

3. *Damlar İ, Altan A, Tatli U, Arpağ OF. Hatay bölgesinde gömülü diş prevalansının retrospektif olarak incelenmesi. Cukurova Med J. 2014;39(3):559-565. doi:10.17826/cutf.03288*

4. *Gisakis IG, Palamidakis FD, Farmakis ETR, Kamberos G, Kamberos S. Prevalence of impacted teeth in a Greek population. J Investig Clin Dent. 2011;2(2):102-109. doi:10.1111/j.2041-1626.2010.00041.x*

5. *Hou R, Kong L, Ao J, et al. Investigation of impacted permanent teeth except the third molar in Chinese patients through an X-ray study. J Oral Maxillofac Surg. 2010;68(4):762-767. doi:10.1016/j.joms.2009.04.137*

6. *Alqerban A, Jacobs R, Fieuws S, Willems G. Comparison of two cone-beam computed tomographic systems versus panoramic imaging for localization of impacted maxillary canines and detection of root resorption. Eur J Orthod. 2011;33(1):93-102. doi:10.1093/ejo/cjq034*

7. *Haney E, Gansky SA, Lee JS, et al. Comparative analysis of traditional radiographs and cone-beam computed tomography volumetric images in the diagnosis and treatment planning of maxillary impacted canines. Am J Orthod Dentofacial Orthop. 2010;137(5):590-597. doi:10.1016/j.ajodo.2008.06.035*

8. *Hashemipour MA, Tahmasbi-Arashlow M, Fahimi-Hanzaei F. Incidence of impacted mandibular and maxillary third molars: a radiographic study in a Southeast Iran population. Med Oral Patol Oral Cir Bucal. 2013;18(1):e140-e145.*

9. *Kaczor-Urbanowicz K, Zadurska M, Czochrowska E. Impacted teeth: an interdisciplinary perspective. Adv Clin Exp Med. 2016;25(3):575-585. doi:10.17219/acem/37451*

10. *Santos KK, Lages FS, Maciel CAB, Glória JCR, Douglas-de-Oliveira DW. Prevalence of mandibular third molars according to the Pell & Gregory and Winter classifications. J Maxillofac Oral Surg. 2022;21(2):627-633. doi:10.1007/s12663-020-01473-1*

11. *Şimşek-Kaya G, Melih-Ömezli M, Yapici G, Dayi E, Ertaş U. Prevalence of impacted premolars in a Turkish population and considerations for surgical treatment. Med Oral Patol Oral Cir Bucal. 2011;16(6):e781-e786.*

12. *Abdelrahman A, Mahon N, Devahi L, Pearce C. Custom-made drill guides to access impacted mandibular premolars. Br J Oral Maxillofac Surg. 2020;58(1):114-115. doi:10.1016/j.bjoms.2019.07.029*

13. *An S, Manjunatha BS, Astekar M, Sameer C. Dentigerous cyst associated with ectopically impacted maxillary second premolar. J Exp Ther Oncol. 2016;11(4):309-313.*

14. *Ahuja VR, Jayanna R, Ahuja A, Patel S. Impacted mandibular premolar concomitant with compound-complex odontome in a 13-year-old girl: a case report. Int J Clin Pediatr Dent. 2020;13(6):729-733.*

15. *Bayrak S, Sen Tunc E, Tuloglu N, Acikgoz A. Timing of permanent teeth eruption in Turkish children. J Clin Pediatr Dent. 2012;37(2):207-211. doi:10.17796/jcpd.37.2.8v072017534j0191*

16. *Fekonja A. Evaluation of the eruption of permanent teeth and their association with malocclusion. Clin Exp Dent Res. 2022;8(4):836-842. doi:10.1002/cre2.544*

17. *Jain S, Valiathan A. Influence of first premolar extraction on mandibular third molar angulation. Angle Orthod. 2009;79(6):1143-1148. doi:10.2319/100708-525r.1*

18. *Kim TW, Artun J, Behbehani F, Artese F. Prevalence of third molar impaction in orthodontic patients treated nonextraction and with extraction of 4 premolars. Am J Orthod Dentofacial Orthop. 2003;123(2):138-145. doi:10.1067/mod.2003.13*

19. *Tarazona B, Paredes V, Llamas JM, Cibrian R, Gandía JL. Influence of first and second premolar extraction or nonextraction treatments on mandibular third molar angulation and position: a comparative study. Med Oral Patol Oral Cir Bucal. 2010;15(5):e760-e766. doi:10.4317/medoral.15.e760*

20. *Infante-Cossio P, Hernandez-Guisado JM, Gutierrez-Perez JL. Removal of a premolar with extreme distal migration by sagittal osteotomy of the mandibular ramus: report of case. J Oral Maxillofac Surg. 2000;58(5):575-577. doi:10.1016/s0278-2391(00)90026-0*

How to Cite

Sefa Çolak, Aras Erdil, Ahmet Altan. Evaluation of clinical and radiographic features of impacted premolar teeth in the central black sea region. Ann Clin Anal Med 2023;14(5):459-463. doi:10.4328/ACAM.21620