This work is licensed under a Creative Commons Attribution-NonCommercial 4.0 International License (CC BY-NC 4.0). To view a copy of the license, visit **https://creativecommons.org/licenses/by-nc/4.0/**

Annals of Clinical and Analytical Medicine

Case Report

Intraoperative nerve stimulation for lesion localization in pediatric traumatic facial paralysis: A Case Report

Acute Traumatic Facial Paralysis

Bülent Ulusoy[1]

[1]Department of Otorhinolaryngology-Head and Neck Surgery, Faculty of Medicine, Selçuk University, Konya, Türkiye.

Abstract

Introduction: This case report aimed to describe the use of intraoperative nerve stimulation for identifying the suspected site of nerve injury in patients with acute traumatic peripheral facial paralysis (PFP). Although intraoperative facial nerve stimulation has been described in other clinical settings, its potential role in localizing the site of nerve injury during surgery for acute traumatic facial paralysis has not been well established.

Case Presentation: This case report describes two pediatric patients who presented with acute-onset complete PFP. Intraoperative facial nerve stimulation was performed sequentially along the nerve's course. Localization of the suspected injured segment was based on the absence of a stimulation response in the affected area, while responses remained intact distal to the suspected lesion. In both cases, intraoperative stimulation enabled identification of the suspected site of nerve injury.

Conclusion: The findings enabled targeted and limited decompression of the facial nerve.

Keywords

facial paralysis, peripheral, temporal bone, trauma, diagnose

DOI: 10.4328/ACAM.22837 Ann Clin Anal Med 2026;17(12):1369-1372
Received: 31.07.2025 Accepted: 31.08.2025 Published Online: 07.09.2025 Printed: 01.12.2026
Corresponding Author: Bülent Ulusoy, Department of Otorhinolaryngology-Head and Neck Surgery, Faculty of Medicine, Selçuk University, Konya, Türkiye.
Email: ulusoybulent@hotmail.com **P.:** +90 506 509 78 93
Corresponding Author ORCID: https://orcid.org/0000-0001-7643-7100

Introduction

Traumatic facial nerve paralysis (FNP) is a complex condition that requires a multidisciplinary approach for accurate diagnosis and management.[1,2] It occurs in 7-10% of patients with temporal bone fractures.[3] However, the indications and timing for surgical intervention in cases of FNP caused by temporal bone fractures remain controversial.[4] Traumatic FNP is classified as early or late based on the onset of paralysis after injury; paralysis developing within 24 to 72 hours is considered the acute form.[1,3] There is no consensus regarding treatment when a displaced fracture line in the facial nerve canal is not observed. In this situation, the physician's clinical experience and the patient's or their parents' choices (once they are informed about the process) are generally significant.

Facial nerve integrity monitoring is routinely employed by many surgeons during otologic procedures to ensure intraoperative nerve preservation. To our knowledge, clinical evidence regarding this application of intraoperative nerve stimulation in acute traumatic peripheral facial paralysis is limited. In this case report, we describe the use of intraoperative nerve stimulation for identifying the suspected site of nerve injury in two pediatric patients with acute traumatic peripheral facial paralysis.

Case Presentation

Case 1

A 9-year-old boy presented with left-sided acute complete peripheral FNP (House-Brackmann (HB) grade VI) following blunt trauma to his head while he was playing football with his friends (Figure 1A).

Otoscopic examination revealed marginal perforation of the tympanic membrane in the anterosuperior quadrant. High-resolution CT (HRCT) of the temporal bone identified a nondisplaced fracture extending to the geniculate ganglion (GG) (Figure 2). Surgical decompression was elected without waiting for electroneuronography (ENoG), based on the acute onset and severity of paralysis.

Intraoperatively, after canal wall up tympanomastoidectomy and posterior tympanotomy, each facial nerve segment was stimulated, starting from the GG level and proceeding distally, with 0.8 mA using a monopolar stimulator probe (NIM-Response® 3.0 Medtronic Xomed Inc., Jacksonville, FL 32216-0980 USA). The presence of visible facial muscle contraction and/or electromyography (EMG) waveform was accepted as an indicator of functional nerve conduction. Nerve stimulation was not seen in the GG and tympanic segments, while nerve stimulation was seen in the second genu and the proximal part of the mastoid segment. After decompression of the fallopian canal at the geniculate ganglion and tympanic segments, the Nerve Integrity Monitor (NIM) findings were reassessed. The perineurium was edematous in the tympanic and GG segments. As a result, decompression was completed by making an incision in the perineurium only in these two segments. This approach allowed decompression to be limited to the suspected injured segments.

The patient was followed up with monthly EMG in the postoperative period, and complete functional recovery (HB grade I) was achieved in the fifth month (Figure 1B).



A B

Figure 1. *A: Preoperative Left House-Brackmann Stage VI Acute Peripheral Facial Paralysis*

B: Full Recovery was Observed in the Postoperative 5th Month (Case 1)

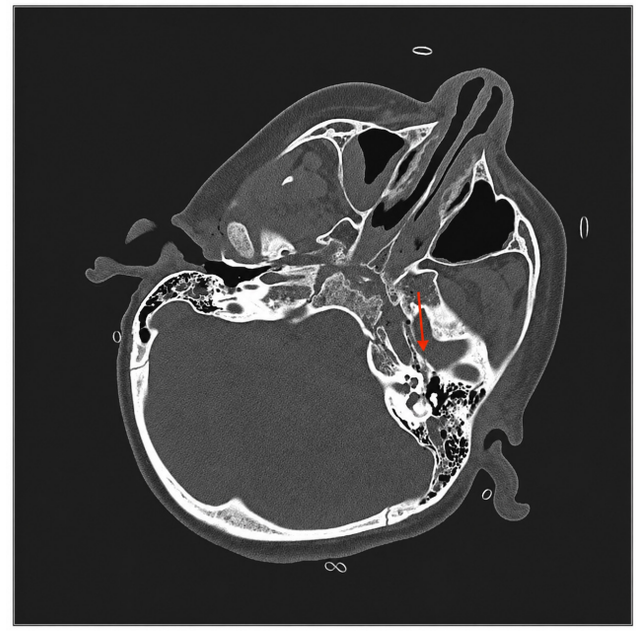

Figure 2. *Temporal Bone HRCT Demonstrates a Fracture Line (Red Arrow)*

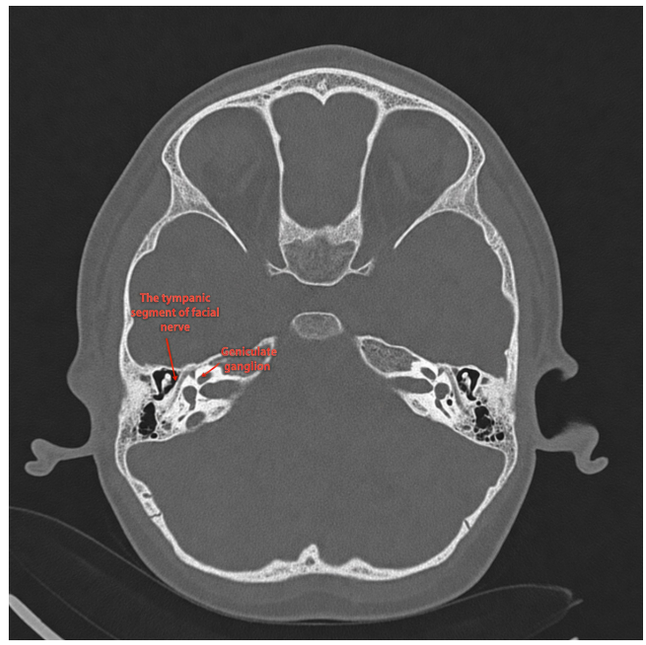

Figure 3. *The Fallopian Canal is Observed to be Normal at the Level of the Geniculate Ganglion and Tympanic Segment in the Temporal Bone CT*

Case 2

A 3-year-old male patient presented with right-sided acute complete peripheral facial paralysis (HB grade VI) after striking his head on a stove while running. HRCT revealed no apparent fractures involving the facial nerve canal (Figure 3).

Due to the acute complete peripheral facial paralysis following trauma, and the patient's presentation within the first six hours, a decision was made to perform facial nerve decompression without awaiting ENoG. Intraoperatively, a longitudinal fracture line was observed along the epitympanum, perpendicular to the GG, and a second fracture line was noted parallel to the tympanic segment of the fallopian canal. Using the same stimulation protocol as in Case 1, no evoked response was detected in the first three segments, while a positive response was recorded distal to the second genu.

Facial nerve decompression was performed from the GG to 2 mm distal to the second genu. At this stage, the NIM findings were reassessed by repeating the stimulation, with no response elicited from the previously non-responsive segments. Based on these intraoperative findings, decompression was limited to the suspected injured segments without extending further into the mastoid segment. After identification of the suspected injured segment, an incision was made in the perineurium. The patient was followed up with monthly EMG, and a complete functional recovery (HB grade I) was achieved in the 6th month.

Ethical Approval

Ethical approval was obtained from the Ethics Committee of XXXX University (2025-02-25, No:2025/125).

This case report was prepared in accordance with the CARE (Case Report) guidelines.

Discussion

The key finding of this report is that intraoperative nerve stimulation may have potential utility for identifying the suspected site of nerve injury in patients with acute traumatic peripheral facial paralysis. In these two cases, the intraoperative stimulation findings were used to guide the extent of facial nerve decompression.

Emergency surgical intervention is generally recommended for cases of acute complete FNP secondary to trauma, whereas delayed-onset cases are usually managed conservatively.[3] Hato et al. reported a 92.9% recovery rate to HB grade I or II following decompression within two weeks in patients with severe acute traumatic FNP.[3] The standard criteria for surgical intervention include onset of paralysis within 14 days, greater than 90% degeneration on ENoG, and absent activity on EMG.[2,3]

Trauma may lead to perineural edema, vascular congestion, partial or complete rupture, and degeneration of the facial nerve.[2] In such cases, surgical decisions regarding the extent of decompression and the need for nerve repair depended on subjective microscopic evaluations of the facial nerve during exploration, which do not entirely reflect the physiological status of the nerve fibers.[4] Therefore, more specific criteria are needed to guide clinical decision-making.[4] Furthermore, appropriate localization of the injured nerve segment is an important consideration in facial nerve decompression.[5]

Modern diagnostic tools, such as HRCT of the temporal bone and advanced electrophysiological tests, are employed to plan the appropriate treatment strategy.[4] Electrophysiological tests play an essential role in demonstrating the degree of nerve damage and the stages of nerve degeneration and regeneration.[1] ENoG, nerve excitatory test (NET), and maximal stimulation test (MST) may be used to evaluate acute complete paralysis while the nerve is in the degeneration phase. These tests provide accurate information in the first 3 weeks and are not used in the first three days because Wallerian degeneration has not yet reached the stylomastoid foramen.[1] EMG plays a supportive role within the first 14 days following the onset of acute paralysis and is particularly valuable for assessing chronic paralysis after the third week.[1]

Due to the inability to perform electrophysiological tests like ENoG within the first 72 hours, deferring intervention during this time may lead to missing the crucial therapeutic window in cases of actual nerve injury. In such cases, many clinicians make decisions based on HRCT findings of the temporal bone and carry out decompression if a displaced fracture is identified along the course of the facial nerve.

As part of standard practice in many otologic procedures, intraoperative facial nerve monitoring is routinely employed. However, the use of a nerve integrity monitor is not routine in patients with facial nerve paralysis. We routinely use facial nerve monitoring in patients undergoing facial nerve decompression. In a case of acute traumatic complete peripheral FNP, we decided to perform decompression following the family's informed consent. Intraoperative findings in this case prompted us to explore the potential use of sequential nerve stimulation for lesion localization. Considering that Wallerian degeneration takes approximately 72 hours to reach the stylomastoid foramen, we hypothesized that early intraoperative nerve stimulation might provide information regarding the suspected site of nerve injury.

Using a monopolar stimulator probe, we stimulated the facial nerve sequentially from the GG distally. In the first patient, no evoked response was detected in the GG and tympanic segments, whereas positive responses were obtained in the second genu and proximal mastoid segments (Case 1). The same method was also applied in a second case, yielding similar intraoperative stimulation findings in the early period of complete traumatic FNP (Case 2).

Although intraoperative facial nerve stimulation is commonly used in neurotologic surgeries, including cerebellopontine angle surgery and tympanomastoidectomy, clinical evidence regarding its use for lesion localization in traumatic facial paralysis remains limited. Gantz et al. previously described intraoperative evoked electromyography for lesion localization in Bell's palsy.[5,6] The present cases provide preliminary clinical observations regarding the potential utility of this approach in acute traumatic peripheral facial paralysis.

Limitations

This case report has several limitations, most notably the inclusion of only two patients. Therefore, these observations cannot establish the diagnostic accuracy, reliability, or reproducibility of the technique. Larger prospective multicenter studies are needed to evaluate its diagnostic performance, clinical utility, and reproducibility.

Conclusion

This case report suggests that intraoperative nerve stimulation may have potential utility for identifying the suspected site of nerve injury in acute complete traumatic peripheral facial paralysis. In these two cases, the intraoperative stimulation findings were used to guide the extent of facial nerve decompression. This approach may allow decompression to be limited to the suspected injured segments and may provide additional intraoperative information

when gross nerve continuity is preserved despite suspected axonal injury. However, these observations are based on only two cases, and larger prospective multicenter studies are needed to evaluate the diagnostic performance, clinical utility, and reproducibility of this approach.

Declarations

Animal and Human Rights Statement

All procedures performed in studies involving human participants were in accordance with the ethical standards of the institutional and/or national research committee and with the 1964 Helsinki Declaration and its later amendments or comparable ethical standards.

Informed Consent

Written informed consent for the surgical procedures was obtained from the patients' parents/legal guardians. Written informed consent was also obtained from the parents/legal guardians for publication of the clinical information and accompanying images.

Data Availability

The data supporting the findings of this case report are not publicly available because they contain potentially identifiable clinical information concerning paediatric patients. Any requests for additional information will be considered by the corresponding author in accordance with applicable ethical and privacy requirements.

Conflict of Interest

There is no conflict of interest in this case report.

Funding

No financial support was received for this study.

Author Contributions (CRediT Taxonomy)

Conceptualization: B.U.
Methodology: B.U.
Investigation: B.U.
Resources: B.U.
Data Curation: B.U.
Writing – Original Draft Preparation: B.U.
Writing – Review & Editing: B.U.
Visualization: B.U.
Supervision: B.U.

AI Usage Disclosure

The authors declare that no AI-assisted technologies were used.

Abbreviations

CT: Computed tomography
EMG: Electromyography
ENoG: Electroneuronography
FNP: Facial nerve paralysis
GG: Geniculate ganglion
HB: House-brackmann
HRCT: High-resolution computed tomography
NIM: Nerve integrity monitor
PFP: Peripheral facial paralysis

References

1. *Ziai K, Daher GS, Henry CR, Lighthall JG. Evaluation and surgical decision making in facial paralysis. Oper Tech Otolaryngol Head Neck Surg. 2021;32(4):205-212. doi:10.1016/j.otot.2021.10.011*

2. *Andresen NS, Sun DQ, Hansen MR. Facial nerve decompression. Curr Opin Otolaryngol Head Neck Surg. 2018;26(5):280-285. doi:10.1097/moo.0000000000000478*

3. *Hato N, Nota J, Hakuba N, Gyo K, Yanagihara N. Facial nerve decompression surgery in patients with temporal bone trauma: analysis of 66 cases. J Trauma. 2011;71(6):1789-1792. doi:10.1097/ta.0b013e318236b21f*

4. *Ashram YA, Badr-El-Dine MM. Surgery for traumatic facial nerve paralysis: does intraoperative monitoring have a role? Eur Arch Otorhinolaryngol. 2014;271(9):2365-2374. doi:10.1007/s00405-013-2712-9*

5. *Gantz BJ. Intraoperative facial nerve monitoring. Am J Otol. 1985;Suppl:58-61.*

6. *Gantz BJ, Gmur A, Fisch U. Intraoperative evoked electromyography in Bell's palsy. Am J Otolaryngol. 1982;3(4):273-278. doi:10.1016/s0196-0709(82)80066-5*

How to Cite

Bülent Ulusoy. Intraoperative nerve stimulation for lesion localization in pediatric traumatic facial paralysis: A Case Report. Ann Clin Anal Med 2026;17(12):1369-1372. Article in Press. doi:10.4328/ACAM.22837