This work is licensed under a Creative Commons Attribution-NonCommercial 4.0 International License (CC BY-NC 4.0). To view a copy of the license, visit **https://creativecommons.org/licenses/by-nc/4.0/**

Annals of Clinical and Analytical Medicine
Original Research

Examining the efficacy of hypericum perforatum oil in acetic acid-induced colitis

Hypericum perforatum in acetic acid colitis

İshak Aydın[1] Uğur Topal[1] Serdar Gümüş[1] Ali Yıldırım[1] Burak Yavuz[2] Ahmet Rencüzoğulları[2] Atılgan Tolga Akçam[1] Kıvılcım Eren Erdoğan[3] Sevinç Püren Yücel[4] Halil Mahir Kaplan[5] İsmail Cem Eray[1]

[1]Department of General Surgery, Çukurova University Faculty of Medicine, Adana, Türkiye.
[2]Department of General Surgery, Koç University Faculty of Medicine, İstanbul, Türkiye.
[3]Department of Pathology, Çukurova University Faculty of Medicine, Adana, Türkiye.
[4]Department of Biostatistics, Çukurova University Faculty of Medicine, Adana, Türkiye.
[5]Department of Medical Pharmacology, Çukurova University Faculty of Medicine, Adana, Türkiye.

Abstract

Aim: This study aimed to examine the efficacy of Hypericum perforatum oil in a rat model of acetic acid-induced colitis.

Methods: Twenty-four female Wistar albino rats were randomized into four groups (n = 6): Control, Colitis (acetic acid), Hypericum perforatum oil, and Olive oil. Colitis was induced by intrarectal administration of 1 cc of 4% acetic acid. Treatment groups received 1 cc of 20% Hypericum perforatum oil or extra virgin olive oil intrarectally on day 3. On day 5, animals were sacrificed, and colon tissue and blood samples were collected. Inflammatory markers (TNF-α, IL-6), oxidative stress markers (malondialdehyde [MDA], myeloperoxidase [MPO], superoxide dismutase [SOD], catalase, glutathione peroxidase [GPx]), and apoptosis markers (bax, bcl-2, caspase-3) were measured by ELISA. Macroscopic and histological scoring were performed.

Results: Hypericum perforatum oil significantly reduced TNF-α, IL-6, MDA, bax, and caspase-3 levels compared to the colitis group ($P < .001$ for all). SOD, catalase, GPx, and bcl-2 levels were significantly increased in the Hypericum perforatum group ($P < .001$). Weight loss was significantly lower in the Hypericum perforatum group than in the colitis group ($P = .014$). Histological scores were significantly improved ($P < .001$).

Conclusion: Rectal administration of Hypericum perforatum oil demonstrated anti-inflammatory, antioxidant, and anti-apoptotic effects in an experimental acetic acid-induced colitis model, suggesting a potential therapeutic role for this agent in inflammatory bowel disease.

Keywords

hypericum perforatum, acetic acid-induced colitis, inflammatory bowel disease, oxidative stress, apoptosis

DOI: 10.4328/ACAM.50063 Ann Clin Anal Med 2026;17(12):1329-1333
Received: 04.02.2026 Accepted: 17.04.2026 Published Online: 17.04.2026 Printed: 01.12.2026
Corresponding Author: Ali Yıldırım, Department of General Surgery, Çukurova University Faculty of Medicine, Adana, Türkiye.
Email: aliyildirim@cu.edu.tr **P.:** +90 322 338 60 60
Corresponding Author ORCID: https://orcid.org/0000-0002-4789-9805
Other Authors ORCID: İshak Aydın, https://orcid.org/0000-0002-6366-2461 • Uğur Topal, https://orcid.org/0000-0003-1305-2056 • Serdar Gümüş, https://orcid.org/0000-0001-7629-9369 • Burak Yavuz, https://orcid.org/0000-0002-5262-0346 • Ahmet Rencüzoğulları, https://orcid.org/0000-0002-5993-9536 • Atılgan Tolga Akçam, https://orcid.org/0000-0001-7525-3107 • Kıvılcım Eren Erdoğan, https://orcid.org/0000-0002-4951-8703 • Sevinç Püren Yücel, https://orcid.org/0000-0002-5768-3549 • Halil Mahir Kaplan, https://orcid.org/0000-0002-1911-7327 • İsmail Cem Eray, https://orcid.org/0000-0002-1560-7740

Introduction

Inflammatory bowel disease (ulcerative colitis and Crohn's disease) is a group of disorders with a very heterogeneous clinical course, which is characterized by inflammation.[1]

Many factors, such as neutrophil infiltration and overproduction of proinflammatory mediators like cytokines and arachidonic acid metabolites, have been reported in the pathogenesis of inflammatory bowel disease (IBD). Genetic and immunological studies have tried to clarify the role of environmental factors, host factors, and genetics in pathogenesis.[2,3] However, the etiopathogenesis has not been fully elucidated, which has led to the advancement of treatments through anti-inflammatory mechanisms.

Various substances have been used as therapeutic agents in experimental colitis models, and Hypericum perforatum oil is one of them. Although many agents are used in various ways in treatment, it is not clear by which mechanisms they produce treatment effects. However, information on the efficacy of St. John's Wort (Hypericum Perforatum L.) in the experimental colitis model is limited. Hypericum perforatum application by the rectal route has not been tried before, and our study is the first to try this method. St. John's Wort (Hypericum L.) is found on every continent except Antarctica and shows various effects through its ingredients. It has antidepressant, antimicrobial, antiviral, anti-cancer, wound-healing, and anti-inflammatory effects. Its most known active ingredients are hyperforin and hypericin.[4-7]

The present study aimed to examine the efficacy of Hypericum perforatum oil in a rat model of acetic acid-induced colitis in light of the literature.

Materials and Methods

The study was started after being approved by the local ethics committee. The experiment was conducted in accordance with Directive 2010/63/EU of the European Parliament, ensuring compliance with ethical standards and animal welfare regulations. The Hypericum perforatum (St. John's Wort) plant used in this study is not classified as a protected or endangered species according to the International Union for Conservation of Nature (IUCN) or local Turkish conservation lists. The plant material used in the study was commercially obtained from a certified supplier and not collected from the wild.

Humane endpoints were established to minimize animal suffering. Animals were monitored daily for signs of pain, distress, or moribund condition, including but not limited to significant weight loss (>20%), abnormal posture, immobility, piloerection, or decreased food and water intake. Any animal exhibiting severe distress was scheduled for humane euthanasia via cervical dislocation under appropriate anesthesia, as approved by the institutional ethics committee.

In the experiments, 24 female Wistar albino rats with average weights of 160–220 grams were used, which were provided by an accredited experimental research center. During the experiment, the light schedule was set to 12 hours a day and 12 hours a night. Rats were individually placed in cages and housed at approximately 21 °C room temperature. Throughout the research, they were fed with rested tap water and standard pellet food. The rats were randomized and divided into 4 equal groups in accordance with power analysis (n = 6):

Induction of Colitis

Rectal 1 cc of 4% acetic acid was slowly administered to the rats, followed by 1 cc of air via a 6 French polyurethane cannula introduced 1 cm into the rectum, and the rats were held upside down by the tail for 30 seconds. The subjects were then placed in their numbered cages.

Group 1 (Control): Given 1 cc of 0.9% NaCl intrarectally (IR) and 1 cc of air.

Group 2 (Colitis): Given 1 cc of 4% acetic acid via IR followed by 1 cc of air.

Group 3 (Hypericum Perforatum Oil): Given 1 cc of 4% acetic acid via IR, followed by 1 cc of air. Three days later, 1 cc of 20% Hypericum perforatum oil (in extra virgin olive oil) was administered via anal canal, followed by 1 cc of air using a 6 French polyurethane cannula while in the supine position.

Group 4 (Olive Oil): Given 1 cc of 4% acetic acid via IR, followed by 1 cc of air. On the third day, 1 cc extra virgin olive oil was administered via the anal canal, followed by 1 cc of air using a 6 French polyurethane cannula while in the supine position.

Before the experiment, rats were weighed, and their weights were recorded. On day 5, rats were weighed again after anesthesia was induced by intramuscular injection of ketamine hydrochloride (50 mg/kg) and xylazine hydrochloride (5 mg/kg). Intracardiac blood (1–2 cc) was collected, and rats were sacrificed by cervical dislocation. The left colon and rectum were removed via median laparotomy, and stool samples were collected and checked for fecal occult blood. Half of the colon and rectum were fixed in formaldehyde, while the other half was stored in liquid nitrogen and frozen at -20 °C.

Macroscopic and Histological Assessment

Tissue samples were fixed in 10% formaldehyde solution and examined macroscopically in the pathology department. The tissues were then divided into 0.5 cm pieces, embedded in paraffin,

Table 1. Criteria For Macroscopic Scoring Of Colonic Mucosa[8]

Colitis score	Macroscopic morphology
0	No macroscopic changes
1	Mucosal erythema only
2	Mild mucosal edema, superficial bleeding, or small erosions
3	Moderate edema, bleeding ulcers, or erosions
4	Severe ulceration, erosions, edema

Table 2. Histological Damage Scoring[8]

Score/criterion	0	1	2
Acute inflammatory cell infiltration	Absent	Mild	Severe
Chronic inflammatory cell infiltration	Absent	Mild	Severe
Fibrin deposition	Negative	Positive	
Submucosal edema	Absent	Focal	Diffuse
Epithelial necrosis	Absent	Focal	Diffuse
Mucosal ulcer	Negative	Positive	

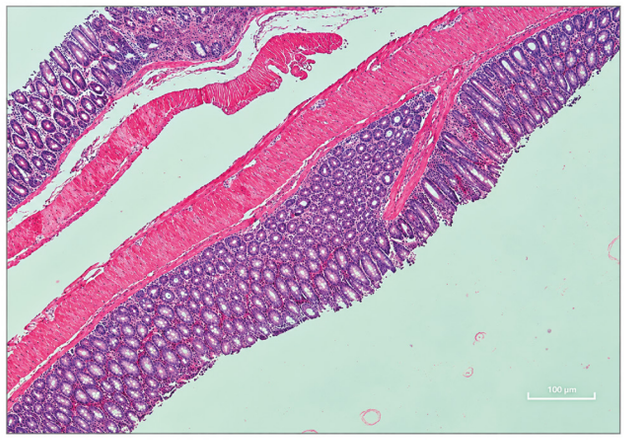

Figure 1. *Colitis Group Rat Colon Histological Image*

Ulceration in the intestinal tissue, necrosis in the epithelium, acute and chronic inflammatory cells, submucosal edema, fibrin deposition in the vessel walls are observed (×40 magnification, H&E staining)

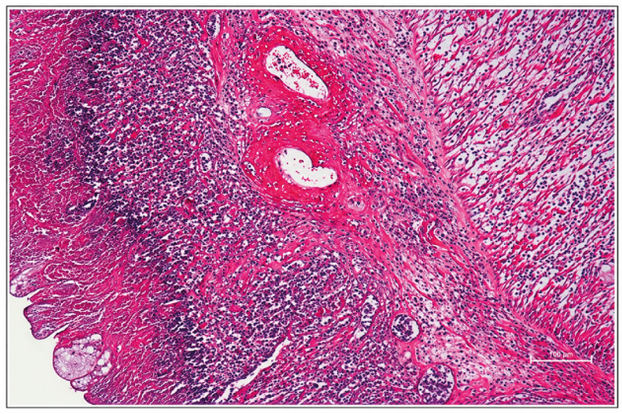

Figure 2. *St. John's Wort Group Rat Colon Histological Image*

The mucosa appears smooth; edema and inflammatory cells are observed in the submucosa (×40 magnification, H&E staining)

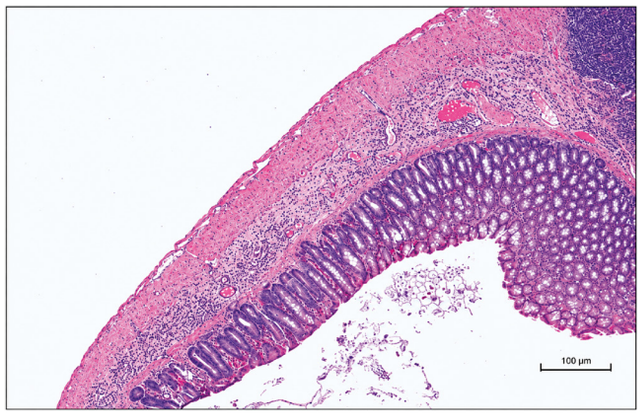

Figure 3. *Olive Oil Group Rat Colon Histological Image*

Surface ulceration with complete epithelial necrosis is observed. Widespread inflammatory cells, fibrin around vessels, and submucosal edema are noted (×100 magnification, H&E staining)

and sectioned into 5-micron sections. These sections were stained with hematoxylin-eosin and examined under a microscope (Figure 1, Figure 2 and Figure 3). A blinded pathologist performed macroscopic and histological examination of the most inflamed segments of colon, and the results were evaluated using scoring systems in Table 1 and Table 2.[8]

Biochemical and Tissue Examination

To determine inflammation, oxidative damage, and apoptosis rates, TNF-α and IL-6 levels, myeloperoxidase (MPO), superoxide dismutase (SOD), catalase, malondialdehyde (MDA), glutathione peroxidase (GPx), caspase-3, bax, and bcl-2 were examined in blood and tissue samples collected from the rats. Blood samples were collected via intracardiac puncture and stored in ethylenediaminetetraacetic acid (EDTA) tubes, while tissue samples were placed in Eppendorf tubes with RIPA buffer and stored at -20 °C. ELISA tests were performed on the tissue samples, which were homogenized with an ultrasonic disintegration device and centrifuged at 10,000 RPM for 10 minutes. The supernatants were used for the ELISA tests.

ELISA tests were performed using an ELISA microplate reader and washer obtained from Rayto. Catalase activity was analyzed using a CAT activity test kit (Cat. No. K773-100) purchased from BioVision. The kit used for MPO measurement was Myeloperoxidase Activity Colorimetric Assay Kit, BioVision, K744-100. MDA was analyzed using a spectrophotometric method based on the reaction of thiobarbituric acid (TBA). SOD assay was performed using the SOD Kit (Superoxide Dismutase Activity Assay Kit, BioVision, K335-100). The GPx assay was conducted using the GPx Kit (Glutathione Peroxidase Activity Colorimetric Assay Kit, BioVision, K762-100). TNF-α and IL-6 serum levels were measured using the immunoenzymatic ELISA method (Quantikine High Sensitivity Human by R&D Systems, Minneapolis, USA).

Ethical Approval

The study was approved by the Ethics Committee of Çukurova University Animal Experiments Local Ethics Committee (Date: 13.05.2020, Decision No: 2020-201197).

Statistical Analysis

Data were analyzed using IBM SPSS Statistics (Ver. 20.0). Categorical data were presented as counts and percentages, while quantitative data were presented as mean and standard deviation (or median and minimum-maximum values when necessary). The Shapiro-Wilk test was used to test for normality. The One-Way Analysis of Variance (ANOVA) was used for overall comparison of quantitative measurements between groups. Pairwise comparisons were made using the Bonferroni test (for homogeneous variances) or the Games-Howell test (for non-homogeneous variances). A significance level of 0.05 was used for all analyses.

Reporting Guidelines

This study is reported in accordance with the ARRIVE guidelines for animal research.

Results

Inflammatory Markers

In the acetic acid-induced colitis model, the rectal administration of Hypericum perforatum oil decreased TNF-α and IL-6 levels compared to the colitis group ($P < .001$; $P < .001$, respectively). The detailed data are provided in Supplementary Table 1.

Oxidative Damage Markers

In the acetic acid-induced colitis model, the rectal administration of Hypericum perforatum oil decreased MDA levels ($P = .006$) and increased SOD and catalase levels ($P < .001$; $P < .001$, respectively) compared to the colitis group. The detailed data are provided in Supplementary Table 1.

Apoptosis Markers

In the acetic acid-induced colitis model, the rectal administration of Hypericum perforatum oil decreased Bax and caspase-3 levels

($P < .001$ and $P < .001$, respectively) and increased bcl-2 levels ($P < .001$) compared to the colitis group.

Weight and Histological Score

The mean weights of the rats were similar in the groups on day 0 ($P = .161$). On day 5, the mean weights were also similar ($P = .583$). The percent weight loss in rats was statistically different between the groups ($P = .014$). Pairwise comparison revealed less weight loss in the Hypericum perforatum group than in the acetic acid group ($P < .05$). The mean histological assessment score was different between the groups ($P < .001$). The pairwise comparisons revealed a difference between the control and acetic acid groups, control and Hypericum perforatum groups, Hypericum perforatum and acetic acid groups, and control and olive oil groups ($P < .05$). The detailed data are provided in Supplementary Table 2.

Discussion

Inflammation and oxidative stress are believed to play key roles in the pathophysiology of IBD. External or internal stimulation induces the activation of inflammation, causing oxidative stress and activation of inflammatory cells.[9]

In experimental colitis models, disease activity index and weight loss are parameters that indicate colitis. In an experimental colitis model, Tanideh et al. reported weight loss in all groups except the control group.[10] Our study detected weight loss in all groups with acetic acid-induced colitis. The weight loss was less in the Hypericum perforatum group than in the colitis group, and the difference was statistically significant. It was demonstrated that Hypericum perforatum oil could reduce weight loss during acute inflammation in an experimental colitis model.

Wang G et al. reported increased MDA levels in the colitis group compared to the control group in their experimental colitis model.[11] Our study found lower MDA levels in the Hypericum perforatum group than in the colitis group. This suggests that Hypericum perforatum oil reduces MDA levels and may have a positive effect on tissue damage prevention.

MPO not only increases the damage in the tissue but also causes the formation of more radicals than necessary.[12] In an experimental colitis model, Osafo et al. found increased MPO levels in the colitis group compared to the control group.[13] Our study also established increased MPO levels in all groups with acetic acid-induced colitis. In our study, the comparison of MPO levels between the Hypericum perforatum and colitis groups revealed no positive effect of Hypericum perforatum oil on MPO levels.

In their experimental colitis model, Wang G et al. found the SOD level to be lower in the colitis group than in the control group.[11] Our study also found low SOD levels in all groups with acetic acid-induced colitis. The SOD level was higher in the Hypericum perforatum group than in the colitis group. This suggests that Hypericum perforatum oil increases SOD levels and may have a positive effect on tissue damage prevention.

In an experimental colitis model, Osafo et al. detected lower catalase levels in the colitis group than in the control group.[13] Our study also found low catalase levels in all groups with acetic acid-induced colitis. The catalase level was higher in the Hypericum perforatum group than in the colitis and olive oil groups. This suggests that Hypericum perforatum oil increases catalase levels and may have a positive effect on tissue damage prevention.

The levels of GPx increase during oxidative damage.[14,15] In an experimental colitis model, Xing J et al. found GPx levels to be lower in the colitis group than in the control group.[16] Our study showed that Hypericum perforatum oil and olive oil increased GPx levels and might have a positive effect on tissue damage prevention.

TNF-α and IL-6 are proinflammatory cytokines, and Sehirli AO et al. found higher TNF-α levels in the colitis group than in the control group in an experimental colitis model.[17] Rezayat et al. also detected higher TNF-α levels in the colitis group than in the control group in their experimental colitis model.[18] In another experimental colitis model, Wang G et al. found higher IL-6 levels in the colitis group than in the control group.11 The experimental colitis study by De Paula do Nascimento R et al. also found higher IL-6 levels in the colitis group than in the control group.[19] Our study showed that Hypericum perforatum oil reduced TNF-α and IL-6 levels and might have an anti-inflammatory effect.

Bax is a proapoptotic, and Bcl-2 is an antiapoptotic protein. In an experimental colitis model, Tang X et al. found higher Bax levels in the colitis group than in the control group.[20] In another experimental colitis model, Shen J et al. detected lower Bcl-2 levels in the colitis group than in the control group.[21] Our study showed that Hypericum perforatum oil increased the levels of Bcl-2 and decreased the levels of Bax, suggesting an anti-apoptotic effect.

Recent advances in experimental colitis models have underscored the importance of both systemic and localized anti-inflammatory strategies in managing intestinal injury. Talapka et al. developed a repetitive TNBS-induced colitis model that mimicked the chronic relapsing nature of Crohn's disease and demonstrated a protective preconditioning effect with reduced neuronal and mucosal damage upon repeated inflammation.[22] Complementing these findings, Cagin et al. investigated the effects of dexpanthenol in an acetic acid-induced colitis model and showed that systemic administration of the compound attenuated oxidative stress, improved histological parameters, and decreased apoptotic activity, highlighting the therapeutic potential of antioxidants in acute colitis.[23]

Our study contributes a novel dimension to this body of work by evaluating the rectal administration of Hypericum perforatum oil—an approach not previously reported in colitis models. We demonstrated that Hypericum perforatum significantly reduced inflammatory cytokines (TNF-α, IL-6), oxidative stress markers (MDA), and pro-apoptotic proteins (Bax, caspase-3), while upregulating antioxidant enzymes (SOD, catalase, GPx) and the anti-apoptotic marker Bcl-2. These effects were associated with less weight loss and improved histological scores compared to the colitis group. Unlike the systemic administration routes employed in prior studies, the local rectal delivery of Hypericum perforatum offers a promising therapeutic option with targeted mucosal effects and potentially reduced systemic exposure. Together with previous literature, our findings support the role of plant-derived agents in modulating multiple inflammatory and oxidative pathways in experimental colitis, and provide preliminary evidence for the efficacy of Hypericum perforatum oil when administered via the rectal route.

Limitations

This study has several limitations. First, the sample size per group was relatively small ($n = 6$), which may limit the statistical power of certain comparisons. Second, the short follow-up period of five days reflects the acute phase of colitis and does not allow for assessment of long-term effects. Third, the study was conducted in a single experimental colitis model; results may differ in other colitis models or in chronic disease settings. Finally, the optimal dose and administration schedule of Hypericum perforatum oil were not systematically evaluated, and further dose-response

studies are warranted.

Conclusion

It was demonstrated that Hypericum perforatum oil decreased the levels of inflammatory and oxidative damage markers and reduced apoptosis, which suggests a therapeutic effect in experimental colitis models. We believe that further clinical studies are needed regarding the effect of Hypericum perforatum on colitis.

Declarations

Animal and Human Rights Statement

All experimental animal procedures were performed in accordance with institutional guidelines for the care and use of laboratory animals.

Informed Consent

Not applicable.

Data Availability

The data supporting the findings of this study are available from the corresponding author upon reasonable request.

Conflict of Interest

The authors declare that there is no conflict of interest.

Funding

This work was financially supported by an institutional scientific research grant (Grant Number TTU 2020-13042).

Author Contributions (CRediT Taxonomy)

Conceptualization: İ.A., U.T., S.G., A.R., A.T.A., İ.C.E.
Methodology: İ.A., U.T., S.G., A.R., A.T.A., İ.C.E.
Software: S.P.Y.
Validation: K.E.E., S.P.Y.
Formal analysis: S.P.Y.
Investigation: B.Y., A.Y.
Resources: H.M.K., İ.C.E.
Data curation: B.Y., A.Y., S.P.Y.
Writing – original draft: İ.A., U.T., S.G.
Writing – review & editing: A.R., A.T.A., İ.C.E., H.M.K.
Visualization: K.E.E.
Supervision: A.T.A., İ.C.E.
Project administration: İ.C.E.
Funding acquisition: İ.C.E., H.M.K.

AI Usage Disclosure

The authors did not declare the use of AI-assisted technologies in the preparation of this manuscript.

Abbreviations

ANOVA: Analysis of variance
ARRIVE: Animal research: reporting of in vivo experiments
bax: Bcl-2-associated x protein
bcl-2: B-cell lymphoma 2
CAT: Catalase
EDTA: Ethylenediaminetetraacetic acid
ELISA: Enzyme-linked immunosorbent assay
GPx: Glutathione peroxidase
IBD: Inflammatory bowel disease
IL-6: Interleukin-6
IR: Intrarectal
MDA: Malondialdehyde
MPO: Myeloperoxidase
NaCl: Sodium chloride
NF-κB: Nuclear factor kappa b
SOD: Superoxide dismutase
TNF-α: Tumor necrosis factor alpha

References

1. *Podolsky DK. Inflammatory bowel disease. N Engl J Med. 2002;347:417-429. doi:10.1056/nejmra020831*

2. *Strober W, Fuss IJ. Proinflammatory cytokines in the pathogenesis of inflammatory bowel diseases. Gastroenterology. 2011;140:1756-1767. doi:10.1053/j.gastro.2011.02.016*

3. *Laharie D, Debeugny S, Peeters M, et al. Inflammatory bowel disease in spouses and their offspring. Gastroenterology. 2001;120:816-819. doi:10.1053/gast.2001.22574*

4. *Eray İC, Yalav O, Dalcı K, et al. The effects of glutamine and N-acetylcysteine on experimental colitis induced by 2,4,6-trinitrobenzene sulphonic acid in rats. Turk J Colorectal Dis. 2019;29:85-90. doi:10.4274/tjcd.galenos.2019.47640*

5. *Gul M, Akyuz C, Sunamak O, et al. Effects of Saint John's wort extract on intestinal injury and apoptosis. Ann Med Res. 2021;28:1725. doi:10.5455/annalsmedres.2020.11.1096*

6. *Kıyan S, Uyanıkgil Y, Altuncı YA, et al. Investigation of acute effects of Hypericum perforatum (St. John's wort–kantaron) treatment in experimental thermal burns and comparison with silver sulfadiazine treatment. Ulus Travma Acil Cerrahi Derg. 2015;21:323-336.*

7. *Yücel A, Kan Y, Yesilada E, et al. Effect of St. John's wort (Hypericum perforatum) oily extract for the care and treatment of pressure sores: a case report. J Ethnopharmacol. 2017;196:236-241. doi:10.1016/j.jep.2016.12.030*

8. *Morris GP, Beck PL, Herridge MS, et al. Hapten-induced model of chronic inflammation and ulceration in the rat colon. Gastroenterology. 1989;96:795-803. doi:10.1016/s0016-5085(89)80079-4*

9. *Xu BL, Zhang GJ, Ji YB. Active components alignment of Gegenqinlian decoction protects ulcerative colitis by attenuating inflammatory and oxidative stress. J Ethnopharmacol. 2015;162:253-260. doi:10.1016/j.jep.2014.12.042*

10. *Tanideh N, Sadeghi F, Amanat S, et al. Protection by pure and genistein-fortified extra virgin olive oil, canola oil, and rice bran oil against acetic acid-induced ulcerative colitis in rats. Food Funct. 2020;11:860-870. doi:10.1039/c9fo01951k*

11. *Wang G, Xu B, Shi F, et al. Protective effect of methane-rich saline on acetic acid-induced ulcerative colitis via blocking the TLR4/NF-κB/MAPK pathway and promoting IL-10/JAK1/STAT3-mediated anti-inflammatory response. Oxid Med Cell Longev. 2019;2019:7850324. doi:10.1155/2019/7850324*

12. *Krawisz JE, Sharon P, Stenson WF. Quantitative assay for acute intestinal inflammation based on myeloperoxidase activity. Gastroenterology. 1984;87:1344-1350. doi:10.1016/0016-5085(84)90202-6*

13. *Osafo N, Obiri DD, Danquah KO, et al. Potential effects of xylopic acid on acetic acid-induced ulcerative colitis in rats. Turk J Gastroenterol. 2019;30:732-744. doi:10.5152/tjg.2019.18389*

14. *Lieberman M, Marks AD, Smith CM, et al. Marks' essential medical biochemistry. Lippincott Williams & Wilkins; 2007*

15. *Halliwell B. Free radicals, antioxidants, and human disease: curiosity, cause, or consequence? Lancet. 1994;344:721-724. doi:10.1016/s0140-6736(94)92211-x*

16. *Xing J, You C, Dong K, et al. Ameliorative effects of 3,4-oxo-isopropylidene-shikimic acid on experimental colitis and their mechanisms in rats. Int Immunopharmacol. 2013;15:524-531. doi:10.1016/j.intimp.2013.02.008*

17. *Sehirli AO, Cetinel S, Ozkan N, et al. St. John's wort may ameliorate 2,4,6-trinitrobenzenesulfonic acid colitis of rats through the induction of pregnane X receptors and/or P-glycoproteins. J Physiol Pharmacol. 2015;66:203-214*

18. *Rezayat SM, Dehpour AR, Motamed SM, et al. Foeniculum vulgare essential oil ameliorates acetic acid-induced colitis in rats through the inhibition of NF-κB pathway. Inflammopharmacology. 2017;26:851-859.*

19. *de Paula do Nascimento R, Lima AV, Oyama LM, et al. Extra virgin olive oil and flaxseed oil have no preventive effects on DSS-induced acute ulcerative colitis. Nutrition. 2020;74:110731. doi:10.1016/j.nut.2020.110731*

20. *Tang X, Huang G, Zhang T, et al. Elucidation of colon-protective efficacy of diosgenin in experimental TNBS-induced colitis: inhibition of NF-κB/IκB-α and Bax/caspase-1 signaling pathways. Biosci Biotechnol Biochem. 2020;84:1903-1912. doi:10.1080/09168451.2020.1776590*

21. *Shen J, Cheng J, Zhu S, et al. Regulating effect of baicalin on IKK/IκB/NF-κB signaling pathway and apoptosis-related proteins in rats with ulcerative colitis. Int Immunopharmacol. 2019;73:193-200. doi:10.1016/j.intimp.2019.04.052*

22. *Talapka P, Nagy LI, Pál A, et al. Alleviated mucosal and neuronal damage in a rat model of Crohn's disease. World J Gastroenterol. 2014;20:16690-16697. doi:10.3748/wjg.v20.i44.16690*

23. *Cagin YF, Parlakpinar H, Vardi N, et al. Effects of dexpanthenol on acetic acid-induced colitis in rats. Exp Ther Med. 2016;12:2958-2964. doi:10.3892/etm.2016.3728*

How to Cite

İshak Aydın, Uğur Topal, Serdar Gümüş, Ali Yıldırım, Burak Yavuz, Ahmet Rencüzoğulları, Atılgan Tolga Akçam, Kıvılcım Eren Erdoğan, Sevinç Püren Yücel, Halil Mahir Kaplan, İsmail Cem Eray. Examining the efficacy of hypericum perforatum oil in acetic acid-induced colitis. Ann Clin Anal Med 2026;17(12):1329-1333. ARTİCLE İN PRESS. doi:10.4328/ACAM.50063