This work is licensed under a Creative Commons Attribution-NonCommercial 4.0 International License (CC BY-NC 4.0). To view a copy of the license, visit **https://creativecommons.org/licenses/by-nc/4.0/**

Annals of Clinical and Analytical Medicine
Original Research

One lesion, two different stories: the changing clinical face of symptomatic Meckel's diverticulum in children and adults

Meckel's diverticulum: children vs adults

Özgür Ekinci[1] Medeni Şermet[1] Meltem Çağlar[2] Gökçe Akyol[2] Çiğdem Ulukaya Durakbaşa[2] Orhan Alimoğlu[1]

[1]Department of General Surgery, Faculty of Medicine, Istanbul Medeniyet University, Istanbul, Türkiye.
[2]Department of Pediatric Surgery, Faculty of Medicine, Istanbul Medeniyet University, Istanbul, Türkiye.

Abstract

Aim: Symptomatic Meckel's diverticulum (MD) is a rare but serious cause of acute abdomen. This study compared clinical features, diagnostic approaches, and outcomes of complicated MD in pediatric and adult patients.

Methods: A retrospective review was conducted of 45 patients who underwent surgery for MD between 2017 and 2025. Patients were classified as pediatric (<18 years, *n* = 29) or adult (≥18 years, *n* = 16). Demographics, presentation, diagnostics, operative findings, pathology, and outcomes were analyzed using SPSS 28.0.

Results: Male predominance was observed in both groups. Adults experienced a significantly longer time to diagnosis (8.5 vs. 3.9 days, *P* = *.003*). Gastrointestinal bleeding was more frequent in children (41.4% [including isolated bleeding (27.6%) and bleeding combined with abdominal pain (13.8%)] vs. 6.2%), whereas abdominal pain with or without vomiting predominated in adults (93.7%). Comorbidities were significantly higher in adults (75% vs. 13.8%, *P* < *.01*). Perforation occurred more frequently in adults (37.5% vs. 3.4%, *P* = *.008*). Ultrasound was the primary diagnostic modality in pediatrics (100%), while computed tomography was universal in adults (100%, *P* < *.001*). The laparoscopic approach was more common in children (55.2% vs. 25%). Adults demonstrated larger diverticular base dimensions (2.6 vs. 1.6 cm, *P* < *.001*) and prolonged hospital stays (14.7 vs. 8.2 days, *P* < *.001*). One mortality occurred in each group.

Conclusion: Pediatric symptomatic MD typically presents with bleeding and obstruction, while adult cases are characterized by diagnostic delay, comorbidities, and elevated risk of perforation and diverticulitis. Age-specific diagnostic algorithms and timely surgical intervention are essential to minimize morbidity and mortality.

Keywords

Meckel's diverticulum, diverticulitis, pediatrics, adults, acute abdomen, complications

DOI: 10.4328/ACAM.50082 Ann Clin Anal Med 2026;17(12): 0-0
Received: 16.02.2026 Accepted: 03.04.2026 Published Online: 08.04.2026 Printed: 01.12.2026
Corresponding Author: Medeni Şermet, Department of General Surgery, Faculty of Medicine, Istanbul Medeniyet University, Istanbul, Türkiye.
Email: medeni.sermet@medeniyet.edu.tr **P.:** +90 507 236 70 20
Corresponding Author ORCID: https://orcid.org/0000-0001-6119-0037
Other Authors ORCID: Özgür Ekinci, https://orcid.org/0000-0002-2020-1913 • Meltem Çağlar, https://orcid.org/0000-0003-4706-6384 • Gökçe Akyol, https://orcid.org/0009-0008-7179-9346 • Çiğdem Ulukaya Durakbaşa, https://orcid.org/0000-0002-6474-3407 • Orhan Alimoğlu, https://orcid.org/0000-0003-2130-2529

Introduction

Meckel's diverticulum (MD) is the most common congenital gastrointestinal system anomaly resulting from incomplete closure of the embryonic vitelline duct (omphalomesenteric duct).[1] Although its prevalence in the general population is reported to be approximately 2%, most cases are asymptomatic and are usually detected incidentally during surgery or autopsy for other reasons. In a significant proportion of symptomatic MD cases, inflammatory processes (Meckel's diverticulitis [MD]) are the main complication and can lead to acute abdominal symptoms. MD can be clinically confused with acute appendicitis, Crohn's disease, diverticulitis due to other causes, or intestinal obstruction, leading to delays in diagnosis and increased morbidity/mortality risk.[2,3]

Although numerous studies in the literature address MD and its complications, most have focused on either pediatric or adult populations.[4,5] In the pediatric population, MD is one of the leading causes of lower gastrointestinal bleeding, especially in the first 2 years of life, and is associated with the presence of ectopic gastric mucosa. In adults, symptomatic MD is less common, but differences such as longer time to diagnosis, presence of comorbidities, and higher perforation rates have been reported. Comprehensive studies directly comparing the potential differences in clinical presentation, diagnostic challenges, spectrum of complications, and treatment outcomes between these two age groups are limited.

This retrospective cohort study compares pediatric and adult cases of Meckel's diverticulum requiring surgery at a single center with respect to demographic characteristics, presenting complaints, diagnostic processes (imaging and laboratory), intraoperative findings and surgical techniques, pathological features, complications, hospital stay durations, and mortality. For the purposes of this study, we included all major complications requiring surgery, namely acute diverticulitis, significant hemorrhage, and mechanical intestinal obstruction secondary to diverticulitis. The limited number of comprehensive studies in the literature that provide detailed comparisons between pediatric and adult patient groups underscores the original value of this study. The data obtained are intended to contribute to increasing clinical suspicion in both age groups, improving diagnostic approaches, and determining age-specific treatment strategies.

Materials and Methods

Study Design and Ethical Approval

We evaluated consecutive patients diagnosed with Meckel's diverticulum who underwent surgical treatment at a tertiary University Hospital between January 2017 and January 2025. All patient data were fully anonymized prior to analysis in compliance with applicable data protection regulations. The study protocol conformed to the ethical principles of the Declaration of Helsinki. Given the retrospective nature of the study and the use of de-identified data, the requirement for written informed consent was waived by the institutional review board.

Inclusion and Exclusion Criteria

Eligible participants were patients of any age presenting with an acute abdomen attributable to complicated Meckel's diverticulum, including acute diverticulitis, overt gastrointestinal bleeding originating from the diverticulum, or bowel obstruction caused by the diverticulum or associated fibrous bands, who subsequently underwent surgery with histopathological confirmation of Meckel's diverticulum. Exclusion criteria included asymptomatic or incidentally detected diverticula, nonoperative management, lack of pathological confirmation, and incomplete clinical records (Figure 1).

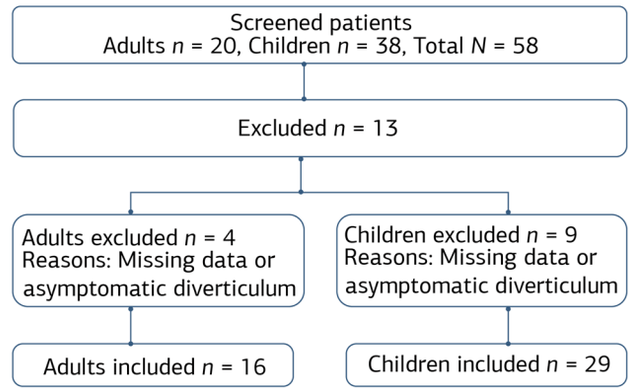

Figure 1. *Patients Flowchart*

Data Collection

Data were extracted from hospital information systems using a standardized form. Demographic characteristics (age, sex, comorbidities) and presenting complaints (abdominal pain, vomiting, gastrointestinal bleeding, symptom duration) were recorded. Laboratory variables included WBC count, CRP, hemoglobin, fecal occult blood, and stool culture. Imaging modalities (USG, CT, MRI, Meckel scintigraphy) and colonoscopy findings were documented. Surgical data included time to surgery, operative method, distance from the ileocecal valve, intraoperative findings, type of procedure, and any additional interventions. Pathology reports provided diverticulum size, ectopic tissue, tumor presence, and final diagnosis. Postoperative outcomes included complications, length of stay, and mortality.

Grouping

Patients were categorized as:

Pediatric Group: <18 years (n = 29), Adult Group: ≥18 years (n = 16).

Ethical Approval

This study was approved by the Ethics Committee of Göztepe Prof. Dr. Süleyman Yalçın City Hospital (Date: 11.09.2025, Decision No: 0155).

Statistical Analysis

Analyses were performed using SPSS v28. Continuous variables were expressed as median (min–max) or mean ± SD; categorical variables as number and percentage. Normality was assessed using the Shapiro–Wilk test. Independent Samples t-test or Mann–Whitney U test was used for continuous variables, and Chi-square or Fisher's Exact test for categorical comparisons. Statistical significance was set at $P < .05$. Due to the exploratory design and multiple comparisons, P values were interpreted cautiously and considered hypothesis-generating. No formal sample size calculation was performed due to the retrospective design.

Post-hoc power analysis for the primary outcome (adult vs. pediatric perforation rate: 37.5% vs. 3.4%) indicated that the current sample size provided approximately 85% power at $\alpha = 0.05$, supporting the statistical robustness of this key finding. Other secondary comparisons should be interpreted with caution, given the small adult group (n = 16) and exploratory design.

Reporting Guidelines

This study is reported in accordance with the STROBE guidelines.

Results

A total of 45 patients were included in the study, comprising 29 pediatric and 16 adult patients. Male predominance was observed in both groups, with no significant difference between them (87.5% vs. 89.6%, *p=1.00*). Adults had significantly higher rates of comorbidities, particularly diabetes mellitus, inflammatory bowel disease, and hypertension (each 25%, *P < .05*). Pediatric-specific comorbidities such as nephrotic syndrome and neonatal jaundice were rare and showed no statistical difference. Detailed demographic characteristics and baseline clinical findings are summarized in.

Clinical presentation differed between groups (*P = .058*). Adults most commonly presented with abdominal pain alone (50.0%) or abdominal pain accompanied by vomiting (43.7%). In contrast, pediatric patients demonstrated a more heterogeneous symptom profile, with abdominal pain alone (41.3%) and isolated gastrointestinal bleeding (27.6%) being the most frequent presentations. Laboratory analysis showed significantly higher WBC counts in children (13.2 vs. 8.7 × 10^3/μL, *P = .015*), whereas adults had significantly higher CRP levels (32.3 vs. 14.9 mg/L, *P = .028*). Positive stool culture results were more frequent in adults (31.2% vs. 3.4%), although this difference did not reach statistical significance (*P = .087*).

Marked differences were observed in diagnostic imaging utilization. Ultrasonography was performed in all pediatric patients (100%) and in 68.7% of adults (*P = .003*). Pathological findings were detected by ultrasonography in 75.8% of pediatric cases. Computed tomography was performed in all adult patients (100%) and detected pathological findings in 93.8% of cases (*P < .001*). Meckel scintigraphy was positive in all pediatric patients with gastrointestinal bleeding, but yielded no positive results in adults. Colonoscopy was performed significantly more frequently in adults (56.2% vs. 10.3%, *P = .002*). Intraoperative findings showed significantly higher perforation rates in adults (37.5% vs. 3.4%, *P = .008*), while fibrous bands were observed only in pediatric patients (27.5% vs. 0%, *P = .037*). Bleeding tended to be more common in children (30.9% vs. 6.2%, *P = .070*), though this did not reach statistical significance. There were no significant differences in diverticulitis or intussusception rates.

Adults had a significantly larger diverticular base diameter (2.6 vs. 1.6 cm; *P < .001*). Pathologically, diverticulitis was the predominant diagnosis in both groups, and one adult patient was diagnosed with a gastrointestinal stromal tumor. Postoperative hospital stay was significantly longer in adults (14.7 vs. 8.2 days, *P < .001*). Mortality occurred in one patient in each group.

The detailed data are provided in Supplementary Table 1 and Supplementary Table 2.

Discussion

This study demonstrates clear and clinically meaningful differences between pediatric and adult patients undergoing surgical treatment for MD, particularly in clinical presentation, diagnostic strategies, intraoperative findings, and postoperative outcomes. These distinctions reflect underlying age-specific pathophysiological mechanisms and highlight the need to tailor diagnostic suspicion, imaging choices, and management algorithms according to patient age.

A major finding of this study is the substantial divergence in presenting symptoms between the two age groups. In pediatric patients, bleeding was significantly more frequent, occurring either alone (27.6%) or in combination with abdominal pain (13.8%), whereas it was much rarer in adults (6.2%, *P < .01*). This observation aligns with widely recognized evidence in the literature describing that bleeding in children with MD is strongly associated with the presence of ectopic gastric mucosa. The gastric mucosa within the diverticulum secretes hydrochloric acid and pepsin, leading to ulceration of the adjacent ileal mucosa; this mechanism is more pronounced during childhood due to the narrower diverticular base and the higher secretory activity of ectopic mucosa.[6] While our results do not imply that MD is the leading cause of lower gastrointestinal bleeding in the general pediatric population, they reinforce that among children with symptomatic MD, bleeding is the predominant clinical mode of presentation. In contrast, adults typically presented with abdominal pain alone (50.0%) or abdominal pain accompanied by vomiting (43.7%), suggesting that mechanical complications such as diverticulitis, obstruction, or perforation predominate in adulthood. This pattern is consistent with the tendency for the diverticular base to widen over time, predisposing to fecalith formation, bacterial overgrowth, and subsequent inflammatory complications. Additionally, comorbidities such as diabetes or vascular disease may predispose adults to ischemic necrosis and exacerbate local inflammation.[7] These differences collectively highlight the age-dependent pathophysiological evolution of MD, with bleeding from ectopic mucosa seen mainly in children and mechanical or inflammatory complications predominating in adults.

Equally important are the differences observed in diagnostic processes. Time to diagnosis was significantly longer in adults than in children (8.5 vs. 3.9 days, *P = .003*), a delay likely due to a lower index of suspicion for MD in adults, the nonspecificity of symptoms, and symptom masking by comorbidities such as inflammatory bowel disease. The literature suggests that diagnostic delay increases the risk of perforation in adult MD,[8] a finding mirrored in our results, with a high perforation rate in adults (37.5%, *P = .008*). In contrast, pediatric patients were diagnosed more rapidly, aided by more specific symptoms, such as overt bleeding, and more frequent emergency department visits.

Imaging patterns also differed markedly between groups. All pediatric patients underwent ultrasonography (USG), and pathological findings were detected in 75.8% of cases, confirming USG as a high-utility, radiation-free option in children.[9] In adults, however, USG use was significantly lower (68.7%, *P = .003*), likely due to reduced sensitivity caused by increased abdominal adipose tissue.[10] Children benefit from a thin abdominal wall and minimal fat, which facilitate visualization of mesenteric inflammation or free fluid, whereas adult adiposity and longer bowel segments limit the effectiveness of USG.[11] Accordingly, adults uniformly underwent CT imaging, which detected pathological findings in 93.8% of cases (*P < .001*), reaffirming CT as the diagnostic standard in adult MD. CT's superiority lies in its ability to identify perforation, abscess formation, and fat stranding, all of which are especially relevant in adults with more severe or delayed presentations. Meckel scintigraphy was positive in all pediatric bleeding cases but negative in adults, consistent with the known limitations of scintigraphy in adults. This discrepancy may be explained by the higher activity of ectopic gastric mucosa in children and by the reduced sensitivity of scintigraphy in adults when inflammation disrupts blood flow.[12] Notably, Srisan et al. (2025) conducted a directly comparable pediatric-versus-adult analysis of MD, similarly reporting higher bleeding rates in children and higher perforation rates in adults, consistent with our findings. However, our cohort demonstrated a higher adult perforation rate (37.5%

vs. approximately 15% in Srisan et al.), potentially reflecting differences in referral patterns, diagnostic delay, or comorbidity burden between the two single-center cohorts.[12] The convergence of results across both studies reinforces the robustness of age-stratified clinical patterns in symptomatic MD. Colonoscopy, performed more frequently in adults (56.2% vs. 10.3%, *P = .002*), was useful for detecting secondary features such as terminal ileal narrowing, which are more common in adults with comorbid conditions, including inflammatory bowel disease.[13]

Laboratory parameters further reflected age-based physiological differences. Higher WBC levels in children (13.2 vs. 8.7 × 10^3/μL, *P = .015*) suggest a more vigorous leukocyte response to acute inflammation. Conversely, adults had significantly higher CRP levels (32.3 vs. 14.9 mg/L, *P = .028*), likely resulting from more prolonged symptom duration and comorbidities.[14] Children mount a rapid leukocyte-driven response, whereas adults—particularly those with chronic illnesses such as diabetes—demonstrate a more pronounced acute-phase reaction.[15] Stool culture positivity was more common in adults (31.2% vs. 3.4%, *P = .087*), potentially reflecting longer exposure to hospital environments and higher rates of bacterial colonization associated with perforation and diverticulitis.[16]

Intraoperative findings also differed substantially. Adults had a significantly higher perforation rate (37.5% vs. 3.4%, *P = .008*), a finding consistent with delayed diagnosis, a wider diverticular base (2.6 cm vs. 1.6 cm, *P < .001*), and comorbid conditions that predispose to ischemia.[17] Chronic diseases such as diabetes and atherosclerosis may impair local microvascular perfusion, thereby increasing the risk of tissue necrosis and perforation. Literature reports perforation rates of 15–40% in adult MD, underscoring the clinical relevance of our findings. The rarity of perforation in children is consistent with rapid diagnosis and the absence of comorbidities.[18] Conversely, fibrous bands were significantly more common in pediatric patients (27.5% vs. 0%, *P = .037*). These bands, remnants of the omphalomesenteric duct, predispose children to obstruction, volvulus, and intussusception due to increased intestinal mobility and anatomical configuration.[19] The higher trend toward bleeding in children is attributable to the higher prevalence of ectopic gastric mucosa, while adults are less affected due to lower mucosal activity and inflammation-dominant disease progression.[20]

Postoperative outcomes also differed significantly. Adults had longer hospital stays (14.7 vs. 8.2 days, *P < .001*), reflecting the burden of perforation, comorbidities, open surgery, and postoperative complications such as peritonitis and sepsis.[21] Children more often underwent laparoscopic surgery (55.2%), which is associated with less tissue trauma, lower infection rates, and faster recovery. The absence of comorbidities and a lower perforation rate also contributed to shorter hospitalizations in children. Mortality occurred in one patient from each group, demonstrating that perforation and comorbidities substantially elevate mortality risk. The identification of a gastrointestinal stromal tumor (GIST) in one adult patient underscores the importance of routine pathological examination, especially in adults.

Limitations

This study has limitations, including its retrospective, single-center design, small sample size (particularly among adults), heterogeneity of symptoms, and variable follow-up durations, all of which may affect generalizability.

Conclusion

Meckel's diverticulitis behaves differently across age groups. Children predominantly experience bleeding and obstruction, whereas adults more often present with delayed diagnosis, inflammation, and perforation. These findings highlight the importance of age-adjusted diagnostic pathways: USG and scintigraphy in children and CT and colonoscopy in adults. Clinicians should consider MD in the differential diagnosis of acute abdomen across all age groups and adjust diagnostic strategies based on age-specific pathophysiology and presentation.

Declarations

Animal and Human Rights Statement

All procedures performed in this study were in accordance with the ethical standards of the institutional and/or national research committee and with the 1964 Declaration of Helsinki and its later amendments, or comparable ethical standards.

Informed Consent

Due to the retrospective nature of the study and the use of fully anonymized data, the requirement for written informed consent was waived by the institutional review board.

Data Availability

The datasets used and/or analyzed during the current study are not publicly available due to patient privacy reasons but are available from the corresponding author on reasonable request.

Conflict of Interest

The authors declare no conflict of interest.

Funding

None.

Author Contributions (CRediT Taxonomy)

Conceptualization: Ö.E., M.Ş., M.Ç.
Methodology: Ö.E., M.Ş., M.Ç.
Software: Ö.E., M.Ş., M.Ç.
Validation: Ö.E., M.Ş., M.Ç.
Formal Analysis: G.A., Ç.U.D., O.A.
Investigation: G.A., Ç.U.D., O.A.
Resources: G.A., Ç.U.D., O.A.
Data Curation: G.A., Ç.U.D., O.A.
Writing – Original Draft Preparation: G.A., Ç.U.D., O.A.
Writing – Review & Editing: G.A., Ç.U.D., O.A.
Visualization: G.A., Ç.U.D., O.A.
Supervision: Ö.E., M.Ş., M.Ç.
Project Administration: Ö.E., M.Ş., M.Ç.

AI Usage Disclosure

The authors declare that no AI-assisted technologies were used.

Abbreviations

CI: Confidence interval
CRP: C-reactive protein
CT: Computed tomography
GIST: Gastrointestinal stromal tumor
MD: Meckel's diverticulum
MRI: Magnetic resonance imaging
SD: Standard deviation
STROBE: Strengthening the reporting of observational studies in epidemiology
USG: Ultrasonography
WBC: White blood cell

References

1. *Choi SY, Hong SS, Park HJ, Lee HK, Shin HC, Choi GC. The many faces of Meckel's diverticulum and its complications. J Med Imaging Radiat Oncol. 2017;61(2):225-231. doi:10.1111/1754-9485.12505*

2. *Hansen CC, Søreide K. Systematic review of epidemiology, presentation, and management of Meckel's diverticulum in the 21st century. Medicine (Baltimore). 2018;97(35):e12154. doi:10.1097/MD.0000000000012154*

3. *Zani A, Eaton S, Rees CM, Pierro A. Incidentally detected Meckel diverticulum: to resect or not to resect? Ann Surg. 2008;247(2):276-281. doi:10.1097/SLA.0b013e31815aaaf8*

4. *Dumper J, Mackenzie S, Mitchell P, Sutherland F, Quan ML, Mew D. Complications of Meckel's*

diverticula in adults. Can J Surg. 2006;49(5):353-357.

5. *Groebli Y, Bertin D, Morel P. Meckel's diverticulum in adults: retrospective analysis of 119 cases and historical review. Eur J Surg. 2001;167(7):518-524.*

6. *Lequet J, Menahem B, Alves A, Fohlen A, Mulliri A. Meckel's diverticulum in the adult. J Visc Surg. 2017;154(4):253-259. doi:10.1016/j.jviscsurg.2017.06.006*

7. *Koç ZP, Özcan PP, Tuncel F, İsbir C, Usta Y. SPECT/CT in the diagnosis of ectopic gastric mucosa-Meckel's diverticulum. World J Nucl Med. 2024;23(3):176-179. doi:10.1055/s-0044-1787719*

8. *Ueberrueck T, Meyer L, Koch A, Hinkel M, Kube R, Gastinger I. The significance of Meckel's diverticulum in appendicitis-a retrospective analysis of 233 cases. World J Surg. 2005;29(4):455-458. doi:10.1007/s00268-004-7615-x*

9. *Alemayehu H, Stringel G, Lo IJ, et al. Laparoscopy and complicated Meckel diverticulum in children. JSLS. 2014;18(3):e2014.00015. doi:10.4293/JSLS.2014.00015*

10. *Blouhos K, Boulas KA, Tsalis K, et al. Meckel's diverticulum in adults: surgical concerns. Front Surg. 2018;5:55. doi:10.3389/fsurg.2018.00055*

11. *Grasso E, Politi A, Progno V, Guastella T. Spontaneous perforation of Meckel's diverticulum: case report and review of literature. Ann Ital Chir. 2013;84(ePub):S2239253X13020902.*

12. *Srisan N, Songsiri P, Liukitithara S, et al. Meckel's diverticulum: differences in clinical features between children and adults. Pediatr Surg Int. 2025;41(1):284. doi:10.1007/s00383-025-06183-8*

13. *Kumar S, Panchal M, Mishra P, Srivastava P, Tanti SK. The many faces of Meckel's diverticulum: clinical presentations and complications. Cureus. 2025;17(8):e90370. doi:10.7759/cureus.90370*

14. *Butler K, Peachey T, Sidhu R, Tai FWD. Demystifying Meckel's diverticulum - a guide for the gastroenterologist. Curr Opin Gastroenterol. 2025;41(3):146-153. doi:10.1097/MOG.0000000000001085*

15. *Gambardella M, Smaldone M, Iazzetta F, Corbisiero MC, Graviero G, Coppola GM. Preoperative CT diagnosis of perforated Meckel's diverticulitis in a young patient: a case report. J Basic Clin Physiol Pharmacol. 2023;35(1-2):93-97.*

16. *Dos Santos Villalaz E, Rios Rodriguez JE, Rodrigues Seixas Nunes Z, de Souza Bivaqua VB, Moreira Printes TR, Façanha Neto CD. Obstructive acute abdomen due to Meckel's diverticulum in adult: case report. Int J Surg Case Rep. 2022;99:107717. doi:10.1016/j.ijscr.2022.107717*

17. *Lindeman RJ, Søreide K. The many faces of Meckel's diverticulum: update on management in incidental and symptomatic patients. Curr Gastroenterol Rep. 2020;22(1):3. doi:10.1007/s11894-019-0742-1*

18. *Malik AA; Shams-ul-Bari, Wani KA, Khaja AR. Meckel's diverticulum-revisited. Saudi J Gastroenterol. 2010;16(1):3-7. doi:10.4103/1319-3767.58760*

19. *Mason M, Neel NC, Matson J, Abbadessa B, Minns AB. Meckel's diverticulum enterolith presenting as small bowel obstruction. J Emerg Med. 2023;64(6):718-720. doi:10.1016/j.jemermed.2023.03.048*

20. *Keot KB, Rajbongshi MC, Medhi R, Barbhuiya EA, Kumar R, Borthakur D. An atypical case of Meckel's diverticulum with small bowel obstruction: surgical anatomy, embryology and clinical implications. Clin Ter. 2023;174(2):121-125.*

21. *Gonzalez-Urquijo M, Espino-Rodriguez M, Romero-Davila A, Rodarte-Shade M, Gil-Galindo GA. Persistence of a vitelline artery on a Meckel's diverticulum as a cause of bowel infarction. Clin J Gastroenterol. 2020;13(3):386-392. doi:10.1007/s12328-019-01062-x*

How to Cite

Özgür Ekinci, Medeni Şermet, Meltem Çağlar, Gökçe Akyol, Çiğdem Ulukaya Durakbaşa, Orhan Alimoğlu. One lesion, two different stories: the changing clinical face of symptomatic Meckel's diverticulum in children and adults. Ann Clin Anal Med 2026;17(12): Article in Press doi:10.4328/ACAM.50082