Servikal Mediastinotomi ve Tüp Drenajı ile Tedavi Edilen İatrojenik Trakea Yaralanması, Olgu Sunumu

Treatment of Iatrogenic Tracheal Laceration with Cervical Mediastinotomy and Tube Drainage; a Case Report

Servikal Mediastinotomi ile Tedavi Edilen Trakea Yaralanması
Treatment of Tracheal Laceration with Cervical Mediastinotomy

Berkant Özpolat[1], Cansel Atinkaya[2], Nezih Özdemir[3]
[1]Department of Thoracic Surgery, Kırıkkale University Faculty of Medicine, Kırıkkale, Türkiye.
[2]Department of Thoracic Surgery, Pamukkale University Faculty of Medicine, Denizli, Türkiye.
[3]Department of Thoracic Surgery, Dokuz Eylül University Faculty of Medicine, İzmir, Türkiye.

Özet

Trakeobronşiyal hasar endotrakeal entübasyonun hayati bir komplikasyonudur. Akciğer kist hidatiği nedeniyle standart torakotomi ile kistotomi ve kapitonaj ameliyatı uygulanan 7 yaşındaki bir kız çocukta masif ciltaltı amfizem gelişmesi sonrasında teşhis edilen, entübasyon nedenli trakea yaralanması sunuldu. Tedavide servikal mediastinotomi ve tüp drenajı başarıyla kullanıldı. Konservatif ve cerrahi tedavi metodları tartışıldı.

Anahtar Kelimeler

İntratrakeal Anestezi, Trakea, Pnömomediastinum, Laserasyon, Ciltaltı Amfizemi.

Abstract

Tracheobronchial injury is a life threatening complication of endotracheal intubation. An intubation induced tracheal laceration diagnosed after massive subcutaneous emphysema, in a 7-year-old girl who underwent a cystotomy and capitonnage operation through a standard thoracotomy for pulmonary hydatid cyst is presented. She was treated with cervical mediastinotomy and tube drainage with an uneventful clinical outcome. Conservative and surgical treatment methods are discussed.

Keywords

Intratracheal Anesthesia, Trachea, Pneumomediastinum, Laceration, Subcutaneous Emphysema.

DOI: 10.4328/JCAM.240 Received: 28.03.2010 Accepted: 19.04.2010 Publihed Online: 22.04.2010 J Clin Anal Med 2011;2(2):102-103
Corresponding Author: Berkant Özpolat, Department of Thoracic Surgery, Kırıkkale University Faculty of Medicine, Kırıkkale, Türkiye.
GSM: 05058395247 E-mail:berkantozpolat@yahoo.com

Introduction

Despite the great number of intubations and diagnostic or therapeutic endobronchial interventions, iatrogenic tracheal lacerations are rare complications.[1] After double-lumen tube intubations, the frequency of tracheobronchial rupture (TBR) remains low, estimated between 0.05% - 0.19%. Location of the lesions is generally posterior, mainly concerning the membranous wall of the trachea or the junction between the membranous wall and the cartilage.[2] Management of iatrogenic TBR is controversial. Besides surgical therapy, a growing body of evidence showing that iatrogenic TBR can be dealt conservatively in selected cases.[1,3] A life threatening complication of iatrogenic tracheal laceration which is successfully managed by cervical mediastinotomy and tube drainage is presented.

Case

A 7-year-old girl was admitted with complaints of cough, sore throat and fever. Her physical examination revealed an upper respiratory infection. Chest radiography showed a right middle zone mass and computed tomography scan revealed a cystic mass 14x15 cm in diameter in the same location (Figures 1, 2). Indirect hemagglutination test result supported the prediagnosis of hydatid cyst. A right posterolateral muscle sparing thoracotomy was performed under single lumen endotracheal tube ventilation. The mass was identified at the upper lobe to be hydatid cyst. Cystotomy and capitonnage was carried out without any peroperative complication. The patient was extubated and moved to intensive care unit. Six hours after the operation she started to develop subcutaneous emphysema in the jugular notch progressing to neck and chest wall. Posteroanterior chest radiography showed excessive subcutaneous emphysema. A mild hemoptysis started. Computed tomography scan revealed pneumomediastinum with air along trachea and the operated lung totally expanded (Figure 3). Rigid bronchoscopy was performed under general anesthesia and a 10 mm laceration was detected on the right side of trachea close to the membranous part, 2 cm above the carina. A small transverse incision in the suprasternal notch was done, similar to a mediastinoscopy incision. Pretracheal fascia was dissected easily due to extensive pneumomediastinum and a 12F silicone chest tube was placed the lodge anteriorly to trachea to evacuate the continuing air leak from the tracheal laceration. The skin incision is closed firmly and the tube was connected to underwater drainage (Figure 4). Subcutaneous emphysema resolved immediately and the mediastinal tube was withdrawn 2 days later. She was discharged on postoperative day 9 with no further complications. Her follow up period was uneventful.

Discussion

Tracheal injuries, independent of their origin, are life threatening incidents.[3] The risk for tracheal laceration seems to increase with difficult or emergency intubations, multiple vigorous attempts of an inexperienced anesthesiologist, or the inappropriate use of a stylet. In most cases, they are due to an overinflated cuff, or to sudden moves of the tube. Inappropriate tube size is one of the most important risk factor reported in the literature.[1,2] The symptoms appear during surgery or immediate postoperative period are hemoptysis and subcutaneous emphysema of the head, neck, and upper chest and in severe cases, dyspnea and cyanosis.[1,3,4] Massive progressive subcutaneous emphysema and mild hemoptysis were observed at the 6th postoperative hour, without dyspnea in our case. Computed tomography scan coupled with bronchoscopy is necessary for diagnosis and aid to choose the most appropriate treatment method.[1,5,6] Computed tomography scan revealed pneumomediastinum and bronchoscopy showed a 10 mm laceration on the right side of trachea close to the membranous part, 2 cm above the carina in our case.

There is no established standard for the treatment of iatrogenic tracheal lacerations. The length, type, infection and clinical status of the patient are important factors for the choice of appropriate treatment. Small tears about 1 cm can be treated conservatively whereas in lesions larger than 2 cm, presence of extensive subcutaneous emphysema, pneumothorax and/or pneumomediastinum early surgical repair is recommended.[1,7] The surgical approach is determined by the location of the tear: left cervicotomy for the cervical trachea, right thoracotomy in the fourth intercostal space for the thoracic part.[2] Angelillo-Mackinlay proposed a new technique to take on this intubation-related complication. He performed a cervical mediastinoscopy incision similar to our method but additionally sutured the tear through a vertical incision made in the anterior wall of the trachea. The patient was intubated with a small single tube, retracted laterally to allow the suturing of the tear.[4] Temporary tracheostomy, as well as tracheal intubation, may be performed to prevent the patient from sudden intrabronchial hyperpressures caused by coughing, which may worsen subcutaneous emphysema and widen the tear.[1,7]

Conservative treatment was preferred in our case, although subcutaneous emphysema was massive and progressive. Besides the length of laceration was long compared to an adult and mediastinum was involved. Our method includes a cervical mediastinotomy via jugular notch and tube drainage resulted in total resolution of pneumomediastinum on the 5th postoperative day. We conclude that, in pediatric age group cervical mediastinotomy and tube drainage may be used as an alternative treatment approach for management of iatrogenic tracheal laceration.



Figure 1. CXR showing the mass at right middle zone

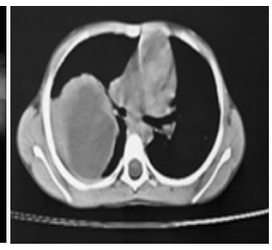

Figure 2. CT scan demonstrating cystic mass.

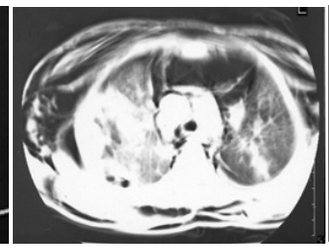

Figure 3. CT scan showing mediastinal and extensive subcutaneous emphysema.



Figure 4. CXR performed at the intensive care unit. The arrow shows the mediastinal tube.

References

1.Borasio P, Ardissone F, Chiampo G. Post-intubation tracheal rupture: A report on ten cases. Eur J Cardiothorac Surg. 1997;12:98-100.
2.Massard G, Rougé C, Dabbagh A, Kessler R, Hentz JG, Roeslin N, et al. Tracheobronchial laceration after intubation and tracheostomy. Ann Thorac Surg. 1996;61:1483–87.
3.Marty-Ane´ CH, Picard E, Jonquet O, Mary H. Membranous tracheal rupture after endotracheal intubation. Ann Thorac Surg. 1995;60:1367–71.
4.Angelillo-Mackinlay T. Transcervical repair of distal membranous tracheal laceration. Ann Thorac Surg. 1995;59:531–2.
5.Carbognani P, Bobbio A, Cattelani L, Internullo E, Caporale D, Rusca M. Management of Postintubation Membranous Tracheal Rupture. Ann Thorac Surg. 2004;77:406–9.
6.Balci AE, Eren N, Eren S, Ülkü R. Surgical treatment of post-traumatic tracheobronchial injuries: 14-year experience. Eur J Cardiothorac Surg. 2002;22:984-9.
7.Kaloud H, Smolle-Juettner FM, Prause G, List WF. Iatrogenic ruptures of the tracheobronchial tree. Chest. 1997;112:774-8.