Yetişkin Bir Olguda Pulmoner Sekestrasyon

Pulmonary Sequestration in a Middle Age Man

Trakeobronşiyal Sisteme Yerleştirilmiş Nazogastrik Tüp / Tracheobronchially Placed Nasogastric Tube

Akın Yıldızhan, Nurettin Yiyit, Ahmet Rauf Görür
GATA Haydarpaşa Training Hospital, İstanbul, Türkiye.

A 40 years old male patient was admitted with recurrent lung infections. Thoracic CT displayed a mass like lesion in lower lobe of the left lung (Figure 1). The lesion was suspected us about to be a sequestration and a CT angiography was performed. An aberrant vessel arising from thoracic aorta and supplying the lesion was detected (Figure 2,3). The lesion was accepted as pulmonary sequestration.

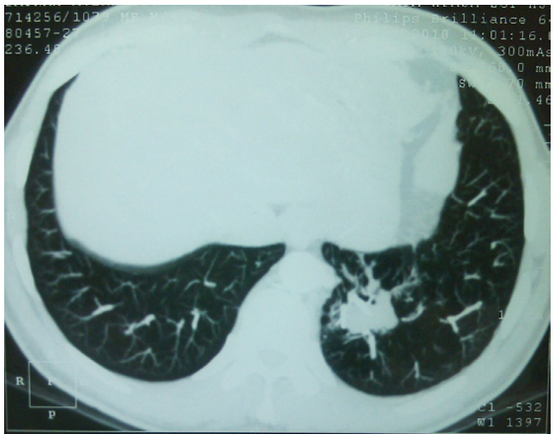

Figure 1. Thoracic CT displayed a mass in lower lobe of the left lung.

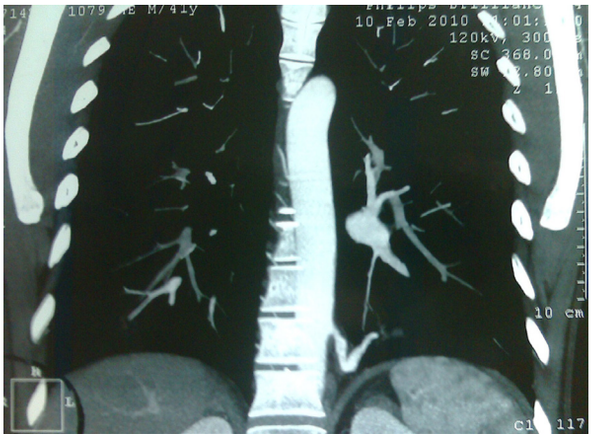

Figure 2. An aberrant vessel arising from thoracic aorta

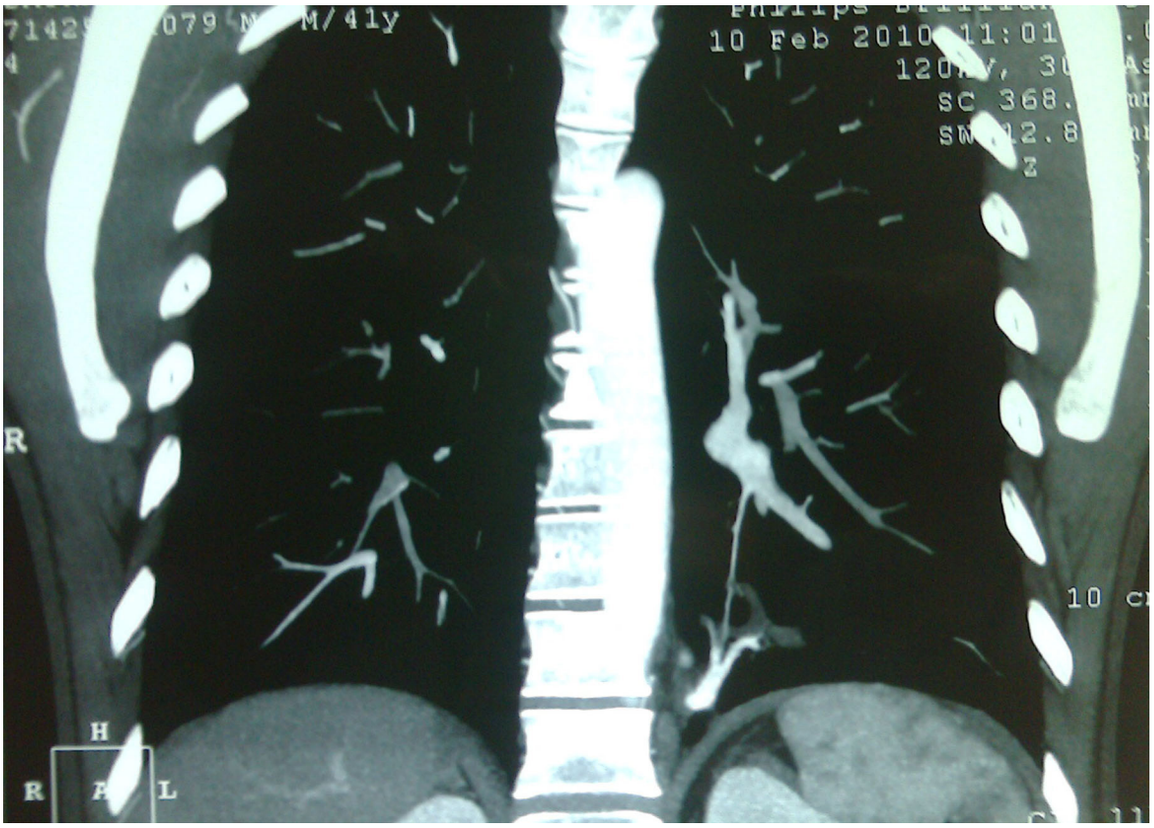

Figure 3. An aberrant vessel arising from thoracic aorta

DOI: 10.4328/JCAM.244 Received: 31.03.2010 Accepted: 21.04.2010 Publishen Online: 25.04.2010 J Clin Anal Med 2011;2(3):283-283
Corresponding Author: Akın Yıldızhan, GATA Haydarpaşa Training Hospital, İstanbul, Türkiye.
E-mail : aknyildizhan@gmail.com