Pektus Ekskavatum Deformitesinde Minimal İnvaziv Cerrahi: Park Teknigi

Minimally Invasive Surgery for Pectus Excavatum: Park Technique

Hyung Joo Park[1]
[1]Department of Thoracic and Cardiovascular Surgery, Korea University Medical Center, Korea.

Özet

Bin canlı doğumda bir görülen pectus excavatum (PE) en sık karşılaşılan göğüs duvarı deformitesidir. Sternum ve kostaların kıkırdak kısımlarının posteriora açılanmasına bağlı oluşan göğüs ön duvarı depresyonu, toraks içindeki organların kompresyonunun yanında estetik olarak hoş olmayan bir görünüme neden olur.Bu durumu düzeltmek için bir çok cerrahi teknik geliştirilmiştir. Deforme kosta kıkırdaklarının hepsinin çıkarılması, sternumdan interkostal paketlerin divizyonu ve transvers sternum osteotomisini kapsayan Ravitch prosedürü 1949'da ortaya konmuştur ve son zamanlara kadar en çok uygulanan tekniktir. Prensip olarak sternumun döndürülmesi olan Wada tekniği alternatif bir prosedür olmuştur. Bu invazif teknikler, kosta kıkırdaklarının kalıcı dekeftine ya da göğüs duvarı kontraktürüyle sonuçlanan uzun ve kanlı operasyonlar içerir. En önemlisi, göğüs ön duvarında büyük ve göze hoş gelmeyen operasyon skarı estetik açıdan tatmin edici değildir.Bu çalışmada "Pektus Ekskavatum Deformitesinde Minimal İnvaziv Cerrahi: Park Teknigi" sunulmuştur.

Anahtar Kelimeler

Pektus Ekskavatum; Minimal invaziv Cerrahi; Park Teknigi

Abstract

Pectus excavatum (PE) is the most commonly encountered chest wall deformity which comprises one out of 1,000 live births. Depression of the anterior chest wall due to posterior angulation of the sternum and costal cartilages results in compression of internal thoracic organs as well as aesthetically unpleasant appearance. Multiple surgical techniques have been developed to correct this condition. Ravitch procedure, the technique including the excision of all deformed costal cartilages, division of intercostals bundles from the sternum, and transverse sternal osteotomy, was proposed in 1949 and most widely applied until recently. The Wada technique, principally sternal turnover, has been an alternative procedure. Those invasive techniques involve tedious and bloody operations resulted in a permanent defect of costal cartilages or contracture of the chest wall. Most importantly, a large, unsightly operative scar at the anterior chest is aesthetically dissatisfying. In this study "Minimally Invasive Surgery for Pectus Excavatum: Park Technique" was explained.

Keyworld

Pectus Excavatum; Minimally Invasive Surgery; Park Technique

DOI: 10.4328/JCAM.518 Received: 03.12.2010 Accepted: 03.12.2010 Printed: 01.09.2011 J Clin Anal Med 2011;2(3):198-204
Corresponding Author: Hyung Joo Park, Department of Thoracic and Cardiovascular Surgery, Korea University Medical Center, Korea.
E-mail: hyjpark@korea.ac.kr

Inroduction

Pectus excavatum (PE) is the most commonly encountered chest wall deformity which comprises one out of 1,000 live births. Depression of the anterior chest wall due to posterior angulation of the sternum and costal cartilages results in compression of internal thoracic organs as well as aesthetically unpleasant appearance.

History of Surgical Correction of PE

Multiple surgical techniques have been developed to correct this condition. Ravitch procedure, the technique including the excision of all deformed costal cartilages, division of intercostals bundles from the sternum, and transverse sternal osteotomy, was proposed in 1949 and most widely applied until recently. The Wada technique, principally sternal turnover, has been an alternative procedure. Those invasive techniques involve tedious and bloody operations resulted in a permanent defect of costal cartilages or contracture of the chest wall. Most importantly, a large, unsightly operative scar at the anterior chest is aesthetically dissatisfying.

New Minimally Invasive Technique

In 1998, Donald Nuss first reported a minimally invasive repair technique revolutionizing pectus repair. The procedure requires only two small incisions made on the lateral aspect of the chest, through which a curved metal bar is inserted retrosternally and then flipped to correct the chest wall depression. This new method has just opened a new era of pectus excavatum repair by providing a much less bloody and cosmetically superior option to patients and surgeons alike (Figure 1).

The Learning Curve

The author started the minimally invasive pectus repair in 1999, only two years after Nuss. Throughout the world, mainly in the USA as well as in Korea, the learning curve for this new technique has been quite steep. A delightful success for the first few cases of the original Nuss procedure was gloomed by a series of disappointing failures soon after that. Complications of the procedure, such as internal organ injury, bar rotation and others still plagued surgeons adopting this new strategy.

Main reasons for this failure have proven to be that the archetype Nuss technique has limitations in patients with asymmetric morphology and older patients with stronger heavier thoraces as well as defective bar fixation. Surprisingly, as much as 42% of pectus excavatum patients exhibit an asymmetric or complex (depressions and elevations) type of chest wall morphology. Nevertheless, the original technique proposed by Dr. Nuss is merely a blind approach by always applying symmetrically shaped bars to all types of pectus excavatum regardless of its morphologic characteristics. Consequently, outcomes failed to achieve symmetric correction. Surprisingly this blind approach is still prevailing in the USA and other countries.

Emerging of Park Technique

In initial experiences worldwide, especially in the USA, high complication rates such as pneumothorax, bar dislocation and consequent reoperation, were highly criticized. In addition, adults' heavy chests could not be effectively managed with this technique. Therefore, severe asymmetry and adults were considered no good candidate or even contraindicated for this procedure.

Accordingly, my journey on the pectus surgery pursued through a trailblazing path to overcome the problems raised from this raw Nuss technique. This process began with a meticulous assessment of individual chest wall topography and ended up creating a morphological classification. Based on the precise morphological analysis, targets that needed correction were identified. Then these targets were incorporated into the hinge point selection and bar bending process where I created an asymmetric or complex shaped bar (seagull, compound, etc.) matching the patient's contour. This has been the first and most important step in acquiring post-repair symmetry.

Another big issue in early experiences worldwide was bar dislocation. Because of the enormous pressure exerted on the bar after its insertion, bar dislocation is a menacing problem that results in defective correction or total failure of the procedure. Fixation of the bar to adjacent subcutaneous tissue, as proposed in Nuss technique, simply does not suffice except in highly selected pediatric patients with less severe and symmet-

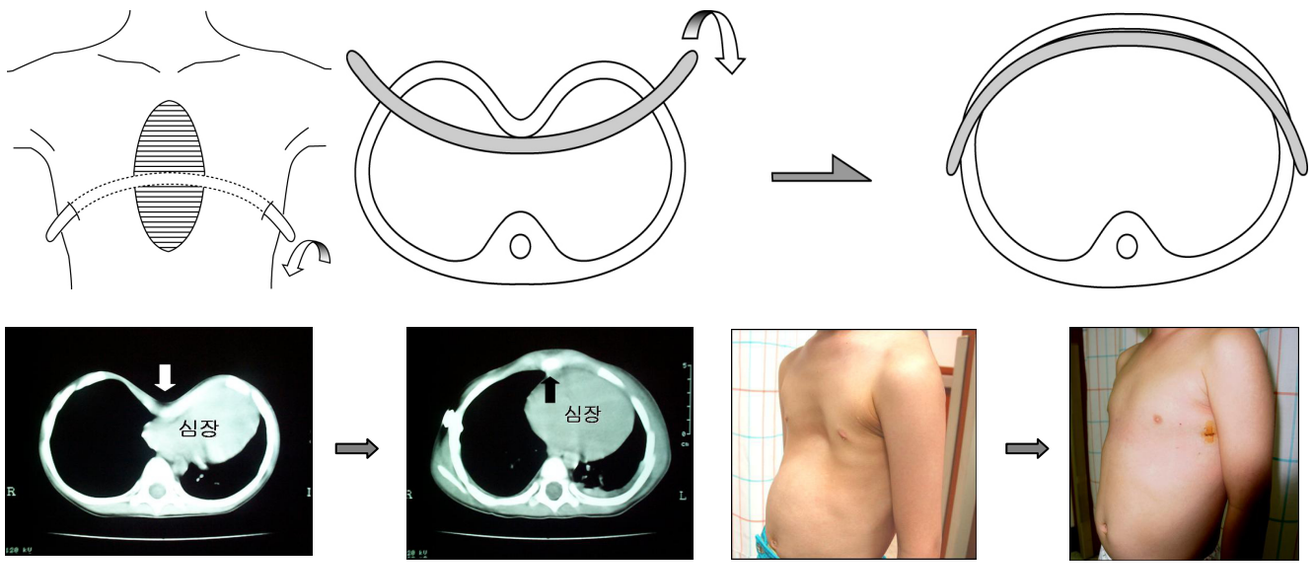

Figure 1. The new minimally invasive pectus excavatum repair technique proposed by Nuss

ric morphology.

As a first generation of this new procedure, the author's initial experience was a dreadful battle with various asymmetries and heavy adult patients. However, with aforementioned morphology-oriented repair principle and additional troubleshooting techniques, ultimately a variety of complex morphology could be repaired successfully.

Theories of Park Technique (MM-MT-TERCOM)

1. Morpholgical Classification

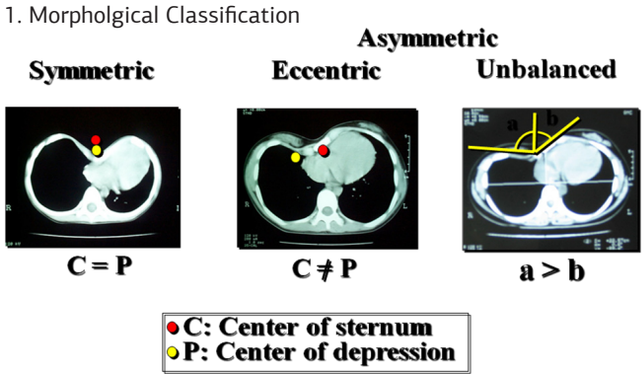

MORPHOLOGICAL CLASSIFICATION

1. Symmetric	2. Asymmetric
A. classical type	A. eccentric
	1. focal type
B. broad flat type	2. broad flat type
	3. long canal type*
	B. unbalanced
	C. combined

* Grand Canyon type

2. Multiple Momentum Theory (MM Theory)

Many times a complex morphology encompassing "excavatum-carinatum combination, Type 2C" is met in repair. In these cases, single momentum approach that is focusing only on elevating the depressed portion cannot avoid further elevation of the protruded portion. To solve this problem, discovering a role of negative momentum in the lever action of the pectus bar, which compresses the hinge point, can be the sole solution for minimizing the protrusion and achieving an eventual symmetric correction.

3. Multiple Target Approach (MT Approach)

As mentioned above in MM Theory, in repair of chest wall deformities, it is common that the target to be corrected is not a single depression, but various combinations of multiple depressions and/or protrusions of the chest wall. Having an eye for recognition of each and every factor of the deformity is the first step to a solid repair strategy.

4. Terrain Contour Matching System (TERCOM)

Once the multiple targets are set, all these targets must be reflected in the pectus bar shaping to correct every element of the deformity. I have come up with the easiest way to do it: the "Terrain Contour Matching" which is a fitting of the bar to the chest wall undulations, which makes the bar of exact mirror image.

Terrain Contour Matching (TERCOM) on the eccentric-unbalanced type of asymmetry. A, Topography (depressions or protrusions) of the chest wall is precisely reflected on the bar in the process of bar shaping. The apex of the bar (A) corresponds to the point of depression (D), and a notch (N) is created in the bar at the point of protrusion (P) between both hinge points (H). B, Bar is bent to an asymmetric (A)-seagull (N) shape, according to the TERCOM system, as the mirror image of the chest wall configuration.

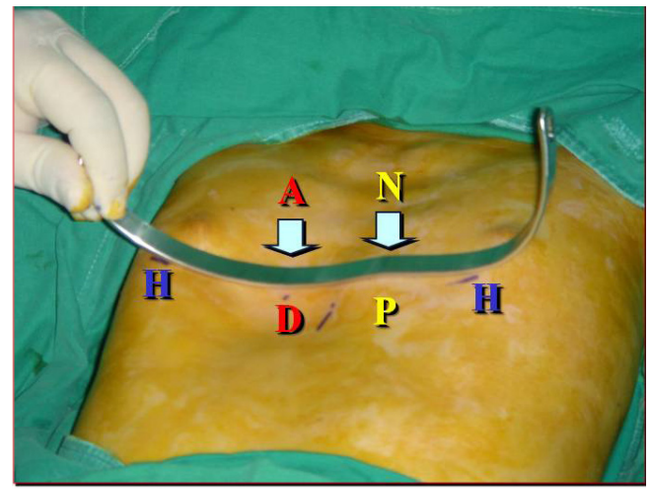

5. Bar Dislocation Mechanism

Through my research of each case of bar displacement, it is proven that there are three mechanisms of bar dislocation. First, "bar flipping" is returning of the bar into its original position before rotation. It indicates the repair a complete failure. Second, "sliding of the bar" is a lateral sliding toward the left or right side according to asymmetry of the depression. Last, "hinge point disruption" is a strip of intercostal muscle structure at the hinge area which occurs when correcting heavy chest depressions. Appropriate remedies for each mechanism were proposed and applied by the author.

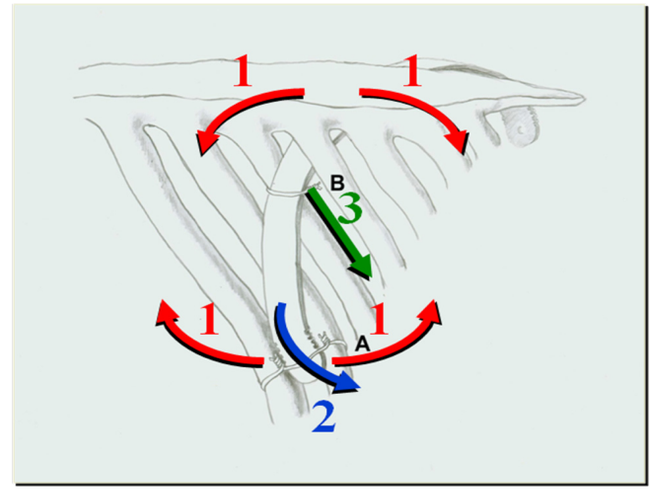

3 Mechanisms of bar dislocation

1. Flipping; 2. Lateral Sliding; 3. Hinge Point Disruption

6. New CT Indices

To assess the degree of depression and asymmetry in a different angle, new indices utilizing CT scan was created by the

author. These are also useful tools to verify whether the repair is correct.

$$\text{1. Depression Index (DI)} = \frac{b}{a}$$

$$\text{(CT Index (Haller Ix, HI))} = \frac{c}{a}$$

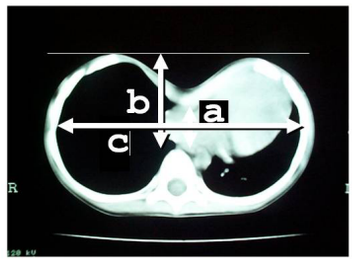

$$\text{2. Asymmetry Index (AI)} = \frac{b}{a}$$

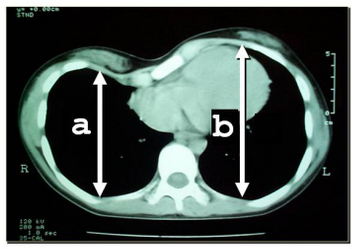

$$\text{3. Eccentricity Index (EI)} = \frac{b}{a}$$

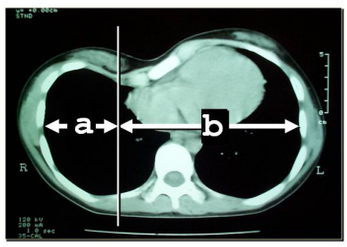

$$\text{4. Unbalance Index (UI)} = \frac{\alpha}{\beta}$$

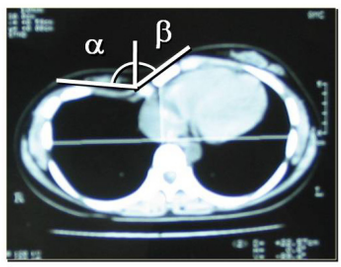

New Computerized Tomogram Indices

Park Technique (The Second Generation Techniques)
Surgical Techniques

A patient is placed in supine position and both arms are freely hung on overhead slings to avoid arm stretch. A pectus bar shaping is performed on the operating table by the principal surgeon (HJP), which makes it custom-fit to the patient's chest wall morphology. One centimeter skin incisions are made on both mid-axillary lines. An introducer or the pectus clamp (Biomet Microfixation, Jacksonville, FL, USA.) was passed through the mediastinum with a tactile approach, or recently, specially designed video-scope guided approach (Pectoscope). A guide (20 Fr chest tube) followed by the bent bar is passed through. By rotating the pectus bar, the convexity of the bar lifts the depressed chest wall. Both ends of the pectus bar and hinge points are fixed to the adjacent ribs with pericostal sutures or recently with Claw Fixators. Hemo-vac catheters are inserted in the subcutaneous pockets around the pectus bar and/or pleural cavities. In cases of adults, teenagers, or patients with severe depressions, to avoid the heart injury and make the procedure easier, the Crane system is utilized to elevate the sternum before passing the introducer.

1. Bar Shaping

According to the morphologic classification and TERCOM system, the bar is tailor-made for each patient. The asymmetric bar is designed for eccentric asymmetry, seagull bar for unbalanced asymmetry, and combination of both for complex morphologies.

Principally, to elevate the asymmetric chest wall depression selectively, convexity was localized to the corresponding portion of the bar (asymmetric bar), whereas to avoid the further elevation of the protruded part of the chest wall, a notch was created at the portion of the bar (seagull bar).

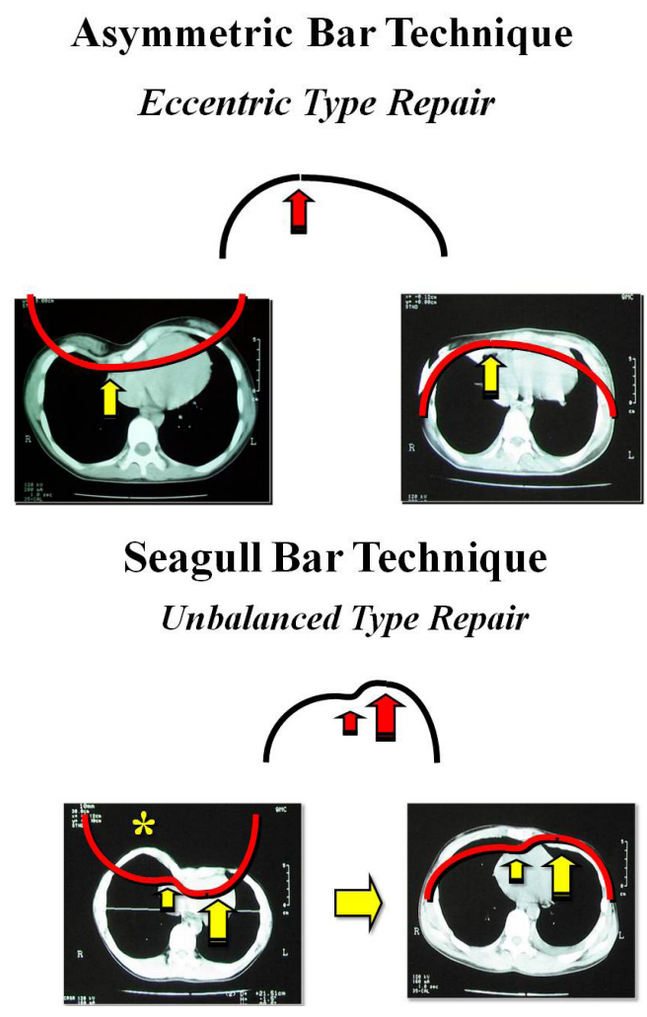

2. Bar Fixation Technique (Multipoint Fixation, MPF)

Evolution progressed over a period in early experience and finally the multipoint fixation to the corresponding ribs by means of pericostal sutures (wire or absorbable) at the end of the bar plus

hinge point(s) (End-hole fixation + Hinge point fixation) settled as a fixation of choice. However this approach has been in the process of replacement by a recent invention – a new sutureless fixation device, the "claw fixator."

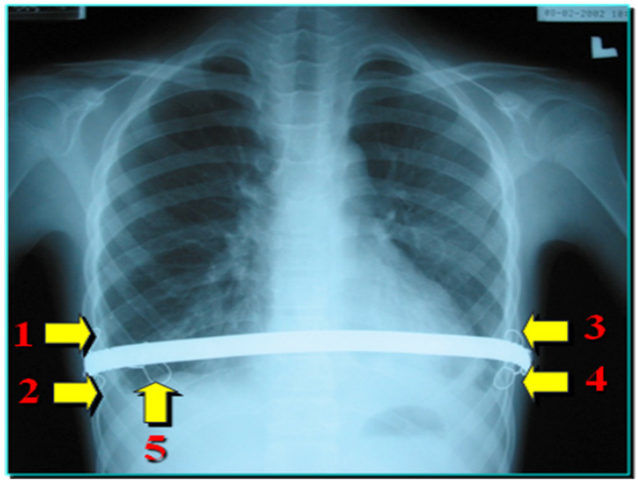

Multiple point Fixation Technique (5-Point Fixation): Pericostal wire or absorbable sutures

End-Hole (1-4) and Hinge Point Fixations (5)

3. Through-the-Skin Suture Technique (TTS)

Through-the-skin suture technique is a specialized technique for pericostal bar fixation, which is the entire suturing process is performed outside the small lateral incisions for bar insertion. First the targeted rib is first palpated and the suture needle is pierced directly through the overlying skin, passed around the rib and taken out, once again, through the skin. Then the sutured wires are then retrieved via subcutaneous dissection and finally pulled out through the incision. The hinge point fixation suture is made with the same technique. Pericostal sutures are passed through the end-hole of the bar and tied within the incision. With this trick, the skin incision remains small (1 cm), the size just allows the bar passage after all pericostal fixation sutures are made.

4. Techniques for Adults

This selected group of patients needs a special care during repair and in postoperative care. The most typical problem is that the adults' heavy and stiff chests cannot be elevated with a conventional pectus bar. In addition, the hinge system consisted of intercostal muscle bundles is not strong enough to sustain the bar for those heavy chests. To prevent intercostal muscle stripping and flattening of the shaped bars, the "crane technique" and "a compound bar" were instituted. Those are the milestone techniques to make the repair possible for adult patients.

The "crane technique" is elevating the depressed sternum prior to rotating the bar in order to alleviate the pressure on the bar and hinge points. Briefly the technique employs a wire suturing to the bony tissue on the xiphi-sternal area or other portion of the sternum as necessary and lifting the wire suture and the sternum by an operating table-mounted retractor system.

In the procedure, flipping the bar overzealously can result in major internal organ injury as well as tearing of the intercostals muscles at the hinge points resulting in insufficient chest wall elevation. The "crane" plays a paramount role at this stage of the operation. The crane elevates the chest wall off the internal organs to allow safe passage of the clamp and bar. Flipping the bar is much easier and hinge point degradation is prevented as well.



Compound bar: combination of two bars

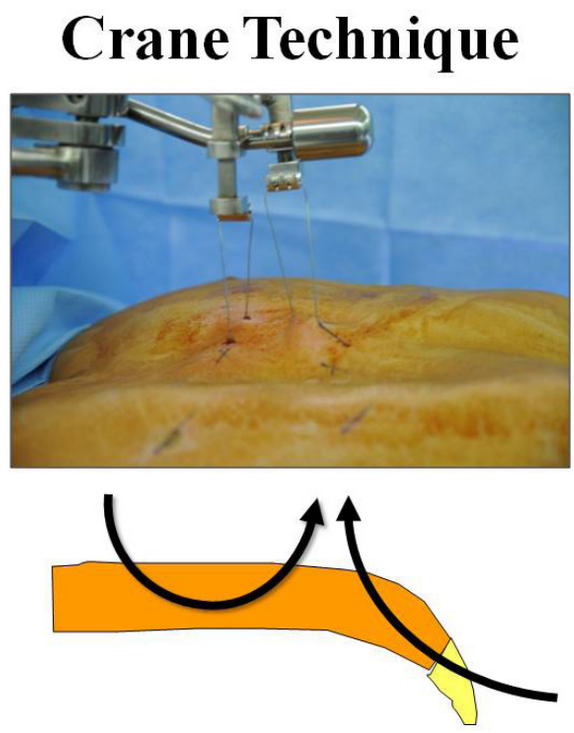

The Crane Tchnique

5. Crest Compression Technique

The crest compression is the technique utilizing the "negative momentum." The bar actively compresses protrusions by placing the hinge point exactly on the crest. The compressing pressure was generated by a lever-action when rotating the bar on the crest which serves as a pivot.

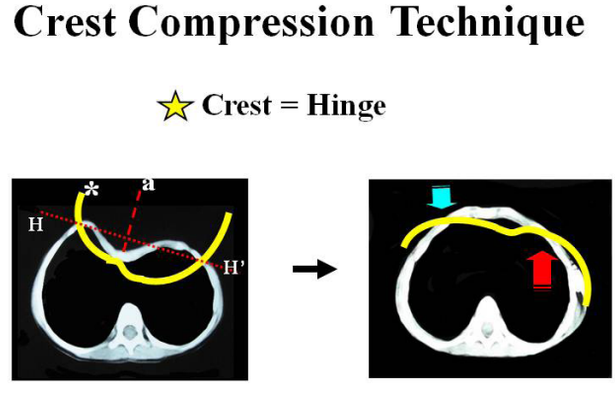

The crest compression technique

6. Parallel Bar Technqiue

When a single bar cannot elevate the entire depression since the depression extends to the level of clavicle, an additional bar at the upper chest can be used. In parallel bar technique, The main (lower) bar insertion point corresponds to the main depression, generally at 1 or 2 intercostal spaces below the nipple (6th to 7th intercostal space at the anterior axillary line). The second (supplementary) bar is usually positioned above the nipple (3rd or 4th intercostal space at the anterior axillary line).

Results

The single surgeon's experience with 1,526 pectus excavatum patients between August 1999 and September 2010 were analyzed. Minimally invasive repair with the author's technique evolved chronologically were applied to all and no patient was precluded from the repair due to morphological reasons.

Age ranged from 16 months to 53 years (mean of 10 years and median of 8 years). Among them, 341 patients (22.4%) were adults (age >/=15 years). Male to female ratio was 4.2. Symmetric type was 58.2% and asymmetry was 41.8%.

The symmetric bar (n=917, 60.1%), asymmetric bar (n=609, 39.9%), seagull bar (n=275, 18.5%), parallel bar (n=259, 17%), and crest compression (n=156, 10.2%) techniques were used. The crane technique was employed for adult patients to elevate ossified and heavy chests, or for severe depressions of any age to facilitate the procedure (n=511, 33.5%).

To assess post-repair residual depression, asymmetry, and eccentricity, CT scan-calculated indices were utilized. All pectus indices were decreased after repair: DI (pre 2.89 to post 1, $p<0.01$), AI (pre 1.11 to post 1.03, $p<0.01$), and EI (pre 1.69 to post 1, $p<0.01$).

Total complication rate was 12.8% but major complication rate was 3.2%. Reoperation rate was 2.5%.

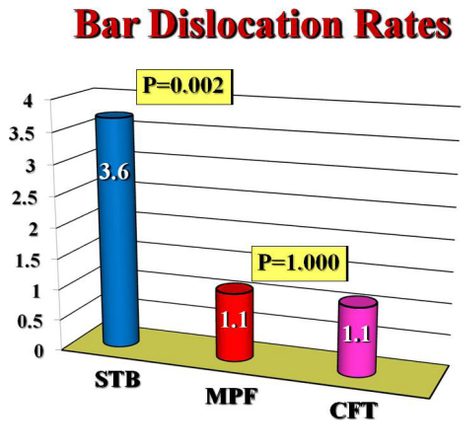

Bar dislocation rates by Fixation Techniques
STB: stabilizer(conventional); MPF: multiple; Point Fixation Technique; CFT: Claw Fixator

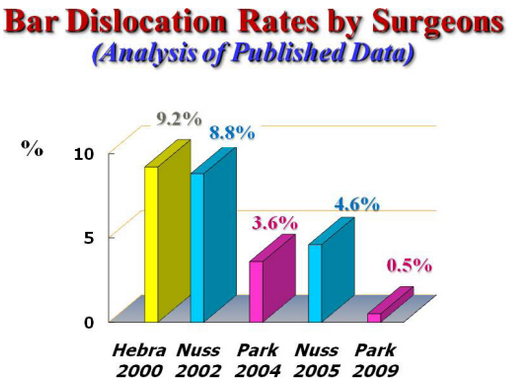

Bar dislocation rates by Surgeons

Park Technique II (The Third Generation Techniques)

1. Internal Visualizing Device: The "Pectoscope"

In this minimally invasive approach, risk of major internal organ injury such as cardiac perforation and devastating hemorrhage while passing the clamp past the lungs and heart is inherent. Use of video-scopic instruments has been instituted to assist in the safe passage of the clamp, but this usually requires enlarging the incision or making additional wounds. Furthermore, this conventional equipment provides barely a limited view to the compressed and displaced heart. In patient with very deep depression, it is impossible to obtain a reliable view to a critical point where the chest wall tightly contacts the heart.

A new device, the "pectoscope", therefore developed in order to fulfill this crucial inevitability. This consists of a curved hollow metal sheath with an observation deck at the tip, which accepts a flexible scopic device inside. Importantly this device has 3 functions all together in one piece (the Trinity device), specifically visualization, dissection, and a guide. The surgeon can view the entire passage directly while dissecting with this device between the depressed chest wall and the heart, and then finally use it as a guide. This device guarantees the safety 100% without the need for additional instruments or incisions, and ultimately making the procedure safe, easy and comfortable.

2. A New Bar-Fixation Device: The "Claw Fixator"

The Multi-point Fixation (MPF) method has successfully prevented bar dislocation in over 800 consecutive patients including asymmetry and adults and therefore made an enormous contribution to settle this procedure effective. However, for most surgeons, a blind wire suture placing around the rib cannot be always easy and is not comfortably reproducible at times. Also this was not without complications such as transient pneumothorax. Thus this technique also needs to be updated to fit for modern era of technology.

This new fixation device, the "Claw Fixator" is very small to handle easily compare to conventional stabilizer and eliminates invasive suture technique completely from the procedure. The technique includes small plates and screws that are placed at the end of the bar and hooked to nearby ribs to stabilize the bars. A recent study ongoing has revealed that in pediatric patients, the efficacy of "Claw" is equivalent to the MPF technique even with lower complication rates, so that now its applications are expanding to adult patients.

3. The Hinge Plate

The hinge plate (The Prime Med Co. Seoul, Korea) is a metal strip with a concave cradle to embrace and support the pectus bar at the hinge points. The hinge plate is designed to prevent all the forces generated from the lever action of the pectus bar and all the vectors exert to sustain the pectus bar in the hinge. All the forces creating intercostal muscle stripping (hinge destruction) are three directional vectors. Vector 1 and 2 that are pressures directing downward due to the chest wall weight and vector 3 is a force exerting antero-downward sliding along the lower rib in the intercostal space.

The cradle has a round bottom adjustable to the pectus bar direction and works for protecting the hinge against the vectors 1 and 2. A spur is fashioned at the lower end of the cradle to block the vector 3.

References

1. Park HJ, Lee SY, Lee CS, et al. The Nuss procedure for pectus excavatum: an evolution of techniques and results on 322 patients. Ann Thorac Surg 2004;77:289-95.
2. Park HJ, Lee SY, Lee CS. Complications associated with the Nuss procedure: analysis of risk factors and suggested measures for prevention of complications. J Pediatr Surg 2004;39:391-5.
3. Park HJ. Technical innovations in minimally invasive approach for pectus excavatum: a paradigm shift through 630 patients. Innovations 2007;2:25-8.
4. Lee CS, Park HJ, Lee SY. New computerized tomogram (CT) indices for pectus excavatum: tools for assessing modified techniques for asymmetry in Nuss repair. Chest 2004;126(Suppl.):777S.
5. Park HJ, Chung WJ, Lee IS, Kim KT. Mechanism of bar displacement and corresponding bar fixation techniques in minimally invasive repair of pectus excavatum. J Pediatr Surg 2008;43:74-8.
6. Park HJ, Lee IS, Kim KT. Extreme eccentric canal type pectus excavatum: morphological study and repair techniques. Eur J Cardio-Thorac Surg 2008; 34:150-4
7. Park HJ, Jeong JY, Jo WM, Shin JS, Lee IS, Kim KT, Choi YH. Minimally Invasive Repair of Pectus Excavatum: A Novel Morphology-Tailored Patient-Specific Approach. J Thorac Cardiovasc Surg 2010;139:379-386 8. Park HJ, Jeong JY, Kim KT, Choi YH. Bar shaping method for minimally invasive pectus excavatum surgery: to expand its role to asymmetries and adults. (in press)
9. Park HJ, Jeong JY, Kim KT, Choi YH. A New videoscopic device to avoid cardiac injury in minimally invasive pectus excavatum repair: the Pectoscope. (in press)
10. Park HJ, Jeong JY, Kim KT, Choi YH. Hinge Reinforcement Plate for Adult Pectus Excavatum Repair: A Novel Armamentarium for Minimally Invasive Technique (in press)