Editör'e Mektup
JCAM
Letters to Editor

Axillary Pilonidal Sıinus of a Hirsute Woman

Hirşutizmli Bir Kadında Aksiller Pilonidal Sinüs

Ilker Sengul[1], Demet Sengul[2], Gamze Mocan[3]
[1]Department of General Surgery, Giresun University Faculty of Medicine, Giresun,
[2]Department of Pathology, Prof. Dr. A. Ilhan Ozdemir State Hospital, Giresun,
[3]Division of Cytology, Department of Pathology, Hacettepe University Faculty of Medicine, Ankara, Turkey

To the editor

The terminology of pilonidal sinus was firstly used by Hodges et al [1] in 1880 after 33 years from Anderson et al who founded a hair in a sacrococcygeal ulcer [2]. Although it is seen mostly in sacrococcygeal area, it may also occur in seldom anatomical localizations such interdigital area, forehead, scalp, umblicus, clitoris, penis, abdomen, neck and axilla [3].

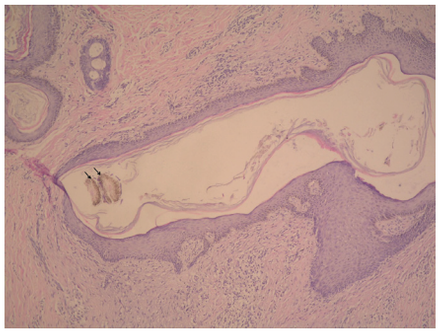

Figure 1. Sinus tract and the section of the hair inside it (arrows) (H & E, original magnification, 10x20)

We had presented a hirsute Turkish woman aged 25 in November 2009 with the history and complaint of the intermittent small amount of leakage from her right axilla during the past year. On the physical examination, one small sinus sized 2 mm in diameter in her right axilla was detected. However, it was defined at neither the intergluteal sulcus and nor the other parts of the body. The surgical treatment was performed via eliptic skin incision. Following the total surgical excision the histopathological evaluations confirmed the preassumptive diagnosis of axillary pilonidal sinus (Figure 1, 2). Surgical treatment gives to appropriate choice of treatment partially for the disease having one or two sinuses, besides enabling to absolute histopathological diagnoses. Any perioperative or postoperative complication and recurrence has not been detected during the 46 months follow-up [3].

Sion-Vardy et al presented two similar cases of axillary pilonidal sinus one month later, in December 2009. They were a 19-year-old male having the prediagnosis of sebaceous cyst and 22-year-old female having the prediagnosis of lymph node. Both patients had given a history of axillary shaving with razor. Sion-Vardy et al mentioned in their study about that the related previously reported cases were non-hirsute healthy women, aged 17-30 years. However, our presented case in November 2009 is a hirsute 25-year-old woman [4].

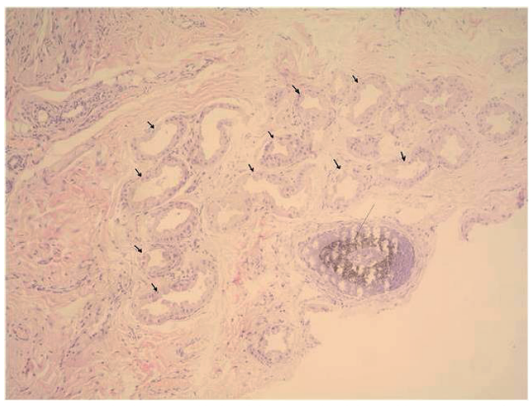

Figure 2. Apocrine gland structures (thick and short arrows) and the neighbouring section of the hair (thin ang long arrow) (H & E, original magnification, 5x10)

So, according to our point of view, the awareness of the probability of a pilonidal disease even in seldom locations like groins of axilla for both hirsute and non-hirsute patients is very important. The malignant degeneration of the disease is very rare, but when it occurs it has much more poor prognosis comparing with squamous cell carcinoma and regular nonmelanoma skin cancer [3].

References

1. Hodges R. M. Boston Med Surg J 1880;103:485.
2. Anderson A. W. Boston Med Surg J 1847;36:74.
3. Sengul I, Sengul D, Mocan G. Axillary pilonidal sinus: A case report of a rare location of pilonidal sinus. North Am J Med Sci 2009;1:316-318.
4. Sion-Vardy N, Osyntsov L, Cagnano E, Osyntsov A, Vardy D, Benharroch D. Unexpected location of pilonidal sinuses. Clin Exp Dermatol 2009;34:e599-601.

DOI: 10.4328/JCAM.446 Received: 15.10.2010 Accepted: 26.10.2010 Printed: 01.01.2012 J Clin Anal Med 2012;3(1):130
Corresponding Author: Ilker Sengul, General Surgery, Vice Dean's Office, The ounder Chairman of Department of General Surgery, Deanery of Giresun University Faculty of Medicine, 28100 Giresun / Turkey.
Rectorship : +90 454 310 10 00 Deanary: +90 454 214 03 69 GSM: +90 530 885 00 50 GSM-Belgium: +32 484 53 62 61 Fax: +90 454 214 02 47 E-Mail: dr.ilker52@mynet.com, ilker.sengul@giresun.edu.tr