Flap Lymphedema after Successful Reconstruction of the Chronic Inguinal Wound with a Vertical Rectus Abdominis Flap (VRAM)

Kronik İnguinal Açık Yaranın Vertikal Rektus Abdominus Flebi (VRAM) ile Onarımı Sonrasında Oluşan Flep Lenfödemi

Flep Lenfödemi / Flap lymphedema

Yalçin Kulahci, Celalettin Sever, Rahmi Evinç
Department of Plastic and Reconstructive Surgery and Burn Unit,
Gülhane Military Medical Academy and Medical Faculty, Haydarpasa Training Hospital, Istanbul, Turkey

Özet

Geniş ve komplike olan açık yaraların onarımı rekonstrüktif cerrahların en büyük sorunlarından biridir. Lokal flepler, uzak flepler ve serbest flepler açık yaraların debridmanından sonra uygulanacak en iyi onarım yöntemleridir. Vertikal rektus abdominus flebi (VRAM) inguinal bölge, gluteal bölge, perine, gövde ve memenin onarımında başarılı olarak uygulanmıştır. Biz bu olgu sunumunda, inguinal bölgesindeki açık yarası VRAM ile başarılı bir şekilde onarılan ancak flep lenfödemi oluşan bir olguya dikkat çekmek istedik. Yaptığımız literatür araştırması sonucunda daha önce rapor edilmiş flep lenfödemine ait bir literatür mevcut değildir.

Anahtar Kelimeler

Vertikal Rektus Abdominus Flebi; Flep Lenfödemi; Açık Yara

Abstract

The reconstruction of extensive and complex wounds represents a challenging problem for reconstructive surgeon. The reconstructive options to provide coverage following debridment of these complicated wounds are local, distant flaps, or freetissue transfer. Vertical rectus abdominis flaps have been used successfully to repair defects in the groin, hip, perineal, trunk, and breast regions. We encountered flap lymphedema after successful reconstruction of the chronic inguinal wound with a vertical rectus abdominis (VRAM) flap. As far as were able to ascertain, there is no report in the literature related to flap lymphedema.

Keywords

Vertical Rectus Abdominis Flap; Flap Lymphedema; Wound

DOI: 10.4328/JCAM.486 Received: 20.11.2010 Accepted: 30.11.2010 Printed: 01.07.2012 J Clin Anal Med 2012;3(3): 339-341
Corresponding Author: Celalettin Sever, GATA Haydarpaşa Eğitim Hastanesi. Plastik ve Rekonstrüktif Cerrahi Servisi. Selimiye Mah. Tıbbiye Cad. 34668 Kadıköy, İstanbul, Turkey. T.: +90 2165422656 E-Mail: drcsever@hotmail.com

Introduction

The rectus abdominis musculocutaneous (VRAM) flap has been widely used in reconstructive surgery. The pedicled VRAM flap provides a reliable tool for coverage of large soft-tissue defects of the chest wall, groin, hip, and perineum even in a high-risk population, in which a safe and fast forward flap procedure is the primary reconstructive goal. Numerous advantages of vascularized muscle transfer, such as improved healing time, lowered bacterial counts, improved antibiotic delivery, increased local oxygen tension and enhanced ability of macrophages to combat infection, have been reported. In addition, the muscle flap also provides tissue bulk to obliterate dead space and diminishes the risk of recurrent infection [1]. Furthermore, the successfully transferred myocutaneous flap may also improve lymph circulation and may alleviate obstructive lymphedema [1,2].

Case Report

A 64-year-old man was referred to our clinic with a chronic right inguinal wound that had been present for 2 years. According to the patient's history, hematoma formation occurred after coronary angiography and caused skin necrosis and the appearance of an open wound. In addition, the patient was suffering from right lower extremity secondary lymphedema. He was managed with pneumatic compression therapy for 60 minutes, every 6 hours. Physical examination revealed a 10x12x5 cm soft-tissue defect surrounded by severely scarred tissue. Due to lymphedema of the leg, the ipsilateral inferior epigastric vessels may have been involved in this case. Thus, after wound care with serial debridement, VAC therapy and antibiotherapy, the defect was reconstructed with contralateral VRAM flap. No complications were encountered; the flap healed completely and the patient was discharged ten days after the operation (Figure 1a,b). There were no complications at the first visit of the patient 1 month after surgery (Figure 1c). Lymphedema therapy with a pneumatic compression device was not performed throughout the postoperative hospitalization period, but it was resumed after discharge. Interestingly, two months after the operation, the patient was admitted to our department with complaints of
swelling and redness due to the VRAM flap transfer (Figure 2a). When the patient was admitted to our department, complete blood count and wound culture were performed. White blood cell count was 6x103/μL, and no bacterial colonization was isolated. Upon physical examination, flap skin was sloughed; the flap was firm, edematous and red. When the flap was palpated, there was no regional temperature increase, which was considered as a sign of infection. Furthermore, there was edema without godet sign. All of these signs led us to consider flap lymphedema. The presence of lower extremity lymphedema also supported our diagnosis. The sloughed skin was related to poor wound care on the patient's part and healed a few days later. To reduce flap lymphedema, extremity elevation, massage therapy and pneumatic compression therapy with increased intervals were recommended to the patient. During the follow-up period, flap lymphedema was significantly decreased, and the patient was satisfied with the results (Figure 2b).



Figure 1. The appearance of the right inguinal soft-tissue defect after debridement (A). Appearance of the flap 10 days after the operation (B). Appearance of the patient 1 month after surgery. The flap survived completely, and the wound healed uneventfully (C).

Discussion

For the last decades, VRAM flap has contributed to the efficient reconstruction of the tissue defects which need a great amount of cutaneous and muscular tissue. Many flaps have been described with each one having specific advantages. The rectus abdominis flap may be designed as variously shaped flaps, i.e., a verticalshaped type, a transverseshaped type, and an obliqueshaped type. These flaps can be used for reconstruction of a variety of soft-tissue defects in the different pathology and in various anatomic areas. Simultaneous flap elevation with preparation of the recipient site, easy dissection, minimal donor-site morbidity, and a constant vascular anatomy with long pedicle are advantages of the flap.

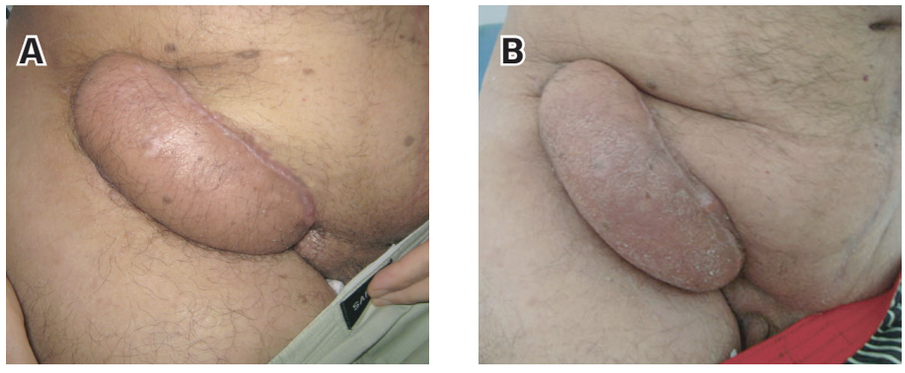

Figure 2. The appearance of VRAM flap lymphedema two months postoperatively. Note the swelling and redness at the transferred VRAM flap (A). After extremity elevation, massage therapy and pneumatic compression therapy with increasing intervals, flap lymphedema was significantly reduced (B).

Soft-tissue defects in the thigh and groin region are distinct with regard to anatomy,
complication rates, and reconstructiveoptions. It is difficult to maintain a clean and dry wound in this region because the wound tension increases substantially here. Thus, these wounds have a higher percentage of complications than other areas. Reconstruction of groin region defects requires tissue in sufficient quantity to fill the dead space for definitive coverage. In the case presented here, the contralateral rectus abdominis myocutaneous flap was chosen for coverage of inguinal wound. It is accepted that when there is doubt regarding donor vessel patency or if there is leg lymphedema on the ipsilateral side, the flap from the healthy contralateral side should be considered. Flap harvesting should be performed from a site that is far away from the wound [1]. Qi et al. reported on a similar case with a right femoral wound and lymphedema of the right leg; the authors used contralateral side rectus abdominis myocutaneous flap for reconstruction [1]. They noted that the lymphedema was significantly reduced and that the patient was quite satisfied with the outcome. Contrary to their findings, lymphedema of the leg was not reduced in the present study. In addition, flap lymphedema developed in the transferred VRAM flap. Use of a contralateral VRAM flap for repair of the groin/femoral wound has not been widely reported. In the literature, Khainga reported one case for whom the contralateral extended rectus abdominis myocutaneous flap was used for groin wound reconstruction after the left femoral aneurysm bypass procedure with prosthetic vascular graft had failed [3]. Parret et al. reported 18 cases of contralateral rectus abdominis myocutaneous flaps for irradiated thigh and groin defects [4], and Qi et al. reported 13 cases of contralateral rectus abdominis myocutaneous flaps for complex groin wounds [5]. Furthermore, Parret et al. reported on four patients with acquired lower extremity lymphedema who were treated with a contralateral VRAM flap with an inferior cutaneous pedicle left intact to facilitate lymphatic drainage into the unaffected groin [2]. According to their preliminary study, transfer of a contralateral VRAM flap with an inferior cutaneous pedicle left intact to the groin of a lymphedematous leg improves lymphedema and decreases the incidence of cellulite [2]. Our experience with the presented approach to repair shows that the ipsilateral rectus abdominis flap should not be used if leg lymphedema is present and if the contralateral side is available. Furthermore, we suggest that when the contralateral side is considered for reconstruction, the inferior cutaneous pedicle of contralateral VRAM flap should be left intact during reconstruction of inguinal/femoral wounds if ipsilateral leg lymphedema is present.

References

1. Qi F, Gu J, Shi Y. Difficult groin reconstruction using contralateral rectus abdominis myocutaneous flap. Plast Reconstr Surg. 2008;121:147e-148e.
2. Parrett BM, Sepic J, Pribaz JJ. The contralateral rectus abdominis musculocutaneous flap for treatment of lower extremity lymphedema. Ann Plast Surg. 2009;62:75-9.
3. Khainga SO. Extended pedicle rectus abdominis myocutaneous flap for groin reconstruction: case report. East Afr Med J. 2006;83:575-9.
4. Parrett BM, Winograd JM, Garfein ES, Lee WP, Hornicek FJ, Austen WG Jr. The vertical and extended rectus abdominis myocutaneous flap for irradiated thigh and groin defects. Plast Reconstr Surg. 2008;122:171-7.
5. Qi F, Zhang Y, Gu J. Repairs of complex groin wounds with contralateral rectus abdominis myocutaneous flaps. Microsurgery. 2009;29:199-204