A Ruptured Gastrointestinal Stromal Tumor of Jejunum Causing Acute Abdomen

Akut Karın Tablosuna Neden Olan Jejunumun Rüptüre Gastrointestinal Stromal Tümörü

Perforated Gastrointestinal Stromal Tumor / Perfore Gastrointestinal Stromal Tümör

Atakan Sezer[1], Tamer Sagiroglu[1], Fulya Ozpuyan[2], Bahadir Erdogan[1], Ebru Tastekin[2]

[1]Department of Surgery, School of Medicine, Trakya University, Edirne, Türkiye.

[2]Department of Pathology, School of Medicine, Trakya University, Edirne, Türkiye.

The case report was presented as poster presentation in the congress of "17. Ulusal Cerrahi Kongresi" in Ankara at 26-29 May 2010.

Özet

Gastrointestinal Stromal tümörler, ince bağırsak tümörlerinin nadir çeşitleridir. İnce bağırsak tümörlerinin önde gelen semptomları arasında kanama, bağırsak tıkanıklıkları ve bağırsak veya tümör delinme ve yırtılmaları gelir. 61 yaşında bayan hasta 2 gündür süren bulantı, kusma ve karın ağrısı şikayetleri ile başvurdu. Karın bilgisayarlı tomografi incelemesinde ince bağırsak kaynaklı 2x5 cm'lik kitle tespit edildi. Explorasyonda Treitz ligamanının 45 cm distalinde jejunal bir anstan kaynak alan rüptüre bir tümör görüldü. Kısmi ince bağırsak rezeksiyonu ve primer anastamoz yapıldı. Histopatolojik ve immünohistokimyasal incelemede ince bağırsak kaynaklı gastrointestinal stromal tümör tanısı kondu. İmmunohistokimyasal incelemede neoplastik hücrelerde CD117, desmin ve CD34 antikorları ile kuvvetli boyanma saptandı. Postoperatif dönemde hastaya oral 400 mg/gün imatinib başlandı. Hastanın 6. ay kontrol tomografisinde nüks lehine bulgu saptanmadı. Klinisyenler uzun sağkalım sağlamak ve onkolojik cerrahi prensipleri uygun olarak yerine getirmek için bu nadir hastalığı akılda tutmaları gerekmektedir.

Anahtar Kelimeler

Gastrointestinal Stromal Tümör, İnce Bağırsak Tümörleri, Akut Karın.

Abstract

Gastrointestinal stromal tumors are the rare form of the small bowel tumors. The foremost symptoms of small bowel tumors are bleeding, obstruction, and perforation. A 61-year-old female was admitted with abdominal pain, nausea and vomiting lasting for 2 days. Computed tomography investigation revealed a mass of small bowel in 2×5 cm size. On exploration a perforated tumor originated from a jejunal segment 45 cm distal from the ligament of Treitz was identified. Segmental resection and primary anastomosis were performed. The histopathologic and immunohistochemical investigation demonstrated gastrointestinal stromal tumor arising from small bowel. Immunohistochemically, the neoplastic cells strongly stained with CD117, desmin, and CD34 antibodies. Postoperatively, the patient was treated by oral administration of 400 mg/day of imatinib. Surveillance abdominal computed tomography scan at six months was unremarkable. Physicians should be kept this rare entity in mind for prolonged survival and accurate treatment including oncologic surgery.

Keywords

Gastrointestinal Stromal Tumors, Small Bowel Tumors, Acute Abdomen.

DOI: 10.4328/JCAM.497 Received: 26.11.2010 Accepted: 08.12.2010 Publihed Online: 01/07/2012 J Clin Anal Med 2012;3(3):342-344

Corresponding Author: Atakan Sezer, Department of Surgery, School of Medicine, Trakya University, Edirne, Türkiye.

Phone: +902842357641 GSM: +9005324223840 Fax: +90 284 2352730 Email: atakansezer@hotmail.com

Introduction

Although the small bowels constitute the majority of gastrointestinal tract (GI), the tumors of the small bowel are rare entities (1 to 5% of GI). Adenocarcinoma, carcinoid, stromal tumors, lymphoma, endocrine tumors, and metastatic tumors are the pathologic types of small bowel neoplasms.[1] Gastrointestinal stromal tumors (GISTs) are mostly originated from the stomach. Jejunum and ileum are rare localization areas for GISTs. GISTs are difficult to diagnose and are often in advanced stage at the time of definitive treatment. The foremost symptoms of the GISTs are bleeding, obstruction, and perforation/rupture of the tumor. There are no clinical or radiological features of the GIST to differentiate from other tumors of the small bowel. Here in, a patient with the rupture of a GIST of the jejunum presented with acute abdomen is reported.

Case Report

A 61-year-old female was admitted with abdominal pain, nausea and vomiting lasting for two days. Her past medical history was unremarkable, and she was a healthy-appearing patient. Vital signs were normal within the blood pressure; 110/60 mmHg, pulse rate of 80 per minute and body temperature of 37.20C. Physical examination revealed tenderness and rebound on the lower quadrants. Initial laboratory examinations indicated normal values except an elevated leukocytes count as 19300/L. Plain abdominal X-ray showed a few air-fluid levels of small bowels. Abdominal ultrasonography demonstrated free fluid in Douglas pouch. Computed tomography investigation of the abdomen revealed a mass in 2x5 cm size originated from the small bowel. There was no metastatic lesion in solid organ or peritoneal surfaces (Figure 1). The patient referred to operation with an initial diagnose of small bowel mass and acute abdomen. On exploration a ruptured tumor originated from a jejunal segment, 45 cm distal from the ligament of Treitz, was identified. The tumor was located at the antimesenteric side of the jejunal wall. There was no association with the bowel lumen and ruptured area (Figure 2). Segmental resection of the jejunum containing the lesion and primary anastomosis were performed. The patient's postoperative course was uneventful and discharged at the seventh day. On macroscopic examination a ruptured stromal nodule was examined on the serosal surface of the resected small intestinal specimen. The cut surface was mild, hemorrhagic and necrotic in the center. Peripheral areas were hard and rubbery. Microscopically, a mesenchymal tumor was found on the serosal side of the small intestine. Muscularis propria and submucosal tissue were infiltrated by the tumor. Mucosa was unaffected. Histologically spindle shaped tumor cells with the oval nucleus without nucleoli were noticed. Mitotic index was accounting as 9/50 HPF. Immunohistochemical staining revealed diffuse cytoplasmic and focal membranous CD117 positivity, diffuse strong positivity for SMA, focal CD34 and S100 positivity. Desmin was negative on the tumor cells. Ki67 staining showed %9 intranuclear positivity. With these results gastrointestinal stromal tumor was the end diagnosis (Figure 3). The multidisciplinary oncosurgery team has decided not to proceed with any adjuvant treatment. Postoperatively, the patient was treated by oral administration of 400 mg/day of imatinib. Surveillance abdominal computed tomography scans at six months was unremarkable.

Discussion

In this paper, a gastrointestinal stromal tumor of the jejunum was reported in which the tumor was spontaneously ruptured into peritoneal space and presented with the acute abdomen. The small intestine tumors account for less than 1% of all gastrointestinal malignancies. Gastrointestinal stromal tumors are described as mesenchymal tumors of GI tract with a histologic pattern of spindle cell, epithelioid, and rarely pleomorphic morphology and immunohistochemical staining with CD117. The frequency of GISTs vary from 5-20/1,000 000 of the population and the possibility of malignancy is 20-30%. GISTs arise anywhere within the gastrointestinal tract. Approximately, 70% of GISTs arise in the stomach, with 20–30% originating in the small intestine and the remainder 10% occurring in the esophagus, colon, rectum, omentum, mesenteries, and retro peritoneum.[1,2] GISTs predominantly occur in middle aged or older with a median age of sixth decades. No sex or race predilection exists. They have distinctive histologic and clinical features that vary according to their primary site of origin. The clinical presentations of GISTs of small bowel are variable and depend on the tumor size and anatomic site. In the review of Miettinen and Lasota[3] the most common presentation of GIST is reported as GI bleeding. The tumors smaller than 2 cm in size are generally asymptomatic and larger tumors may present with upper abdominal pain, palpable intra abdominal mass, vomiting, weight loss, and perforation or rupture. In current case the patient has admitted with the acute abdomen due to rupture of a GIST of small bowel. Tumor rupture in small bowel presenting as acute abdomen is the rarest clinical presentation of GIST and the mechanism is unclear. Karagulle et al.[4] suggested that the reason of the perforation or rupture of GIST is the replacement of the bowel wall by tumor cells followed by necrosis, ischemia of the intestine due to tumor embolization, and increased intraluminal pressure caused by obstruction. The radiological di-

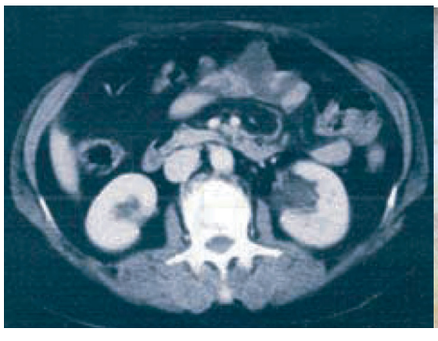

Figure 1. CT scan shows an extrinsic mass of a loop of small bowel.



Figure 2. Intraoperative view of the tumor. Tumor mass was adhered to anti-mesenteric border of small bowel. At the top of the tumor a ruptured area was present.

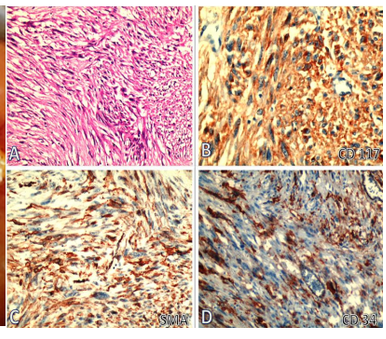

Figure 3. Low power view of the gastrointestinal stromal tumor of the small intestine. Note the transition of the submucosal and mural tumor with the normal intestine. Spindle shaped tumor cells with hiperchromatic hyperchromatic nucleus (H&E x 100). (A) Cytoplasmic and focally membranous CD117 positivity (IHC x 200). (B) SMA positivity on the tumor cells (IHC x 200). (C) CD34 positivity (IHC x 100). (D)

agnosis generally based on symptoms. Plain graphy or barium studies may direct physicians to the proper diagnose in case of obstruction or large masses in small bowels. Computed tomography or magnetic resonance investigation is useful in tumors larger than 2 centimeters.[5-7] Endoscopic examinations fail in the diagnosis of GISTs originated from the small intestine. GISTs are currently defined as CD117 positive spindle cell or epithelioid neoplasms with the minimal or incomplete myogenic or neural phenotype. Efremidou et al.[8] reported that in the immunohistochemical examination of the GIST the staining proportion is 100% for CD117, 70% for CD34, 20-30% for SMA, 10% for S100, and <5% for desmin. Like as in current case, the specimen contained spindle cells that stained strongly for CD117, CD34, and SMA. Surgery is the principal initial treatment for GISTs. Complete tumor resection with negative tumor margins was considered the only curative procedure for primary and non-metastatic tumors. The long term survival is 50% at best. These tumors are believed to be potentially malignant lesions with an average rate of 20–25% of gastric and 40–50% of small intestinal localization. Metastases commonly develop in the abdominal cavity and liver; rarely, in bones, soft tissues, and skin.[2,3,7] Prognostic factors for GISTs are the age, anatomic location, mitotic rate, and tumor size. Authors declare that mitotic rate and tumor size were considered the most reliable and consistent predictors of the outcome.[3,8] Chemotherapy and radiotherapy do not increase the survival time. Radiotherapy is indicated in intraperitoneal hemorrhage and maintaining analgesia in unresectable tumors. Imatinib, a selective inhibitor of tyrosinekinases, is a hope promising drug, which is the first effective treatment for non-resectable or metastatic GISTs. Furthermore, imatinib is indicated in intraperitoneal perforated or ruptured GIST due to the possibility of peritoneal soiling.[8] In current case, the patient has received imatinib 400 mg/day orally because of tumor rupture into peritoneal area and possibility of intraperitoneal dissemination.

Conclusion

As a conclusion, the non-diagnostic physical findings and insidious presentation of the small intestine originated GISTs, proper preoperative diagnosis is generally drudging. These tumors may be the cause of the acute abdomen due to the rupture of the GIST. Oncologic surgery principles including clear resection margins, resection without rupturing or spilling tumor should be done for prolonged survival.

References

1. Sunamak O, Karabicak I, Aydemir I, Aydogan F, Guler E, Cetinkaya S, et al. An intraluminal leiomyoma of the small intestine causing invagination and obstruction: A case report. Mt Sinai J Med 2006;73:1079-1081.
2. Bucher P, Egger JF, Gervaz P, Ris F, Weintraub D, Villiger P, et al. An audit of surgical management of gastrointestinal stromal tumours (GIST). Eur J Surg Oncol 2006;32:310-314.
3. Miettinen M, Lasota J. Gastrointestinal stromal tumors: pathology and prognosis at different sites. Semin Diagn Pathol 2006;23:70-83.
4. Karagülle E, Türk E, Yildirim E, Göktürk HS, Kiyici H, Moray G. Multifocal intestinal stromal tumors with jejunal perforation and intra-abdominal abscess: report of a case. Turk J Gastroenterol 2008;19:264-267.
5. Lupescu IG, Grasu M, Boros M, Gheorghe C, Ionescu M, Popescu I, et al. Gastrointestinal stromal tumors: retrospective analysis of the computer-tomographic aspects. J Gastrointestin Liver Dis 2007;16:147-151.
6. Spivach A, Zanconati F, Bonifacio Gori D, Pellegrino M, Sinconi A. Stromal tumors of the small intestine (GIST). Prognostic differences based on clinical, morphological and immunophenotypic features. Minerva Chir. 1999;54:717-724.
7. Abbas M, Farouk Y, Nasr MM, Elsebae MM, Farag A, Akl MM, et al. Gastrointestinal stromal tumors (GISTs): clinical presentation, diagnosis, surgical treatment and its outcome. J Egypt Soc Parasitol 2008;38:883-894.
8. Efremidou EI, Liratzopoulos N, Papageorgiou MS, Romanidis K. Perforated GIST of the small intestine as a rare cause of acute abdomen: Surgical treatment and adjuvant therapy. Case report. J Gastrointestin Liver Dis 2006;15:297-299.