


# "Erken evre" Skuamöz Hücreli Karsinomda Maksimum Parankim Koruyucu Rezeksiyon

# Maximum Parenchyma Saving Resection for an "Early Stage" Squamous Cell Carcinoma

"Erken evre" Skuamöz Hücreli Karsinom / "Early Stage" Squamous Cell Carcinoma

Cagatay Tezel, Volkan Baysungur, Erdal Okur, Semih Halezeroglu
Department of Thoracic Surgery, Süreyyapaşa Chest Disease and Thoracic Surgery Teaching Hospital, İstanbul, Türkiye.

**Özet**

Erken evre skuamöz hücreli karsinom radyolojik okült bir hastalıktır. Literatürde nadir olgular olarak rapor edilmiştir. Olgumuz, bronksokopik incelemede sağ alt lob superior segment ile bazal segment bronş ayrım karinasında lokalize küçük polipoid lezyon ile karakterize olup, sağ alt lob superior segmentin sleeve rezeksiyonu ile sonuçlanmıştır. Erken evre skuamöz hücreli karsinom tedavisinde anatomik olarak komplet rezeksiyon olan maksimal parankim koruyucu rezeksiyon seçilmiş vakalarda uygulanabilir.

**Anahtar Kelimeler**

Akciğer Kanseri; Tanı Ve Evreleme; Akciğer Kanseri Cerrahisi; Akciğer Patolojisi.

**Abstract**

Early stage squamous cell carcinoma is a radiologically occult disease. A few cases have been reported in the literature. In the case described here, bronchoscopic examination revealed a small polypoid lesion arising at the division between the superior and basal segmental bronchus of the right lower lobe. Sleeve resection of the superior segment of the right lower lobe was performed. An anatomically complete maximal parenchyma-saving resection can be done for such an early-stage squamous cell carcinoma.

**Keywords**

Lung Cancer; Diagnosis And Staging; Lung Cancer Surgery; Lung Pathology.

DOI: 10.4328/JCAM.537 Received:12.12.2010 Accepted: 05.01.2011 Publihed Online: 01.07.2012 J Clin Anal Med 2012;3(3):351-353
Corresponding Author: Cagatay Tezel, Department of Thoracic Surgery, Süreyyapaşa Chest Disease and Thoracic Surgery Teaching Hospital, İstanbul, Türkiye.
GSM: +905052600050 Fax. +902164214265 E-mail.: mdcagatay@hotmail.com

## Introduction

Early-stage, radiographically occult squamous cell carcinoma (ROSCC) is a subtype of squamous cell carcinoma. It has a high survival rate of almost 90% at the 5-year, in contrast to 75% survival rate of Stage-I squamous cell lung cancer.[1] ROSCC can be detected in high-risk patients with either sputum cytology or bronchoscopic inspection. Although ROSCC are typically small, 70% of cases require lobectomy.[2] Cases of ROSCC without lymph node metastases are regarded as localized carcinomas, which are in the range of segmentectomy. The major hesitation with regard to performing sleeve resection in these cases is local recurrence and increased postoperative complications.

In the case reported here, we describe the pathological overview of the tumour and current treatment modalities, in particular, the advantages of utilizing a maximal parenchyma-saving operation such as sleeve segmentectomy instead of lobectomy.

## Case

A 47-year-old male patient was referred to our pulmonology clinic with the symptom of haemoptysis. He had a history of smoking approximately 50 pack/years. His physical examination was unremarkable. His chest x-ray was normal, and his blood analyses findings were within normal ranges. Respiratory function tests, which included forced expiratory volume in the first second and forced vital capacity, were 95% and 92%, respectively. Chest tomography revealed right pleural thickening with reticulonodulary infiltration in the parenchyma of the basal segment of the right lower lobe.

Fiberoptic bronchoscopy was performed and a tumour occluding the superior segmental bronchus of the right lower lobe was identified. Biopsy of the lesion revealed a squamous cell carcinoma. The patient was referred to our thoracic surgery clinic. A metastatic work-up with positron emission tomography (PET)/computer tomography (CT) investigation showed consolidation in the right lower lobe with a 2.2 maximum standard uptake value (SUVmax). A second fiberoptic bronchoscopy prior to surgical resection revealed a normal endobronchial tree with mucosal haemorrhage from the superior segmental bronchus. Additionally, autofluorescence fiberoptic bronchoscopic examination was considered for better localization of the lesion. Mucosal irregularity at the division between superior and basal segmental bronchus of the right lower lobe was observed (Figure 1a,b). Biopsy revealed submucosal tumour infiltration.

A right muscle-sparing thoracotomy was performed. The lower lobe bronchus and basilar segmental bronchus were transected, and margins were seen to be clear macroscopically. The superior segment was stripped of basilar segments and sent for frozen section pathologic examination of the bronchial margins. Mediastinal lymph node dissection was performed. Frozen section evaluation was negative in both margins. Bronchial anastomosis was performed with continuous sutures using 4-0 absorbable material and sleeve segmentectomy was completed.

Histopathological examination of the resected specimen revealed a polypoid-type, well-differentiated early squamous cell carcinoma of 5 mm diameter with negative mediastinal and hilar lymph nodes (Figure 2).

## Discussion

One of the subtypes of squamous cell carcinoma is early-stage squamous cell carcinoma, which may rarely grow as an endobronchial polypoid mass. Sometimes referred to as an exophytic squamous cell carcinoma, these endobronchial tumours are usually very well differentiated and show minimal infiltration into the underlying lamina propria. Findings that meet endoscopic criteria of tumours are crucial for the determination of appropriate treatment. Konaka et al. discussed the correlation of endoscopic findings of early-stage squamous cell carcinomas with histopathology.[3] On the basis of bronchoscopic features, early-stage, central-type squamous cell carcinomas are divided into three types: polypoid (pedunculated), nodular, and superficial (hypertrophic). The presence of lymph node metastases and extracartilage invasion occurs in more than 20% of polypoid and nodular types; this was evident in the case described here. The hypertrophic type exhibits less than 5% invasion beyond the bronchial wall. Therefore, endoscopic findings can provide useful information in determining curative treatment. In our case, the tumour dimension was calculated as 5 mm with negative mediastinal and hilar lymph nodes but with extracartilage invasion.

Depth of invasion is an important indicator of survival and correlates with the length of the longitudinal extension of these tumours. Another indicator of survival is lymph node metastases. Tumours less than 10 mm in longitudinal extension are regarded as early ROSCC and have been reported to exhibit extracartilage invasion in less than 5% of cases.[4] Therefore, patients with this type of tumour even may undergo less-invasive treatment such as photodynamic therapy (PDT).

In early-stage lung cancer, PDT appears to be the treatment of choice only for the subgroup of patients who: are unsuited for surgical resection or refuse the operation; exhibit bronchial stump infiltration or recurrence; or have multiple side tumours.[5] If patients with findings similar to the case presented here were to undergo PDT without surgery, most likely, their cancer would recur due to cancer cell invasion beyond the cartilage. There-

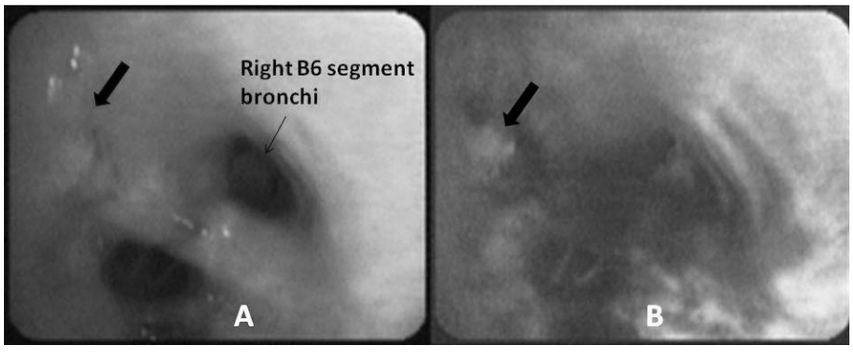


Figure 1. a) Bronchoscopic image shows mucosal irregularity at the division between the superior segmental and basal segmental bronchus of the right lower lobe "thick arrow". b) Autofluorescence fiberoptic bronchoscopic examination detects suspicious white areas in the same location

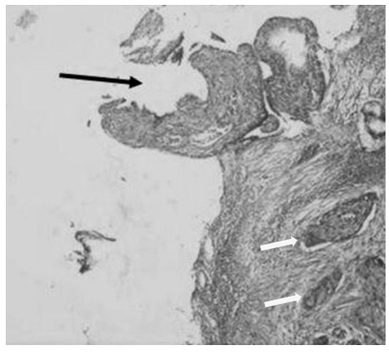

Figure 2. Histopathologic examination of ROSCC shows (Hematoxylin & eosin X 100) the cut surface of previously biopsied polypoid tumour (black arrow) and the submucosal infiltration (white arrows).

fore, especially for surgical candidates, PDT should not be the primary treatment of choice. Complete response rates with PDT have been reported to be between 30% and 85%, and recurrence correlated with complete response has been documented to be approximately 40%.[2,4] The follow-up periods cited in these reports on complete response varied from only one to three months. In contrast, the 5-year survival rate of 94 patients with ROSCC who underwent surgical resection was 93.5%, as reported by Saito et al.[6] Therefore, the "actual complete response" for PDT should be considered lower than published. Endobronchial therapy (laser cauterization, PDT, or brachytherapy) has a limited role because of the inability to assess the distal limit and to obtain a pathological staging on the basis of lymph node dissection.

Segmentectomy as a parenchyma-saving surgical technique is an ideal therapeutic choice especially in those types of tumours (i.e. ROSCC) that have a significant coexistence rate (22% to 25%) with multiple lung carcinomas, synchronous or metachronous.[7,8] As previously described, nearly 35% of ROSCC cases include invasion beyond cartilage, and 5% had lymph node metastases, indicating lobectomy as the preferred treatment of choice. Studies of resection cases in early-stage, nonsmall cell lung cancers (NSCLC) show acceptable results with segmentectomy (distinguished from wedge resection) even in non-compromised patients.

Bronchoplastic pulmonary resection enables complete resection of the tumour while minimizing the loss of lung parenchyma. In tumours that are benign or of low grade malignancy, the role of sleeve segmental resection is well established. But also in selected cases of bronchogenic carcinomas, especially for less aggressive tumours such as ROSCCs, maximal parenchyma-saving resection such as sleeve segmentectomy, as employed in our case, can be performed.

**References**

1. Nakamura H, Kawasaki N, Hagiwara M, Ogata A, Kato H. Endoscopic evaluation of centrally located early squamous cell carcinoma. Cancer 2001;91:1142-7
2. Cortese DA, Pairolero PC, Bergstralh EJ, et al. Roentgenographically occult lung cancer: a ten-year experience. J Thorac Cardiovasc Surg 1983;86:373-80
3. Konaka C, Hirano T, Kato H, et al. Comparison of endoscopic features of early-stage squamous cell lung cancer and histological findings. Br J Cancer 1999;80:1435-9
4. Kennedy TC, McWilliams A, Edell E, et al. Bronchial intraepithelial neoplasia/early central airways lung cancer. Chest 2007;132:221S-33S
5. Moghissi K, Dixon K. Is bronchoscopic photodynamic therapy a therapeutic option in lung cancer? Eur Respir J 2003;22:535-41
6. Saito Y, Nagamoto N, Ota S, et al. Results of surgical treatment for roentgenographically occult bronchogenic squamos cell carcinoma. J Thorac Cardiovasc Surg 1992;104:401-7
7. Fujimura S, Sakurada A, Sagawa M, et al. A therapeutic approach to roentgenographically occult squamous cell carcinoma of the lung. Cancer 2000; 89:2445-8
8. Pierard P, Faber J, Hutsebaut J et al. Synchronous lesions detected by autofluorescence bronchoscopy in patients with high-grade preinvasive lesions and occult invasive squamous cell carcinoma of the proximal airways. Lung Cancer 2004;46:341-7