Migrasyon ve Penetrasyon Gösteren Bir Yabancı Cisim Aspirasyonu: Pisipisi Otu

A Foreign Body Aspiration Showing Migration and Penetration: Hordeum Murinum

Fuat Sayır[1], Ufuk Çobanoğlu[1], Bünyamin Sertoğullarından [2], Duygu Mergan[1]

[1]Göğüs Cerrahisi AD, Yüzüncü Yıl Üniversitesi Tıp Fakültesi, Van, Türkiye.

[2]Göğüs Hastalıkları AD, Yüzüncü Yıl Üniversitesi Tıp Fakültesi, Van, Türkiye.

Özet

Yabancı cisim aspirasyonu çocukluk çağında morbidite ve mortalitenin önemli bir sebebidir. Trakeobronşial yabancı cisim aspirasyonları içerisinde oldukça nadir rastlanan Pisipisi otu atipik bir kliniğe sahiptir. Bronşial sistemdeki geç kalınmış olgularda kaçınılmaz olarak bronşektazi ve akciğer parankim destrüksiyonu gibi cerrahi gerektiren sekellere yol açabilir. İlerleyici özelliğinden dolayı bronkoskopik olarak çıkarılması güç olan Pisipisi otu ilginç klinik tablolara neden olabilir. Bu çalışmada da erken dönemde hemoptiziye yol açması ile tespit edilen ve negatif bronkoskopi sonucu torakotomi ile çıkarılabilen Pisipisi otu aspirasyon olgusu sunulmuştur.

Anahtar Kelimeler

Yabancı Cisim, Pisipisi Otu, Hemoptizi.

Abstract

Aspiration of foreign bodies is an important cause of mortality and morbidity in the childhood period. Very rarely seen among the tracheobronchial foreign body aspirations is the Hordeum Murinum, which has an atypical clinical presentation. It may cause unavoidable sequelae in the bronchial system requiring surgery, like bronchiectasis and destruction of the lung parenchyma in patients with delayed diagnosis. Hordeum Murinum, which is hard to pull out due to its progressive nature, may cause interesting clinical pictures. In this study, a case of Hordeum Murinum aspiration is reported which has been diagnosed early due to hemoptysis could be pulled out by thoracotomy after negative bronchoscopy.

Keywords

Foreign body, Hordeum Murinum, Hemoptysis.

DOI: 10.4328/JCAM.560 Received: 24.12.2010 Accepted: 07.01.2011 Published Online: 01.10.2012 J Clin Anal Med 2012;3(4):455-457

Corresponding Author: Fuat Sayır, Göğüs Cerrahisi AD, Yüzüncü Yıl Üniversitesi Tıp Fakültesi, Van, Türkiye.

Phone:+90-432 215 0473 Fax: +90-432 2168352 E-mail: sayirfuat@yahoo.com

Intraduction

Foreign body aspiration (FBA) is defined as the settlement into the lower respiratory system of an object which is taken by mouth or through the nose during breathing. Foreign body aspiration is an important health problem during childhood. Foreign body aspiration is reported to be one of the most common causes of sudden and unexpected deaths in the childhood period.[1,2] Complications can be seen due to FBA both in the acute phase including asphyxia, hemoptysis, cough, respiratory failure, acute infections, and in the chronic period which include bronchiectasis, abscess and atelectasis due to recurrent infections.[3] Our patient had been admitted to our clinic on the second day of aspiration due to severe hemoptysis which can be evaluated as an important advantage in the sense that more severe complications had been avoided. We thought that it would be worthwhile to report the interesting journey of Hordeum Murinum (Figure 1), which starts from mouth and ends in the pleural cavity, on the pericardium by passing the lungs in a time as short as 3 days after aspiration.

Case Report

The thirteen-year-old male patient has been discharged from the healthcare centre to which he had applied after foreign body aspiration with his medical treatment being arranged. After 24 hours, he was hospitalized in our emergency department with the complaint of 100-150 cc hemoptysis. In his history, the patient reported that he had aspirated a kind of herb while eating salad; could not pull out the substance by coughing and a severe respiratory failure and coughing as being choked had been developed and after a time, his cough had disappeared and the next day a sudden hemoptysis had appeared.

On his physical examination, his general condition was moderate and he was conscious with normal vital signs. On auscultation, respiratory sounds were normal and the blood tests were within normal ranges.

On the radiological evaluation, there was a suspected infiltrative image in the left middle zone on the posteroanterior chest x-ray (Figure 2) and a pneumonic consolidation with a cavity image of 1-2 cm in the left lingular segment level on thoracic computed tomography scans (Figure 3,4). Conservative treatment has been started for the patient Rigid bronchoscopy was performed under general anesthesia and both bronchial systems were evaluated as normal. No foreign body or hemorrhage was detected. Operative intervention was planned due to the reappearance of hemoptysis following bronchoscopy. Posterolateral thoracotomy was performed using single lung ventilation. The lung parenchyme was seen to have adhered to the thoracic wall at the lingular level. After separation of this adhesion from the thoracic wall, an air leak began in an area of 3-4 millimeters. The region where the cavity image had been seen on the tomography was reached by widening the pneumotomy from this area (Figure 5). A foul smelling collection of purulent secretion was detected within the cavity. No foreign body was found in the cavity after cleaning the secretions. On exploration of the thoracic cavity, a Hordeum Murinum was found in the retrosternal region, in the area where the pericardium angles with the thoracic wall, just under the mammarian artery-vein, and it was removed (Figure 5).

In the postoperative period, he had hemoptysis for 1-2 days which decreased gradually and disappeared. The patient was discharged from the hospital on the fifth postoperative day.

Discussion

Although more common in infants and small children, foreign body aspirations can be seen in all age groups. FBA is the most common cause of death due to home accidents in infancy. It has been reported in different studies that 79-96% of patients with foreign body aspiration were less than 10 years of age.[3]

Although the aspirated foreign bodies vary depending on the age, region and season, the most commonly seen foreign body aspirations in our country are dried nuts and pins.[4] Hordeum Murinum is a stringy herb with a powerful tissue penetration that is very rarely seen among foreign body aspirations. It is more commonly reported in children living in rural regions. This grass is also referred to as Wild Barley or Grass Inflorescences.[5]

After aspiration of the foreign body in a significant number of patients, clinical pictures including choking attacks, coughing, wheezing, asphyxia and sudden death can be observed in the acute period. Barrios et al.[6] reported that bronchoscopy should be performed in all patients with the history of choking attack, even if they have minimal symptoms or no radiological signs. The most important symptom other than coughing was hemoptysis in our case. It had begun on the second day, which was different from the information in the literature. Foreign body aspirations may progress into brochiectasis eventually leading to resection. It was determined that after foreign body aspirations, while 2/3 of the patients were diagnosed in the subsequent seven days, 17-19% of the patients were diagnosed after 30 days or later.[7] In our case, hemoptysis with an acute onset can be regarded as a chance for early diagnosis and treatment. After foreign body aspirations, diagnosis is attempted with radiological evaluations. Among these cases, the exact diagnosis is made with bronchoscopy and other advanced surgical interventions. In our case, the presence of a suspected infiltrative image in the left middle zone in the postero-anterior chest X-Ray and determination of a pneumonic consolidation and a cavity region at the left lingular segment level on thoracic computed tomography in as short a period as 3 days, arise from the migration and penetration characteristics of the aspirated foreign body.

Hordeum Murinum can cause coughing, dyspnea and obstructive pneumonia by getting implanted in the airway mucosa, or with its migration ability, it may pass through the peripheral regions of the lung as well as the pleural cavity and cause chronic complications including abscess, cavity formation, atelectasis and empyema. Some rare cases have been reported in which through migration, the foreign body had passed through the pleural cavity and exited the thoracic wall.[8] In our case, the foreign body produced pneumonic consolidation and cavity, penetrated the visceral pleura and



Figure 1. Image of plant (Hordeum Murinum)

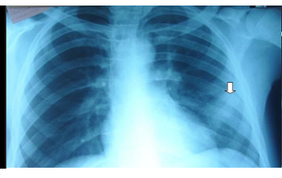

Figure 2. Infiltrative image in the left middle zone in the postero-anterior chest X-Ray

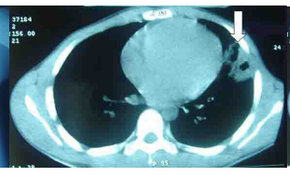

Figure 3. Pneumonic consolidation and a cavity image of 1-2 cm in the left lingular segment level on the thoracic computed tomography (parenchymal window)

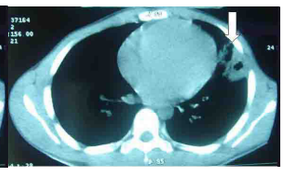

Figure 4. Pneumonic consolidation and a cavity image of 1-2 cm in the left lingular segment level on the thoracic computed tomography (mediastinal window)

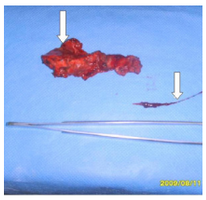

Figure 5. Excisional tissue and Hordeum Murinum

settled in the pleural cavity on the pericardium in as short a duration as 3 days. The necessity of thoracotomy due to the inability to remove the foreign body despite repeated bronchoscopic interventions has been reported in 1% of patients.[9,10] There are some studies reporting as high thoracotomy rates as 34%. The higher thoracotomy rates are thought to be due to the late presentation of the patients to the hospital after aspiration, and therefore encountering complications like bronchiectasis and fibrosis more frequently.[9,10]

In conclusion, Hordeum Murinum aspiration is a rare foreign body aspiration. Its botanic and morphological characteristics cause this herb to migrate rapidly, and in many cases, since it has a silent period, belatedness of referral of the patient to the doctor that can result in morbid conditions. Although our patient was lucky to have referred to the hospital with a hemoptysis attack in the early period, a major method in the diagnosis and treatment of foreign body aspirations, bronchoscopy, was found to be insufficient in our patient, and thoracotomy, which should not be avoided if necessary for the diagnosis and treatment, was performed.

References

1. Metrangelo S, Monetti C, Meneghini L, Zarda N, Giusti F. Eight years experince with foreign- body aspiration in children: what is really important for a timely diagnosis? J Pediatr Surg 1999; 34: 1229-1231.
2. Brkic F, Dedic SD, Hajdarovic D. Broncoscopic removal of foreign bodies from children in Bosnia and Herzegovina: experince with 230 patients. Int J Ped Otorhionolaryngol 2001; 60: 193-196.
3. Kim IG, Brummit WM, Humphry A et al. Foreign Body in the Airways: A Review of 202 Cases. Laryngoscope 1973; 83: 347.
4. Pasaoglu I, Dogan R, Demircin M, Hatipoglu A, Bozer AY. Bronchoscopic removal of foreign bodies in children: retrospective analysis of 822 cases. Thorac Cardiovasc Surg 1991;39:95-8.
5. Dindar H, Konkan R, Çakmak M et al. Bronchopleurocutaneous fistula caused by an unusual foreign body aspiration simulating acute abdomen. Eur J Pediatr 1994; 153: 136-137.
6. Barrios E, Gutierrez C, Vila JJ, Poqeut J, Ruiz S: Bronchial foreign body: Should broncoscopy be performed in all patients with a choking crisis Pediatr Surg Int 1997;12: 118-120.
7. Karakoç F, Karadağ B, Akbenlioğlu C, Ersu R, Yıldızeli B, Yüksel M, Dağlı E. Foreign body aspiration : what is the outcome. Pediatr Pulmonol 2002; 34: 30-36.
8. Basok O, Yaldiz S, Kilincer L. Bronchiectasis resulting from aspirated grass inflorescences. Scand Cardiovasc J 1997; 31: 157-159.
9. Kahraman C, Oğuzkaya F, Akçalı Y, Şahin A. Lung infections due to aspirated foreign bodies: Analysis of 84 cases. Asian Cardiovasc Thorac Ann 1999; 7: 305-308.
10. Deksin R, Young G, Hoffman R. Management of pediatric aspirated foreign bodies. Laryngoscope 1997; 107: 540-543.