Decompressive Craniectomy for Intractable Intracranial Hypertension

Dirençli İntrakranial Hipertansiyonda Dekompresif Kraniektomi

İntrakranial Hipertansiyon için Kraniektomi / Craniectomy for Intracranial Hypertension

Bulent Bakar[1], Mehmet Murat Sumer[2], Ismail Hakki Tekkok[3]
[1]Department of Neurosurgery, Kırıkkale University Faculty of Medicine, Kırıkkale, Türkiye.
[2]Department of Neurology, Güven Hospital, Ankara, Türkiye.
[3]TOBB-ETU Hospital, Department of Neurosurgery, Ankara, Türkiye.

22-26 Nisan 2011 tarihleri arasında Antalya' da düzenlenen 25. Türk Nöroşirürji Derneği Bilimsel Kongresi' nde tartışmalı poster bildiri olarak sunulmuştur.

Özet

Amaç: Bu retrospektif klinik çalışmada çeşitli sebeplerle ortaya çıkmış olan intrakranial hipertansiyon tedavisinde dekompresif kraniektominin yeri ve etkileri incelenmiştir. Gereç ve Yöntem:18 ile 75 yaş arası 9 hasta çalışmaya alınmıştır. Dört hasta travmatik beyin yaralanması, iki hasta subaraknoid kanama ve üç hasta ise malign orta serebral arter tıkanıklığı ile takip ve tedavi edilmiştir. Bulgular: Dokuz hastaya dekompresif kraniektomi tedavisi uygulanmıştır. Bu hastaların ilk başvurularındaki intrakranial basınç (ICP) değerleri ortalaması 22.6 ± 6.7 mmHg; ortalama ameliyat öncesi ICP değeri 40.8 ± 16.3 mmHg ve cerrahi tedavi sonrası ICP ortalama değeri 9.3± 3.6 mmHg olarak ölçülmüştür. İki hastaya bilateral ve kalan yedi hastaya unilateral frontotemporoparietal kraniektomi uygulanmıştır. Kraniektomi kemik flebinin tekrar yerine konması için ortalama 25.75±10.0 gün beklenmiştir. Subaraknoid kanama ile takip edilen bir hasta cerrahi tedavi sonrası ölmüştür (mortalite oranı %11.1). Otuz altı aylık takip sonrası hastaların ortalama Glasgow iyileşme skala puanı yaklaşık 4 olarak hesaplanmıştır. Sonuç: Eğer zamanında ve dikkatli bir şekilde uygulanabilirse bu cerrahi teknik akut ya da gecikmiş dirençli intrakranial hipertansiyon tedavisinde başarılı sonuçlar verir.

Anahtar Kelimeler

İntrakranyal Basınç Yükselişi; Sonuç Değerlendirmesi

Abstract

Aim: This retrospective study was established to analyse the effects of the decompressive craniectomy on patients with different causes of increased intracranial pressure. Material and Methods: Nine patients at risk of developing malignant cerebral edema aged between 18 and 75 years were included in this study. Four patients suffered from severe traumatic brain injury, two patients from subarachnoid haemorrhage (SAH) and vasospastic ischemia, and 3 patients from malignant infarction of the middle cerebral artery. Results: Nine patients underwent decompressive craniectomy as the last therapeutic choice. At first admission mean intracranial pressure (ICP) was 22.6 ± 6.7 mmHg; mean preoperative ICP value was 40.8 ± 16.3 mmHg; and mean postoperative ICP value was 9.3± 3.6 mmHg. In two patients bilateral; and in seven patients unilateral frontotemporoparietal craniectomy was preferred. Mean time of the re-implantation of the bone flap was 25.75±10.0 days. One patient with SAH died postoperatively and eight patients survived (mortality rate 11.1%). Mean value of the Glasgow Outcome Scale score as evaluated at 36 months after the decompression was approximately 4 Discussion: This surgical procedure is successful for treatment of the acute or delayed intractable intracerebral hypertension with a low rate of complication if it is performed timely and carefully.

Keywords

Intracranial Pressure Increase; Outcome Assessment

DOI: 10.4328/JCAM.676 Received: 11.10.2011 Accepted: 22.11.2011 Published Online: 01.10.2012 J Clin Anal Med 2012;3(4):384-388
Corresponding Author: Bulent Bakar, Department of Neurosurgery, Kırıkkale University Faculty of Medicine, Kırıkkale, Türkiye..
T.: +903182252485 E-mail: bulentbanrs@yahoo.com

Introduction

Intractable intracranial hypertension (IIHT) is an additional risk for patients who already have suffered from brain damage and therefore remains a challenge for the treating physician.[1] In these patients the initial strategy is to repair or to stabilize the primary cause and to decrease the intracranial pressure (ICP) levels to minimise the alterations of both local and total cerebral perfusion.[2] Intracranial hypertension which could not be managed with maximal medical treatment occurs in up to 10 to 15% of these patients. Studies show a significant relationship between an ICP greater than 25 mmHg and poor outcome.[3] Numerous recent clinical reports provided data that decompressive craniectomy improves O2 delivery to brain cells when cerebral ischemia is at its peak levels.[4]

There are yet few reports in the medical literature that compare the effect of decompressive craniectomy in different neurosurgical diseases. Therefore this retrospective study was established to analyse the effects of the decompressive craniectomy on patients with different disease groups.

Materials and Methods

Patients characteristics

On admission, cerebral pathology was revealed by neuroradiological studies (CT, MRI, MRA) and neurological status was recorded as the pre-intubation Glasgow Coma Scale (GCS) score. Penetrating head injury or systemic injury with head injury was an exclusion criterion. None of the chosen patients needed to be operated on admission for an intracranial hematoma or mass lesion. Patients with primary fatal brainstem failure as indicated by GCS score of 3 did not undergo surgical intervention.

Treatment protocols

Patients were treated in the neurosurgical intensive care unit (NICU). Each patient was fully resuscitated, intubated, and anaesthesized with pentothal sodium or sedated with propofol and remifentanyl hydrochloride after first admission. In the NICU, patients were kept in a supine position with 30 degree head elevation. Basic monitoring (six lead ECG, invasive arterial blood pressure measurement, pulse oxymeter, continuous rectal temperature assessment), and frequent (2-4 hourly) blood gas analyses were performed; and all basic blood biochemistry parameters (sodium, potassium, albumine, creatinine, etc.) were followed twice daily. Neurologic monitoring included an ICP probe parenchymal type device (Camino, Integra Neurosciences, San Diego, CA), repeated control of pupil size and its reactivity to light, and periodic recording of the GCS score when possible.

The intraparenchymal pressure probe for ICP monitoring was inserted into the brain parenchyma at risk through a drill hole centered at Kocher's point, and the tip was adjusted to a depth of 25-30 mm. The correct position was verified with CT within 24 hours. After insertion of the ICP probe, a standard treatment protocol was used. Ventilation parameters were managed to an optimum PaCO2 according to ICP; and a rising in ICP over the 20 mmHg was managed by mild hyperventilation (PCO2= 30-32 mmHg), intermittent 4 hourly application of mannitol (25-50 g). Dopamine was titrated when cerebral perfusion pressure (CPP) was less than 65 mmHg for more than 15 minutes. Conservative treatment was continued until the ICP level was decreased below 20 mmHg. Further CT investigations were performed if unexpected changes in the clinical status observed. Hypothermia had not been used in any of our patients.

Indications for surgery

The indications for decompressive surgery with dural expansion were:

1. the appearence of definite unilateral or bilateral cerebral swelling on CT scan (midline shift of more than 10 mm and/ or obliteration of the cisternal structures)
2. increased ICP levels (more than 25 mmHg) remaining high for at least 1 hour despite maximal medical treatment
3. worsening the neurological status with dilatation of pupil(s), unresponsiveness to light

The presence of a midline shift was measured on CT scans obtained prior to surgery by observation of the distance of septum pellucidum that deviated from the line between anterior and posterior falx cerebri at its attachment to the inside of the calvarium.

Operative procedures

Unilateral oedema or swelling was treated by a large hemicraniectomy over the swollen hemisphere, whereas bilateral diffuse oedema/ swelling were treated by bilateral fronto-temporo-parietal (F-T-P) bony decompression. If the neurological status and/ or ICP levels were better than the above mentioned surgical indications, supportive and antioedema treatment was continued.

ICP probe insertion is preferably done on the side of planned or predicted surgery. This is important because a contralateral placement may cause difficulty in positioning the patient for surgery or may cause unnecessary pressure over the Camino bolt. From this point of view there is no problem with bilateral decompression yet overturning of bicoronal flap anteriorly will be limited because of the bolt.

Unilateral decompressions are performed using wide F-T-P central skin flap whereas bilateral decompressions are performed by bilateral wide F-T-P skin flaps. The burrholes are connected using pneumatic drill, with subsequent removal of a 12x15 cm free bone flap from each side. Additional temporal craniectomy towards the floor of middle fossa is done using a large rongeur. For bilateral decompressions, a parasagittal 3 cm wide bony strip is preserved both to avoid damage to the sagittal sinus and to serve as a frame for a late calvarial reconstruction. The dura is usually opened with stellate incision in the areas involving the frontal, temporal and parietal lobes extensively (Figure 1). Cortical resection was not performed in any patients. After duraplasty using galea greft or artificial meninges (Duragen, Integra LifeSciences Corporation, USA), the temporal muscle was loosely reapproximated to the healthy dura and the skin flap was then closed with interrupted prolene sutures. The bone flap was usually re-implanted within 1-2 months after craniectomy, having been stored under sterile conditions at -80 0C.

Postoperative management

Postoperatively, a CT scan was obtained for checking brain-bone relationship at craniotomy borders and change in the midline shift. After the decompressive surgery, conventional medi-

cal management including sedational anaesthesia, intermittent mannitol, antiepileptic agents were continued at least two more days (48 hours). A ventriculoperitoneal shunt was performed if it was necessary.

Assessment of neurological outcome

The neurological outcome was scored according to the Glascow Outcome Scale (GOS). When GOS was:

1. death
2. persistent vegetative state
3. severe disability
4. moderate disability
5. mild or no disability[5]

Results

Patients characteristics

All patients were treated during the time period of February 1, 2005 to April 1, 2009. Nine patients at risk of developing malignant cerebral oedema aged between 18 and 75 years (mean age was 48.1 ± 18.8 years) were included in this study. Four patients suffered from severe traumatic brain injury (STBI), two patients from subarachnoid haemorrhage (SAH) (Hunt Hess grade IV or V), and 3 patients from complete infarction of the middle cerebral artery (CVA-cerebrovascular accident) (Table 1).

Mean pre-intubating GCS score of all patients was 7.3±3.1. At initial insertion of ICP probe, mean ICP level of overall patients was 22.6 ± 6.7 mmHg.

Overall, 9 patients underwent decompressive craniectomy between days 1 and 12 post-admission (mean day 5.2 ± 4.6). At initial insertion of ICP probe, mean ICP level was 22.6 ± 6.7mmHg; preoperative mean ICP value was 40.8 ± 16.3 mmHg; and mean postoperative ICP value was 9.3 ± 3.6 mmHg. In two patients bilateral; and in seven patients unilateral F-T-P craniectomy was preferred. Mean time of the re-implantation of the bone flap for calvarial reconstruction was 25.7±10.0 days. The mean hospital stay was 56 days (range 13 to 148 days).

Complications related to decompressive surgery

There was no intracranial and/ or wound infection; nor any CSF leakage in any patient. In one patient, a subdural effusion occured at the surgery side; and after the bone flap re-implantation, the effusion had disappeared (Figure 2). One patient who had sigmoid sinus thrombosis occurring after blunt head trauma required ventricoluperitoneal shunt for late hydrocephalus. In two patients, posttraumatic epilepsy occurred.

Table 1. Descriptive table of the patients

Patient	Age (year)	Sex	Disease	Surgery	f-GCS	a-ICP (mmHg)	f-ICP (mmHg)	p-ICP (mmHg)	Delay of surgery (day)	Reimplantation of the bone flap (day)	d-GCS	GOS
1	18	M	STBI	Bilateral	4	21	30	12	1	30	8	2
2	37	M	STBI	Bilateral	8	18	47	9	12	16	15	5
3	45	M	STBI	Unilateral	5	16	45	7	12	40	11	3
4	34	M	STBI	Unilateral	4	20	50	6	3	40	10	3
5	66	M	SAH	Unilateral	4	36	54	9	2	22	14	5
6	38	F	SAH	Unilateral	10	20	69	10	10	-	Exitus	1
7	51	F	CVA	Unilateral	10	22	22	9	2	21	13	5
8	75	M	CVA	Unilateral	9	19	19	5	3	23	12	4
9	69	M	CVA	Unilateral	12	32	32	17	2	14	14	5

(M: male, F: female, STBI: severe traumatic brain injury, SAH: subarachnoidal haemorrhage, CVA: cerebrovascular accident, f-GCS: Glasgow Coma Scale score on admission, a-ICP: intracranial pressure on admission, f-ICP: preoperative ICP level, p-ICP: post-operative ICP level, d-GCS: Glasgow Coma Scale score while discharge from the hospital, GOS: Glasgow Outcome Scale score as evaluated at 36 months after the decompression)

Follow-up and outcome

The clinical outcomes were evaluated at 36 months after the decompressive surgery. One patient died postoperatively (day 13), and seven patients survived (mortality rate 11.1%). GOS score values of the operated patients were as follows: 4/9 full recovery (GOS score, 5); 1/9 moderate recovery (GOS score, 4); 2/9 severe disability (GOS score, 3); 1/9 vegetative state (GOS score, 2); 1/9 died (GOS score, 1).

Postoperative fatality was associated with delayed basilar artery spasm caused by SAH in a patient with coiled basilar tip aneurysm. In the STBI group, one patient recovered fully, two patients were left with severe disability; and another patient remained in vegetative state. Additionally, each of three CVA patients had moderate/ full recovery; and one SAH patient had full recovery. Mean GOS score value for operated patients was approximately 4±1.2.

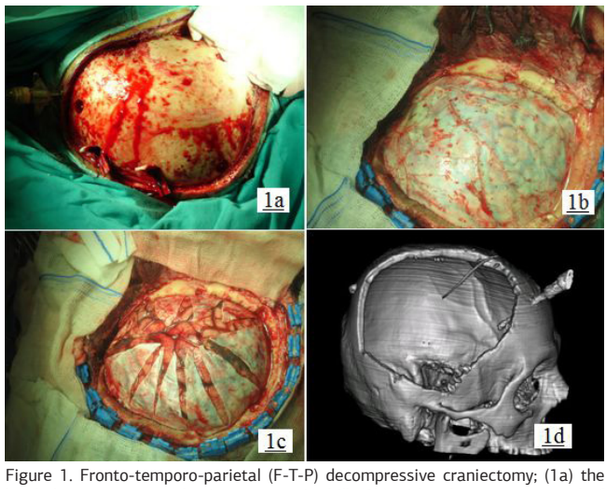

Figure 1. Fronto-temporo-parietal (F-T-P) decompressive craniectomy; (1a) the burrholes are connected using pneumatic drill; (1b) with subsequent removal of the bone flap (12x15 cm); (1c) The dura is then opened in stellate fashion (1d) 3D CT image of the unilateral F-T-P decompressive craniectomy.

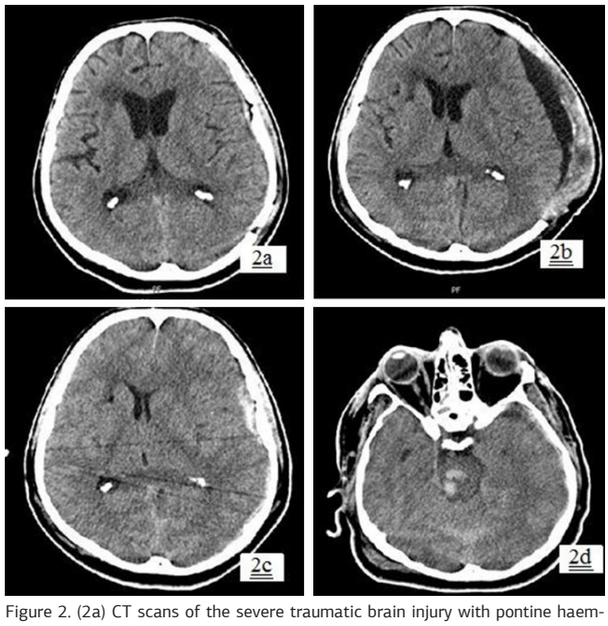

Figure 2. (2a) CT scans of the severe traumatic brain injury with pontine haemorrhage; (2b) delayed progressive hemispheric oedema associated with ipsilateral cerebral contusion; (2c) subdural effusion occured at the surgery side after craniectomy; (2d) please notice that after re-implantation of the bone flap, this complication had disappeared.

Discussion

The basic pathophysiological mechanism of brain oedema associated with brain injury is an increase in the net water content of the brain. This causes an increase in tissue pressure which increases cerebrovascular resistance, compromises the microcirculation, and results in reduced cerebral blood flow.[4] Various neurological conditions which cause an increase in intracranial pressure have been treated successfully with uni- or bilateral decompressive techniques. The effectiveness of this surgical procedure in reducing ICP has been proven by recent reports or studies that come out in a steadily increasing manner.[3] Decompressive craniectomy together with dura expansion is intended to increase the volume of the intracranial compartment, and to create space for oedematous brain tissue. The procedure thus not only prevents the event cascade leading to impaired tissue oxygenation but also the secondary injuries resulting from ischemia.[3,4] Recent studies have shown that early decompression after development of refractory intracranial hypertension almost always brings about an improved outcome.[6] Mortality figures had also dropped from as high as 80% to 20%. Most of the reported investigations suggested that patients who underwent an early surgery (within 6 hours from the injury) have a more favourable outcome compared with those who underwent surgical intervention beyond 6 hours.[7] Kenning et al. (2009) have suggested that hinge craniotomy may be widely applicable for cerebral decompression, and it appears to be as good as decompressive craniectomy in providing postoperative ICP control. They also have shown that their results are in equivalent early clinical outcomes.[8] However this study has not contained the results of the tissue oxygenation levels, and has required long term outcome analysis.

The adverse relationship between elevated ICP and outcome has been recognized for more than 30 years.[9] In our study, mean GCS score on admission was approximately 7; and preoperative mean ICP level was 40.8 ± 16.3 mmHg. Despite these unfavourable preoperative data, the mean GOS score value of the operated patients was approximately 4, and the mortality rate was 11.1%. Salvatore et al. (2008) postulated that in STBI patients, the preoperative neurological status and pupillary reactivities has not effect on the favourable outcome.[7] In our study, mean time between occurence of primary injury and decompressive surgery for IIHT was 5.2±4.6 days; and mean GOS score value of these operated patients was approximately 4. The mean GOS score value of STBI group was nearly 3, but the SAH and CVA group had GOS score of 4. These results suggest that both surgery timing and aetiology of the IIHT is much more important for the favourable outcome.

On the other hand even after sufficient decompression, the brain will still maintain a high demand of oxygen and previously compressed cerebral vessels will fill with blood; and this may cause a further increase in net brain volume and a parodoxical rise in ICP in early postoperative period.[4] In our study, this event occurred during intra- and early post-operative course which had to be aggressively managed by medical treatment. Decompressive craniectomy is usually considered technically simple and it has a low rate complication. With current armementarium of operating rooms lifting a bone flap and incision of the dura to relieve the pressure will not take more than 20 minutes. The cumbersome part is duraplasty. As for bony decompression, almost all the authors have suggested an adequate size of the craniectomy to prevent self-strangulation of edematous brain and local pressure of bony corners on cortex of bulging brain. Within few hours after injury or ischemia pressure of edematous temporal lobe on brain stem will cause necrotic changes within the stem and along the cranial nerves and vascular structures[7] therefore additional craniectomy along the temporal fossa is a crucial part of decompression technique in order to relieve pressure on temporal lobe as a whole hence on brain stem. A large bony decompression also reduces the incidence of delayed intracranial haematoma, repeated surgical intervention, postoperative CSF leakage, traumatic seizure(s), and/or intracranial infections.[10] In our series three patient had minimal brain strangulation: one patient (patient #2) underwent bilateral F-T-P craniectomy; and he had full recovery (GOS score, 5). The other one (patient #1) undergoing bilateral craniectomy ended up was vegetative status (GOS score, 2); and another one (patient #3) performed unilateral craniectomy was severe disability (GOS score, 3).

In several studies, age appeared as a negative predicting factor for favourable outcome. Several authors concluded that the mean age of the group with unfavourable outcome was 56.6 years.[6,9,11,12] Our study did not support this data. In STBI group, all patients' ages were below the 55 years, and mortality rate was 0%; however in CVA group the mean age was 65 years, and they had mild disability with full survival. In SAH group there was one mortality who was 38 year-old-woman.

STBI is a major cause of death and disability in the population; and this morbidity and mortality is produced by cerebral oedema which contributes to elevation of ICP and reduction of cerebral blood flow. These processes manifest as progressive intracranial hypertension refractory to medical therapy with subsequent brain herniation and death. The literature data stress the importance of age, severity of injury, presence of extracranial injuries as main predictors of outcome. Initial GCS score has not been a reliable marker for development of marked ICP elevation.[13] Our study also showed that initial GCS score did not have a predictive value for the outcome. Age too did not correlate with outcome; but severity of the injury and initial ICP values were important prognostic factors in this study (See Table 1).

Most of patients with hemispheric infarctions had unilateral brain swelling and they have 80% mortality rate. Decompressive craniectomy has been shown to reduce this mortality to 20-35%.[2,14,15] Few recent studies on malignant ischemic stroke demonstrate that early surgery even before the pupil dilates may increase the number of patients with a favourable functional outcome.[6,16,17] In our study, although the mean time between the onset of ischemic stroke and the operation was aproximately 60 hours, these CVA patients still had mild disability with full survival.

Some recent studies showed that patients with SAH still suffer from a high incidence of specific complications (such as symptomatic cerebral vasospasm); and delayed cerebral ischemia secondary to vasospasm contributes a major part of the morbidity and mortality).[18,19] In these patients decompressive craniectomy may enable the normalization of arterial PCO2 and reduce the co-morbidity of the 3H therapy (hypertensive, hy-

pervolemic and haemodilutional therapy).[18,20] In our study, one of the SAH patients who had symptomatic cerebral vasospasm died within 13 days; and other one who had right frontal oedema caused to subfalcine herniation recovered almost fully 1 year after decompressive craniectomy. Overall, decompressive craniectomy may lead to improved outcome in a carefully selected subgroup of patients with high-grade patients (Hunt-Hess 4 and 5).

Fortunately, there are only few complications of decompressive surgery. Risk of fatal complications such as intracranial infections and contralateral intracerebral haematoma exist but rarely take place. Other complications (such as subdural effusion-hygroma, postraumatic hydrocephalus, epilepsy) can adversely effect the patient's outcome.[3,9,21] In our experience, there was no postoperative contralateral intracerebral haematoma or any intracranial infection. In two patients, postraumatic epilepsy occurred, and this condition was successfully managed using antiepileptic medication. In one patient, postoperative subdural effusion recovered spontaneously after reimplantation of the bone flap. In another patient, postoperative hydrocephalus occurred 36 days after the decompressive surgery, but this complication was secondary to major dural sinus trombosis and was not related to surgery per se. Overall, this surgical procedure can decrease the mortality and morbidity associated with acute or subacute intracerebral hypertension with a low rate complication if it is performed carefully and adequately.

This retrospective study has few pitfalls. First, because of a small and a rather heterogeneous study population, it is hard to conclude specifically on patient outcome for different etiologies. Additionally it is too small to have statistical impact and give guidelines concerning indications and timing of decompressive craniectomy. However, the patient variety shows that decompressive craniectomy does improve the survival and overall outcome for all, less in trauma more in ischemic group. Second, the study sample includes different disease groups each representing different complex mechanisms. However though the pathophysiology in these groups differs, the most important common denominator is increased ICP and cerebral oedema. All patients with CVA had mild disability and full survival, but the SAH group had one mortality associated with cerebral vasospasm. The outcome in STBI group was not uniform as would be expected. However since the secondary effects of trauma energy follow different pathophysiological steps than CVA and SAH, conditions like contusion, hematoma mass, brain stem damage, diffuse axonal injury and anoxia/ hypoxia could have hampered the outcome of trauma patients. Third, there was no co-measurement of the local brain tissue oxygenation. In literature various studies demonstrate that cerebral hypoxia is common after severe brain injury and this hypoxia sometimes can occur when CPP or ICP is normal levels. This condition is also related with poor outcome. Many studies have showed that decompressive craniectomy with dura expansion restores adequate brain tissue oxygenation.[4,20] Fourth, although the indications for decompressive craniectomy were prospectively defined, data analysis was performed retrospectively without a control group.

As conclusion, the indication for decompressive surgery is simple and straightforward and that is intractable intracranial hypertension. Choice is between unilateral and bilateral decompression and that decision is largely based on preoperative CT scans. The age, severity of injury, presence of extracranial injuries or systemic diseases should not affect patient selection).[13]

Conclusion

1. For improving the outcome following intracranial hypertension, controlling high ICP, maintaining a close-to-normal cerebral perfusion pressure and cerebral blood flow is extremely important.
2. At present, choice of the treatment for acute or subacute intractable intracerebral hypertension is uni- or bilateral decompressive craniectomy. This surgical procedure is successful with a low rate complication if it is performed carefully and adequately.
3. A wide decompressive craniectomy with dura enlargement is essential for good outcome.
4. Both during pre- and post-operative periods, medical antioedema treatment is recommended to decrease local pressure on cortex of herniating brain tissue.
5. Factors such as age, severity of injury, systemic diseases, systemic injuries may affect the outcome after decompressive craniectomy.
6. Finally, decompressive craniectomy is an effective procedure improving survival and overall outcome in various different neurosurgical diseases.

Reference

1. Hutchinson P, Timofeev I, Kirkpatrick P. Surgery for brain edema. Neurosurg Focus 2007; 22: E14.
2. Kim KT, Park JK, Kang SG, Cho KS, Yoo DS, Jang DK, et al. Comparison of the effect of decompressive craniectomy on different neurosurgical diseases. Acta Neurochir (Wien) 2009; 151: 21–30.
3. Aarabi B, Hesdorffer DC, Ahn ES, Aresco C, Scalea TM, Eisenberg HM. Outcome following decompressive craniectomy for malignant swelling due to severe head injury. J Neurosurg 2006; 104: 469–479.
4. Reithmeier T, Löhr M, Pakos P, Ketter G, Ernestus RI. Relevance of ICP and ptiO2 for indication and timing of decompressive craniectomy in patients with malignant brain edema. Acta Neurochir (Wien) 2005; 147: 947- 952.
5. Teasdale G, Jennett B. Assessment of coma and impaired consciousness. A practical scale. Lancet 1974; 2: 81–84.
6. Woertgen C, Erban P, Rothoerl RD, Bein T, Horn M, Brawanski A. Quality of life after decompressive craniectomy in patients suffering from supratentorial brain ischemia. Acta Neurochir (Wien) 2004; 146: 691–695.
7. Salvatore C, Marco M, Antonio R, Salvatore I, Eugenio B. Combined internal uncusectomy and decompressive craniectomy for the treatment of severe closed head injury: experience with 80 cases. J Neurosurg 2008; 108: 74–79.
8. Kenning TJ, Gandhi RH, German JW. A comparison of hinge craniotomy and decompressive craniectomy for the treatment of malignant intracranial hypertension: early clinical and radiographic analysis. Neurosurg Focus 2009; 26: E6.
9. Jiang JY, Gao GY, Li WP, Yu MK, Zhu C. Early indicators of prognosis in 846 cases of severe traumatic brain injury. J Neurotrauma 2002; 19: 869–874.
10. Jiang JY, Xu W, Li WP, Xu WH, Zhang J, Zao BH, et al. Efficacy of standard trauma craniectomy for refractory intracranial hypertension with severe traumatic brain injury: a multicenter, prospective, randomized controlled study. J Neurotrauma 2005; 22: 623–628.
11. Delashaw JB, Broaddus WC, Kassell NF, Haley EC, Pendleton GA, Vollmer DG, et al. Treatment of right hemispheric cerebral infarction by hemicraniectomy. Stroke 1990; 21: 874–881.
12. Koh MS, Goh KY, Tung MY, Chan C. Is decompressive craniectomy for acute cerebral infarction of any benefit? Surg Neurol 2000; 53: 225–230.
13. Timofeev I, Hutchinson PJ. Outcome after surgical decompression of severe traumatic brain injury. Injury 2006; 37: 1125–1132.
14. Robertson SC, Lennarson P, Hasan DM, Traynelis VC. Clinical course and surgical management of massive cerebral infarction. Neurosurgery 2004; 55: 55–62,.
15. Yao Y, Liu W, Yang X, Hu W, Li G. Is decompressive craniectomy for malignant middle cerebral artery territory infarction of any benefit for elderly patients? Surg Neurol 2005; 64: 165–169.
16. Albanèse J, Leone M, Alliez JR, Kaya JM, Antonini F, Alliez B, et al. Decompressive craniectomy for severe traumatic brain injury: Evaluation of the effects at one year. Crit Care Med 2003; 31: 2535–2538.
17. Whitfield PC, Patel H, Hutchinson PJ, Czosnyka M, Parry D, Mennon D, et al. Bifrontal decompressive craniectomy in the management of posttraumatic intracranial hypertension. Br J Neurosurg 2001; 15: 500–507.
18. Buschmann U, Yonekawa Y, Fortunati M, Cesnulis E, Keller E. Decompressive hemicraniectomy in patients with subarachnoid hemorrhage and intractable intracranial hypertension. Acta Neurochir (Wien) 2007; 149: 59–65.
19. Schirmer CM, Hoit DA, Malek AM. Decompressive hemicraniectomy for the treatment of intractable intracranial hypertension after aneurysmal subarachnoid hemorrhage. Stroke 2007; 38: 987–992.
20. Stiefel MF, Heuer GG, Smith MJ, Bloom S, Maloney-Wilensky E, Gracias VH, et al. Cerebral oxygenation following decompressive hemicraniectomy for the treatment of refractory intracranial hypertension. J Neurosurg 2004; 101: 241–247.
21. Yang XF, Wen L, Shen F, Li G, Lou R, Liu WG, et al. Surgical complications secondary to decompressive craniectomy in patients with a head injury: a series of 108 consecutive cases. Acta Neurochir (Wien) 2008; 150: 1241–1248.