Effects of Nitric Oxide –Vascular Endothelial Growth Factor Systems in Chick Embryo Cerebral Vasculogenesis and Angiogenesis

Civciv Embriyosunda Serebral Vaskülogenezis ve Anjiogenezis Üzerine Nitrik Oxid – Vasküler Endotelyal Growth Faktörün Etkileri

Effects of Nitric Oxide in Vasculogenesis and Angiogenesis
Vaskülogenezis ve Anjiogenezisde Nitrik Oksidin Etkileri

Cüneyt Temiz[1], Mehmet Arslan[2], Murat Sayın[1], Seda Vatansever[3], Gülşen Giray[3], Ahmet Var[4]

[1]Departments of Neurosurgery, Celal Bayar University, Faculty of Medicine, Manisa, Türkiye.
[2]Department of Neurosurgery, Yüzüncü Yıl University, Faculty of Medicine, Van, Türkiye.
[3]Departments of Histology-Embriyology, Celal Bayar University, Faculty of Medicine, Manisa, Türkiye.
[4]Departments of Clinical Biochemistry, Celal Bayar University, Faculty of Medicine, Manisa, Türkiye.

Özet

Çalışmalar göstermiştir ki, vaskülogenezis ve angiogenezisin gelişmesinde nitric oksit ve vasküler endotelyal growth factor önemli biyolojik etkilere sahiptir. Bu çalışmada spesifik beyaz fertilize olmuş leghorin tipi yumurtalar kullanıldı. Üç başlıca alt grub dizayn edildi (kuluçkanın 48, 72 ve 80 saatlik zaman aralıklarında) . 48 saatlik embriyoda, anjioblastlar göründü, ama olgunlaşmış endotelyal yapı mevcut değildi. 72 saatlik embriyoda, endotelyal olgunlaşma başlamıştı. 80 saatlik embriyoda, oldukça yüksek seviyede endotelyal olgunlaşma mevcuttu. 48 saatlik grupta, doku nitrit-nitrat konsantrasyonları yüksekti; ama 72 saatlik grupta bu değerler bir önceki gruptan daha yüksekti. 80 saatlik grupta, nitrit-nitrat konsantrasyonları düşüktü ve 48 ve 72 saatlik gruplarla karşılaştırıldığı zaman istatiksel olarak önemli idi. Sonuç olarak, nitrik oksidin vaskülogenezis ve angiogenezisin erken döneminde etkili olduğu göründü, ama bu etki zamanla azaldı.

Anahtar Kelimeler

Angiogenezis; Vaskulogenezis; Nitrik Oxid; Vaskülar Endotelyal Growth Faktor

Abstract

Studies have depicted that nitric oxide and vascular endothelial growth factor systems have important biological effects in the development of vasculogenesis and angiogenesis. In this study; specific pathogen free white Leghorin type fertilised eggs were used. Three main subgroups were designed regarding time points of 48; 72 and 80 hours of incubation. In 48 hours old embryos anjioblasts were seen; but no mature endothelial structure was present. In 72 hours old embryos endothelial maturation began. In the 80 hours there was a high level of endothelial maturation.In all 48 hours groups; tissue nitrite-nitrate concentrations were high but in the 72 hours group these values were higher than in the first group. In the 80 hours group; concentrations were lower and were statistically significant when compared to the 48 and 72 hours groups. In conclusion; NO seems to be effective in early phases of vasculogenesis and angiogenesis; but its effect decreases with time.

Keywords

Angiogenesis; Vasculogenesis; Nitric Oxide; Vascular Endothelial Growth Factor

DOI: 10.4328/JCAM.778 Received: 18.08.2011 Accepted: 21.09.2011 Published Online: 01.10.2012 J Clin Anal Med 2012;3(4):394-398
Corresponding Author: Mehmet Arslan, Department of Neurosurgery, Yüzüncü Yıl University, Faculty of Medicine, Van, Türkiye.
T.: + 0904322150474 Fax: + 0904322168352 E-mail: arslan2002@hotmail.com

Introduction

Vascular endothelial growth factor (VEGF); secreted by vascular tissue and a variety of tumour cells; is a potent angiogenic factor and plays a significant role in both physiological and pathological angiogenesis.[1-6] Also; nitric oxide (NO) has tremendous effects on all tissues and is known to mediate angiogenesis and vascular permeability.[1-6] NO appears to play a key role in the VEGF-induced proliferation of endothelial cells.[4] VEGF is highly expressed in cerebral vascular malformations and excessive VEGF expression can induce increase vascular remodeling and hemorrhage;[2] NO is a product of the conversion of L-arginin to citrulline; which is catalysed by nitric oxide synthase (NOS).[4] There are three isoforms of nitric oxide synthase (NOS): neuronal NOS (nNOS); inducible NOS (iNOS); and endothelial NOS (eNOS).[3] VEGF stimulates NO release mediated by the VEGF receptors in human trophoblasts and also induces eNOS and iNOS expression in vascular endothelial cells in vitro;[3-4] but the inhibition of these receptors was found to result in increased cell proliferation; suggesting that NO may limit the proliferation of trophoblasts.[4] However; the inhibition of in vivo NO results in a decrease in angiogenesis and vascular permeability induced by VEGF.[3] However; the exact role of NO is controversial in cerebral angiogenesis and its mechanism is not clearly understood.

In neurosurgery; pathological states like arteriovenous malformations; cavernous angiomas; venous angiomas and tumours are common diseases that a neurosurgeon often observes in daily practice. If the vascular development of these lesions could be explained; more appropriate therapeutic attempts might be established. We hypothesized that; NO is a critical mediator in VEGF activated angiogenesis in the brain. The aim of this study is to investigate the role of NO and VEGF systems in the physiology of cerebral vasculogenesis and angiogenesis procedure in a chick embryo model.

Material and Methods

Experimental Design and embryo collection:

In this study; we used 120 specific pathogen free (SSPF) white Leghorin type fertilised eggs. These eggs were provided by the State Chick Research Centre; Manisa; Turkey and incubated at 37;8 ⍰ 0;2 ⍰C; at 65- 75 % humidity up to 48 (group 1); 72 (group 2) and 80 hours (group 3).

48; 72 and 80 hours incubated embriyos were evaluated with proper microdissection. In each time point; 10 embryos were collected for iNOS; eNOS and VEGF immunoreactive staining. In brain nitrite-nitrate assay group; early brain structures were dissected under 5X visual magnification and nitrite-nitrate tissue concentrations were determined with Greiss method (n: 10 for each time point).

Histological evaluation:

Eggs were opened after 48; 72 or 80 hours of culture time; embryos were dissected and fixed in formalin solution for 24 hours. Embryonal development was assessed regarding the Hamburger-Hamilton scale under light microscope.[7] They were washed and soaked in graded series of ethanol and embedded in paraffin. Transverse serial selections (5 microns thick) were taken from optic tectum layer of the cranium and prepared for both histochemical and immunohistochemical staining. Hematoxylin staining was used for histological observations of developmental stages of vascular endothelium. Slides were mounted using entellan and covered with glass coverslips prior to viewing and photography under the Olympus BX-40 light microscopy.

For immunohistochemical staining; sections were first incubated at 60°C overnight and then incubated in xylene for 30 min. After washing with a decreasing series of ethanol; sections were washed with distilled water and phosphate-buffered saline (PBS) for 10 min. Sections were then treated with 2% trypsin in Tris buffer (50 mM Tris base and 150 mM NaCl dissolved in deionized water) at 37°C for 15 min and washed with PBS. Sections were drawn delineated with Dako pen (Dako; Glostrup; Denmark) and incubated a solution of 3% H2O2 for 15 min to inhibit endogenous peroxidase activity. Then sections were washed with PBS and incubated for 18 h at +4°C with primary antibodies to polyclonal anti-iNOS in a 1/100 dilution (Zymed 61-770 South San Francisco; CA; USA); anti-eNOS in a 1/200 solution (Biomol S-258; Hamburg; Germany) and a monoclonal anti-VEGF antibody in 1/200 dilution (Neomarkers; Fremont; CA; USA). Afterwards; sections were washed 3 times for 5 min each with PBS; followed by incubation with biotnylated IgG and then with streptavidin-peroxidase conjugate (Dako). All incubation steps were separated by 3 washing steps. After washing 3 times for 5 min with PBS; sections were incubated with DAB substrate containing diaminobenzidine (Dako) 5 min to stain immunolabelling and then with Mayer's hematoxylin. Sections were covered with mounting medium and were analysed light microscopically with a BX 40 microscope (Olympus; Tokyo; Japan). Control samples were processed in an identical manner but the primary antibody was omited. Two observers blinded to experimental information evaluated the staining scores independently. Staining intensity was graded as mild (+); moderate (++) and strong (+++) respectively.

Biochemical evaluation:

In all groups (n:10 for each time point); each early brain structure was dissected under 5X visual magnification with microsurgical technique and placed into glass tubes; labelled and stored in a deep freeze (-80 0C) until homogenization processing. Tissues were homogenized on ice at 12000 rpm for 3 minutes using a homogenizator (IKA T25 basic U.K.) in ice cold phosphate buffer (0;01 M; pH=7.0). Since plasma nitrite (NO2-) and nitrate (NO3-) levels can be used to estimate NO production; we measured the concentrations of these stable NO oxidative metabolites. Determination of NO2- and NO3- was based on the Griess reaction in which a cromophore with a strong absorbance at 545 nm is formed by reaction of NO2- with a mixture of naphthlethylenediamine and sulfanilamide.[8] After samples were deproteinized with Somogyi reagent;[9] an aliquot of the sample was mixed with fresh reagent. 40 minutes after incubation time the absorbance was measured in a spectrophotometer (Shimadzu UV-1201; Japan) to give the NO2- concentration. A second aliquot was treated with copper-coated cadmium granules (Cd) in glycine buffer at pH 9.7 (2;5-3 g Cd granules for a 4 mL reaction mixture) to reduce NO3- to NO2-. The concentration of NO2- in this aliquot thus gave the total NO3- plus NO2-; finally representing total NO concentration. A standard curve was established with a set of serial dilutions (100 µmol/L to 5 µmol/L) of sodium nitrite. The resulting equation was then used to calculate the unknown sample concentrations.

The nitrite-nitrate data are expressed as the mean ⍰ standard deviation and were analysed by Anova-Varyans test. When there were differences between groups; Duncan test was used to definite whether there were difference between groups according to time period (48; 72 and 80 hours). A probability value of <0.05 was considered statistically significant.

Results

Group 1 (48 hours time point [Human 3;5- 4 weeks]):
In hematoxylin stained sections; the development and closure of neural tubes were complete. The development of brain vesicles; optic vesicle; paraaxial mesodermal and cardiac cells was also detected. In the neck and cranial areas of the body; angioblasts were determined but no vascular or endothelial structure had developed (Figure 1a). iNOS immunoreactivity was negative in the whole embryo and in immature neural tissue (Figure 1b); but in a few angioblasts; mild immunoreactivity of eNOS was detected (Figure 1c). Consequently; VEGF immunoreactivity was observed strongly; mainly surrounding matrix of angioblasts (Figure 1d). The result of nitrite-nitrate measurement was 6;16 0;31 micromol/ tissue weight [per gram] (Diagram 1).
Group 2 (72 hours time point (Human 6 weeks)):
In hematoxylin stained sections; the development of brain vesicles was complete; optic vesicle differentiation continued and the major parts of eye differentiation were almost done. Cardiac atrium and ventricles were differentiated; and red blood cells could be seen in these structures. Arteriolar development was completed and endothel formation was almost finished (Figure 2a). While iNOS immunureactivity was still absent in the whole section (Figure 2b); eNOS reactivity was strongly positive; especially in endothelial layer and periarterial mesenchymal tissue (Figure 2c). VEGF reactivity was still strong; especially in endothelial and surrounding tissue (Figure 2d). The result of nitrite-nitrate measurement was 5;97 0;89 micromol/ tissue weight (per gram) (Diagram 1) . This value was no meaningful statistically compared to group 1 ($p < 0.05$); but this value was slightly low (Table 1).
Group 3 (80 hours time point (Human 8- 10 weeks):

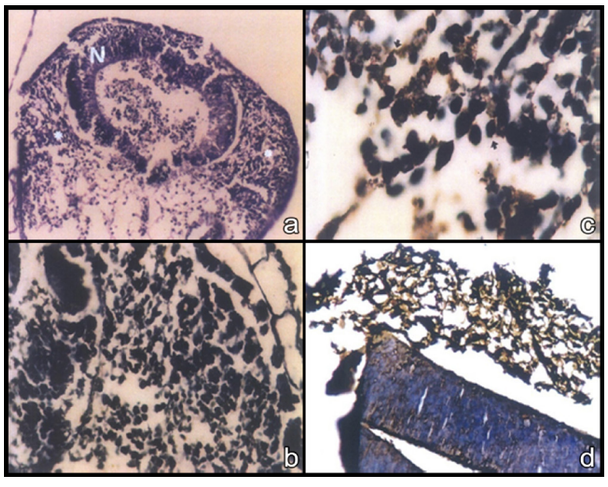

Figure 1. Histochemical and immunohistochemical observation of chick embryo from 48 hours time point. Hemotoxylin staining of sections depicting vascular development in 48 hours time point (N: Notochord; *: Paraaxial mesoderma)(A). iNOS immunostaining of cerebral tissue in 48 hours depicting low staining especially around endothelium and surrounding parenchymal tissue(B). eNOS immunostaining of cerebral tissue in 48 hours depicting high activity especially around endothelium and surrounding parenchymal tissue (arrow) (C). VEGF immunostaining of cerebral tissue in 48 hours depicting high activity especially around endothelium and surrounding parenchymal tissue (D).

Table1. The results of descriptive statistics and comparison for N-Nitrat ngr/pgm

	N	Mean	Std. Deviation		Minimum	Maximum
p.						0;001
48 Hours	10	6;1610 a	;49637	5;17	6;71	
72 Hours	10	5;9740 a	;65104	4;95	6;86	
80 Hours	10	;7800 b	;17544	;56	1;02	
Total	30	4;3050	2;57888	;56	6;86	

There were significant differences statistically between group 3 and other groups ($P < .05$). Difference between group 1 and group 2 was no meaningful ($P < ..05$) .

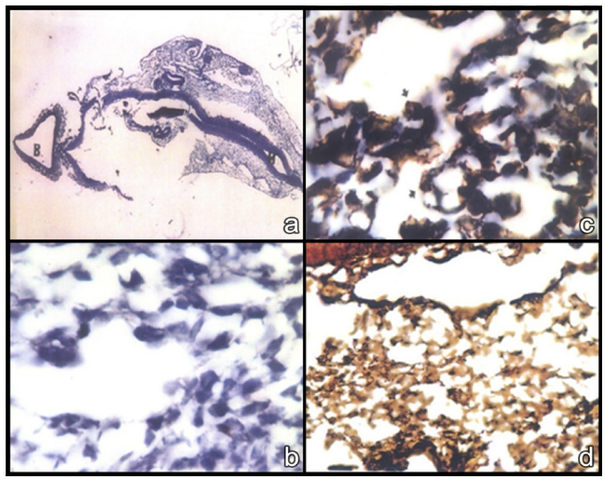

Figure 2. Histochemical and immunohistochemical observation of chick embryo from 72 hours time point. Hemotoxylin staining of sections depicting vascular development in 72 hours time point (B: Brain) (A). iNOS immunostaining of cerebral tissue in 72 hours depicting low staining especially around endothelium and surrounding parenchymal tissue (B). eNOS immunostaining of cerebral tissue in 72 hours depicting high activity especially around endothelium and surrounding parenchymal tissue (arrow) (C). VEGF immunostaining of cerebral tissue in 72 hours depicting high activity especially around endothelium and surrounding parenchymal tissue (D).

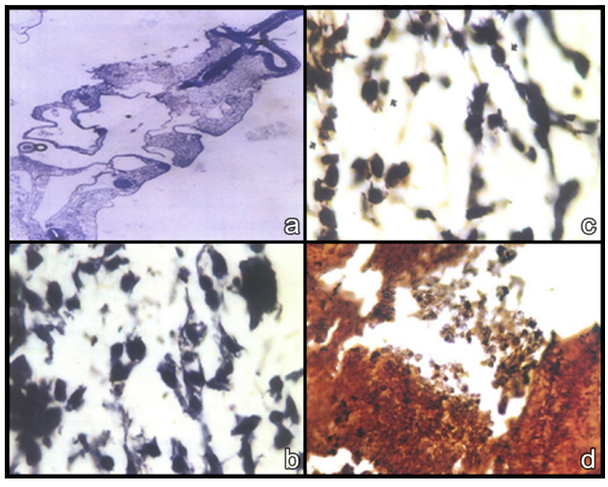

Figure 3. Histochemical and immunohistochemical observation of chick embryo from 80 hours time point. Hemotoxylin staining of sections depicting vascular development in 80 hours time point (A). iNOS immunostaining of cerebral tissue in 80 hours depicting low staining especially around endothelium and surroun ing parenchymal tissue (B). eNOS immunostaining of cerebral tissue in 80 hours depicting high activity especially around endothelium and surrounding parenchymal tissue (arrow) (C). VEGF immunostaining of cerebral tissue in 80 hours depicting high activity especially around endothelium and surrounding parenchymal tissue (D).

Diagram 1. Chick embryo cerebral tissue nitrite- nitrate concentration values regarding time points (micromol/tissue weight/per gram) (mean SD)

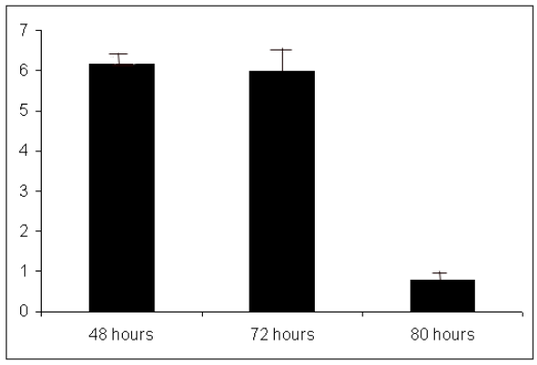

In this time point; the development of optic vesicles was completed. Arteriolar development was also finished and a significant amount of vascular tissues containing endothelium was observed (Figure 3a). eNOS immunoreactivity was decreased to moderate level in all embryonic tissues at this stage; it could still be seen in endothelial layer; but periarteriolar activity was suppressed (Figure 3c). iNOS activity was still negative (Figure 3b). Although VEGF activity was decreased minimally; it was still strongly positive in this stage especially in endothelial layer and periarteriolar mesenchymal tissue (Picture 3d). The result of nitrite-nitrate measurement was 0;78 0;28 micromol/ tissue weight (per gram) (Diagram 1). This result was lower than those of group 1 and 2. There were significant statistical differences when this value was compared to group 1 and group 2 ($P < .05$) (Table 1).

Discussion

Angiogenesis is the major key factor for growth of new tissues; but factors that contribute angiogenesis are still unclear. It has been shown that VEGF has important effects in angiogenesis and vasculogenesis via its R1 and R2 receptors.[10] It has been also suggested that depletion of VEGF in angioblasts causes inadequate vasculogenesis.[11] Based on literature; however; findings are conflicting with respect to the exact role of NO in angiogenesis. An increased level of NO has been found in human tumors.[6] Blocking NOS activity has been shown to retard the growth of tumors; excessive production of NO increases tumor growth.[6] Many conflicts about the effects of NO on vasculogenesis and angiogenesis have been seen for a few years. Jadeski et al.[12] reported that inhibition of NOS by L-nitroarginine methyl ester (L-NAME) depressed neovascularisation inducted by a rat's mamillary tumour. Murohara et. al.[13] showed that in Albino Guinea pigs; L-NAME (20 mg/kg) inhibited the most important part of vasculogenesis and the increase of vascular permeability by a VEGF pathway. In a study by Kang et al.;[14] inhibition of NO by L-NAME was also diminished. neovascularisation in a sick rat's kidney model. In addition; application of L-NAME prior to VEGF caused an inhibition of vascular permeability.[15] Inhibition of NO system was also decreased angiogenesis in a rat' and a rabit's cornea models.[16] Papapetropoulos suggests that vascular proliferation induced by VEGF has been mediated by NO and could be blocked by L-NAME; in human umbilical venous cell culture.[17] It was suggested that VEGF also caused new vascularisation via NO system and these effects could be diminished by L-NAME.[18-20] In contrast to these authors; some reports suggest that NO could not affect vasculogenesis and angiogenesis procedure. For example; Norrby et al.[11] noted that NO system inhibition by L-NAME did not inhibit angiogenesis mediated by VEGF165. For this reason Pipili-Synetos et al.[21-22] suggested in two different studies that inhibition of NO system had increased angiogenesis in a chick embryo's chorioallantoic membrane model. The mechanism of the effects of NO is not clearly understood yet.

In this study we want to evaluate the relationship between physiological development and VEGF-NO system of chick embryo cerebral vascular structure. In the current study; VEGF could be seen in all stages of vasculogenesis and angiogenesis. Although iNOS activity was not positive in all phases in physiological condition; eNOS activity was strongly positive in early stages and it was decreased in later phases.

Some questions still need consideration. For example; do the immunoreactivity of NOS and VEGF system really resemble function al angiogenesis and vasculogenesis? Or; does iNOS system have any effect on vasculogenesis and angiogenesis? We believe that the answer to the first question was given by the measurement of embryonic cerebral tissue nitrite-nitrate values. In the literature we were not able to find any knowledge about concentrations of nitrite and nitrate levels of embryonic cranial tissues on this experimental protocol.

Nitrite-nitrate values were high especially at the 48 hours time point. Levels then minimally decreased in 72 hours and dramatically decreased when the 80 hours time point was reached. There was no statistically meaningful difference between 48 and 72 hours groups values; but the 80 hours group values showed statistically meaningful difference in comparison to the 48 and 72 hours groups values ($P < .05$). These results may be an indicator for the effect of NO system and they may be confirmed with the immunohistochemical result. The answer to the second question is clearer. Tissue ichemia initiates angiogenesis procedure and this causes VEGF expression from endothelial cells. Then; gap junctions of endothelial cell line become more loose. This local reaction causes increased permeability. A little gap opens and endothelial cells migrate from this gap. Then; the proliferation of these cells form a primary skeleton of a vessel. In this procedure we can be suggest that iNOS activation from parenchyma of the brain plays a role in this step of the procedure. But regarding our results; it seems that iNOS activation has no effect during the vasculogenesis and angiogenesis procedures. Also; VEGF values were higher when eNOS values were high. But with time; eNOS activity decreased as well as VEGF values. This situation was evident especially at 72 and 80 hours time points.

It can be estimated that in vasculogenesis procedure; VEGF and eNOS activity have great importance and work together during brain vasculogenesis. But as the time passes when vasculogenesis is over and angiogenesis starts; many other factors may be involved in this procedure and the effect of NO decreases. And another important point is that the vasculogenesis and angiogenesis procedures are realized by primary canalisation conducted by endothelial function in cooperation with VEGF- NO system. In our study; a significant correlation between eNOS and VEGF was found in angiogenesis; suggesting that there may be a direct relationship between the presence of NO and VEGF in the regulation of angiogenesis. In previous studies; however; iNOS was found to be high and excessive NO production mediated by iNOS has been implicated in the pathogenesis of various diseases.[6] They hypothesized that enhanced iNOS production supports the role of NO as a mediator of physiological and pathological processes.[6] Moreover; it may be speculated that the presence of iNOS in cerebral malformations reflects an increased production of NO.[6] However; from the current data; it is not possible to elucidate the exact role of NO in the regulation of cerebral angiogenesis. We view the presence of eNOS in cerebral angiogenesis as a reactive process. In future more studies will be needed to evaluate the exact mechanism of the signalling pathway regarding the vasculogenesis and angiogenesis procedure. In our study; we found that in the early stages of procedure [48 and 72 hours]; iNOS immunoreactivity was low whereas eNOS and VEGF reactivities were high. In 80 hours; eNOS and VEGF immunureactivities started to decrease. iNOS reactivity was absent. It seems that VEGF and eNOS activities initiate the procedure and then decrease. iNOS showed no activity during all phases.

In conclusion; NO and VEGF seems to be effective in early phas-

es of vasculogenesis and angiogenesis. VEGF may contribute to angiogenesis and eNOS probably play an important role.

References

1. Bouloumie A; Schini-Kerth VB; Busse R. Vascular endothelial growth factor up-regulates nitric oxide synthase expression in endothelial cells. Cardiovasc Res. 1999;41:773-780.
2. Lee CZ; Xue Z; Hao Q; Yang GY; Young WL. Nitric oxide in vascular endothelial growth factor-induced focal angiogenesis and matrix metalloproteinase-9 activity in the mouse brain. Stroke. 2009;40:2879-2881.
3. Fukumura D; Gohongi T; Kadambi A; Izumi Y; Ang J; Yun CO; Buerk DG; Huang PL; Jain RK.Predominant role of endothelial nitric oxide synthase in vascular endothelial growth factor-induced angiogenesis and vascular permeability. Proc Natl Acad Sci U S A. 2001 ;98:2604-2609.
4. Cha MS; Lee MJ; Je GH; Kwak JY. Endogenous production of nitric oxide by vascular endothelial growth factor down-regulates proliferation of choriocarcinoma cells. Biochem Biophys Res Commun. 2001;28:1061-1066.
5. Tu YT; Tao J; Liu YQ; Li Y; Huang CZ; Zhang XB; Lin Y. Expression of endothelial nitric oxide synthase and vascular endothelial growth factor in human malignant melanoma and their relation to angiogenesis. Clin Exp Dermatol. 2006;31:413-418.
6. Hattenbach LO; Falk B; Nürnberger F; Koch FH; Ohrloff C. Detection of inducible nitric oxide synthase and vascular endothelial growth factor in choroidal neovascular membranes. Ophthalmologica. 2002;216:209-214.
7. Hamburger V; Hamilton H.L. A series of normal stages in the development of the chick embryo. J Morph. 1951;88:49-92.
8. Cortas N.K; Wakid W.W. Determination of inorganic nitrate in serum and urine by a kinetik cadmium-reduction method. Clin Chem. 1990;36(8):1440-1443.
9. Somogyi M. A method for the preparation of blood filtrates for the determination of sugar. J Biol Chem. 1930; 86: 655-661.
10. Giles J.J; Bannigan J.G. The effect of lithium on vascular development in the chick area vasculosa. J. Anat. 1999;194:197-205.
11. Norrby K. Nitric oxide suppresses bFGF- and IL-1 alpha- mediated but not VEGF165 – mediated angiogenesis in natively vascularized mammalian tissue. APMIS. 1998;106:1142-1148.
12. Jadeski L.C; Lala P.K. Nitric oxide synthase inhibition by N-Nitro-L-Arginine-Methyl Ester inhibits tumor-induced angiogenesis in mammary tumors. Am.J.Pathol. 1999;155:1381-1390.
13. Murohara T; Horowitz J.R; Silver; Tsurumi; Chen D; Sullivan A; Isner J.M. Vascular endothelial growth factor/ vascular permeability factor enhances vascular permeability via nitric oxide and prostacyclin. Circulation. 1998;97:99-107.
14. Kang D.H; Nagakawa T; Feng L; Johnson R. J. Nitric oxide modulates vascular disease in the remnant kidney model. Am.J.Pathol. 2002;161/1:239-248.
15. Witzenbichler B; Asahara T; Murohara T; Silver M; Spyridopoulos I; Magner M; Principe N; Kearney M; Hu J.S; Isner J.M. Vascular endothelial growth factor-C (VEGF-C/VEGF-2) promotes angiogenesis in the setting of tissue ischemia. Am. J. Pathol. 1998; 153/2: 381-394.
16. Ziche M; Morbidelli L; Choudhuri R; Zhang H.T; Donnini S; Granger H.J; Bicknell R. Nitric oxide synthase lies downstream from vascular endothelial growth factor- induced but not basic fibroblast growth factor-induced angiogenesis. J. Clin. İnvest. 1997:99: 2625- 2634.
17. Papapetropoulos A; Garcia-Cardena G; Madri J.A; Sessa W.C. Nitric oxide production contributes to the angiogenic properties of vascular endothelial growth factor in human endothelial cells. J.Clin.Invest. 1997;100/12: 3131-3139.
18. Babaei S; Stewart D.J. Overexpression of endothelial NO synthase induces angiogenesis in a co-culture model. Cardiovascular Research. 2002;55:190-200.
19. Dulak J; Jozkowicz A. Nitric oxide and angiogenic activity of endothelial cells: Direct or VEGF - dependent effect? Cardiovascular Research. 2002;56:487-488.
20. Kon K; Fujii S; Kosaka H; Fujiwara T. Nitric oxide synthase inhibition by N-nitro-L-arginine methyl ester retards vascular sprouting in angiogenesis. Microvascular Research. 2003: 65: 2-8.
21. Pipili-Synetos E; Sakkoula; Maragoudakis M.E. Nitric oxide is involved in the regulation of angiogenesis. Br.J.Pharmacol. 1993; 108:855-857.
22. Pipili-Synetos E; Kritikou S; Papadimitriou; E; Athanassiadou A; Flordellis C; Maragoudakis M.E. Nitric oxide synthase expression; enzyme activity and NO production during angiogenesis in the chick chorioallantoic membrane. Br.J.Pharmacol. 2000; 129: 207-213.