Simultaneous Pulmonary and Transdiaphragmatic Surrenal Resection in Non-small Celled Lung Cancer

Küçük Hücreli Dışı Akciğer Kanserinde Eş Zamanlı Akciğer ve Transdiyafragmatik Sürrenal Rezeksiyonu

Eş Zamanlı Akciğer ve Sürrenal Rezeksiyonu / Simultaneous Lung and Surrenal Resection

A. Irfan Tastepe[1], Ulku Yazici[2], Pinar Bicakcioglu[2], S.S. Erkmen Gulhan[2], Yetkin Ağackiran[3]
[1]Department of Thoracic Surgery, Gazi University Medical Faculty, Besevler, [2]Department of Thoracic Surgery,
[3]Department of Pathology, Ataturk Education and Research Hospital for Chest Diseases and Thoracic Surgery, Kecioren, Ankara, Turkey

The article reported as an oral presentation round of 5th Thoracic Surgery Congress in 2009, Kuşadası.

Özet

Amaç: Günümüzde evre IV küçük hücreli dışı akciğer kanseri olgularından, yalnızca seçilmiş soliter beyin ve sürrenal metastazları cerrahi tedavi için uygun görülmektedir. Rezektabl akciğer kanserli olgularda sürrenal rezeksiyonu sağ kalımı artırmaktadır. Gereç ve Yöntem: Kliniğimizde rezektabl küçük hücreli dışı akciğer kanseri ve izole sürrenal metastaz ön tanısı ile 6 olgu opere edildi. 18F-fluorodeoxyglucose pozitron emisyon tomografi değerlendirmesinde olguların tamamında aynı taraf sürrenal dokuda tutulum mevcuttu. Sürrenal doku patolojik tutulum değerleri 3,71- 20,50 arasındaydı. Bulgular: Dört olguya pnömonektomi, 2 olguya üst lobektomi yapıldı. Eş zamanlı transdiyafragmatik sürrenalektomi yapılan olguların patolojik incelemelerinde 1 olguda sürrenal dokuda tümöral tutulum, 1 olguda adrenokortikal adenom, 2 olguda sürrenal doku hiperplazisi izlendi. Operasyon öncesi kemoterapi alan 2 olgudan 1 tanesinde sürrenal dokuda ve akciğerde tümöral tutulum izlenmez iken diğer olgumuzda sadece sürrenal dokuda tümör izlenmedi. Sonuç: Rezektabl küçük hücreli dışı akciğer kanseri ve aynı taraf izole sürrenal lezyonu olan olgularda, tek bir cerrahi yaklaşımla, eşzamanlı akciğer kanseri cerrahisi ve transdiyafragmatik sürrenal rezeksiyonu güvenilir bir şekilde yapılabilir.

Anahtar Kelimeler

Küçük Hücreli Dışı Akciğer Kanseri; Adrenalektomi; Metastaz

Abstract

Aim: Of the cases with stage IV non-small celled lung cancer, only selected few with solitary brain and surrenal metastases are considered for surgical treatment. Surrenal resection has extended the survival in cases with resectable lung cancer. Material and Method: Six patients with prediagnosis of resectable non-small celled lung cancer and solitary surrenal metastasis at the same side were operated in our clinic. In the evaluations with 18F-fluorodeoxyglucose positron emission tomography, the surrenal tissues of the same side were involved in all the patients. The pathological involvement rate of the surrenal tissues was 3.71- 20.50. Results: Four patients underwent pneumonectomy and two patients, upper lobectomy. Pathology evaluation of the patients who were performed transdiaphragmatic surrenalectomy indicated tumor involvement of the surrenal tissue in one patient, adrenocortical adenoma in one patient, surrenal tissue hyperplasia in two patients. One of the two patients who received chemotherapy preoperatively had no tumor invasion in the surrenal tissue or the lungs, while the other patient had no tumor invasion in the surrenal tissue only. Discussion: In cases with resectable NSCLC and isolated surrenal lesion on the same side, lung cancer surgery and transdiaphragmatic surrenal resection can be performed safely in one operation.

Keywords

Non Small Cell Lung Carsinom; Adrenalectomy; Metastasis

DOI: 10.4328/JCAM.992 Received: 07.04.2012 Accepted: 15.04.2012 Printed: 01.03.2013 J Clin Anal Med 2013;4(2): 138-140
Corresponding Author: Pinar (Yaran) Bicakcioglu, Department of Thoracic Surgery, Ataturk Training and Research Hospital for Chest Disease and Thoracic Surgery, Kecioren, Ankara 06280 Turkey. T.: +90 3123552110 F.: +90 3123552135 E-Mail: piyaren@gmail.com

Introduction

In respectable non-small celled lung cancer (NSCLC), surrenal metastasis is common, while its isolated form is a rare occurrence. In the presence of isolated surrenal metastasis, non-surgical approaches yield poor survival time. Although there are limited number of studies on the removal of surrenal metastasis in cases with resectable lung cancer, surrenal resection has extended the survival [1,2]. Thus, in the presence of isolated surrenal metastasis in NSCLC, surrenal resection is recommended. When surrenal metastasis and lung cancer involve the same side, transdiaphragmatic approach is a safe and effective method. In the same operation, both lung surgery and resection of the surrenal tissue through transdiaphragmatic approach can be performed safely. In this study, we aimed to share our experience with 6 cases in order to emphasize the feasibility of this technique.

Material and Method

Six patients with prediagnosis of resectable NSCLC and solitary surrenal metastasis at the same side were operated in our clinic between 2007 and 2009. All of our patients were male smokers and the mean age of the patients was 58.8 years (range: 55-69 years). All the patients were subjected to routine laboratory tests, respiratory function tests, pulmonary graph, thorax computerized tomography (CT), abdominal ultrasonography, cranial tomography, and 18F-fluorodeoxyglucose positron emission tomography (18F- FDG-PET). According to the results of 18F-FDG-PET, the involvement rate of the surrenal area was 3.71-20.50. Further evaluations indicated that these patients with prediagnosis of resectable NSCLC had no metastasis in any other areas but solitary surrenal metastasis was suspected. All the patients underwent mediastinoscopy. In three patients, right thoracotomy and in the other three patients, left thoracotomy was performed. All the patients were performed complete resection for lung cancer and mediastinal lymph node dissection.

As a surgical approach, posterolateral thoracotomy through 6th intercostals space was planned. After resective lung cancer surgery, transdiaphragmatic surrenalectomy was performed. On both sides, a slightly inclined incision of 6-7 cm was inflicted through posterolateral of the diaphragm. The surrenal gland was at an easily accessible location in the retroperitoneal fat tissue (Figure.1). The surrenal gland is easily distinguished with its unique bright orange color and has three groups of arteries and one group of veins. Careful dissection and ligation of the vascular structures of the surrenal gland is important. To this end, we use electrothermal bipolar vessel sealer (Ligasure; Valleylab, Boulder, CO, USA), which facilitates safe hemostasis and to date, no complications of hemorrhage have occurred. After the completion of resection, the retroperitoneal area was evaluated for bleeding. The diaphragm was sutured with non-absorbable material.

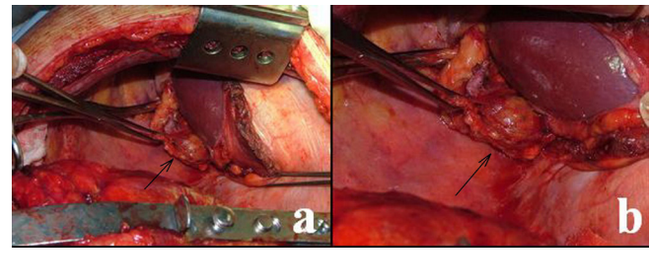

Figure 1. Intraoperative view of transdiaphragmatic surrenal gland resection (A, B)

Results

This technique was safely performed on 6 selected patients. Surrenal resection was achieved in the same operation; thus, a second operation was not needed. Histopathological studies showed surrenal metastasis in one patient, adrenocortical adenoma in one patient, and surrenal hyperplasia in two patients. In one of the two patients who had received chemotherapy preoperatively, no tumors were observed in the lung or the surrenal area. In the other one, there was a tumor in the lung but none in the surrenal area. The surgical treatment, stages, and follow-up durations of our patients have been presented in Table 1.

Table 1. Surgical treatment and pathological characteristics of the patients who underwent lung and surrenal gland resection.

Patient no/ age/ sex	Primary lung cancer histologic type	PET SUV max Lung/Surrenal	Surgical treatment	Postoperative primary lung cancer stage	Neoadjuvant/ Adjuvant therapy	Recurrence	Survival after adrenalectomy (months)
1/54/Male	Squamous cell	21,30/20,50	Right Pneumonectomy/ surrenalectomy	T2N0M0	KT/KT	No	20
2/55/Male	Adenocarcinoma	19,5/12,2	Left Pneumonectomy/ surrenalectomy	T2N0M1	None/KT	Yes	18
3/55/Male	Squamous cell	24,18/3,75	Left upper lobectomy/ surrenalectomy	T2N0M0	None/None	No	7
4/69/Male	Adenosquamous	27,38/3,10	Right upper lobectomy/ surrenalectomy	T2N2M0	None/KT	No	6
5/61/Male	Squamous cell	21,19/5,12	Left Pneumonectomy/ surrenalectomy	T2N1M0	None/KT	No	4
6/58/Male	Squamous cell	44,1/5,0	Right Pneumonectomy/ surrenalectomy	T4N0M0	KT/KT	No	2

SUVmax: maximum standardized uptake value, KT: chemotherapy

Discussion

Although effectiveness of surgical treatment of resectable NSCLC cases with isolated surrenal metastasis is not clearly established, recent studies have shown positive effects of surrenal resectionon on survival [1-3]. Particularly in the presence of metacronous adrenal metastasis with over 6 months of disease-free time, the rate of 5-year survival has been reported to reach 38 % after resection [4]. Shorter than 6 months of disease-free time until synchronized metastases and surrenal metastasis are diagnosed is considered indicators of poor sur-

vival, and factors such as the histology of the primary tumor, T and N stages, and the diameter of the metastasis do not affect survival [2,3,5].

18F- FDG-PET is a valuable tool because it is a non-invasive method for differentiation of benign and malignant adrenal lesions and determination of any metastatic focus in the body. The results of 18F- FDG-PET evaluation in our study showed that the pathological involvement of surrenal tissue in our patients ranged from 3.71 to 20.50. In one patient with an involvement rate of 12.2%, surrenal metastasis was detected. 18F- FDG-PET has 93% sensitivity and 90% specificity in differentiation of benign and malignant surrenal lesions; however, it provides false positive results most frequently for pheochromocytomas and benign adenomas. Accordingly, one of the patients in our study was diagnosed with adrenocortical adenoma based on histopathological evaluations [6,7]. Of the 6 patients who were suspected for surrenal metastasis according to the results of 18F- FDG-PET, in only one patient metastasis was determined. Thus, it should be kept in mind that every 18F- FDG-PET uptake is not metastasis.

There are various surgical methods described for surrenal resection. Open or laparoscopic surrenalectomy will necessitate a second operation and result in accompanying complications, which will also lead to loss of time. Transdiaphragmatic approach, however, facilitates surgery in one operation and with one incision. The operation time is prolonged nearly by 40 minutes, but this does not put an additional burden on the patient. Through this approach, surrenal tissue is easily accessed transdiaphragmatically. The 6th intercostal space preferred in our operations is a proper area to perform surgery in both the lungs and surrenal tissue. Similarly, Hunt et al achieved lung cancer surgery through 5th intercostal space for a similar approach and preferred a second thoracotomy through 7th space for surrenal resection1. Either approach may be used depending on the surgeon's preference.

In conclusion, surgery of isolated surrenal metastasis in resectable NSCLC may provide long survival. Particularly in the presence of surrenal metastasis located at the same side where lung cancer is, transdiaphragmatic approach is an easy and safe method and it spares the patient from additional surgical interventions. High levels of pathological uptake in the surrenal area by 18F- FDG-PET evaluations should provoke suspicions of metastasis; however, surrenal pathologies that lead to false positive results should also be kept in mind.

References

1. Luketich JD, Burt ME. Does resection of adrenal metastases from non-small cell lung cancer improve survival? Ann Thorac Surg 1996;62(12):1614-6.
2. Porte H, Siat J, Guibert B, Lepimpec-Barthes F, Jancovici R, Bernard A, et al. Resection of adrenal metastases from non-small cell lung cancer: a multicenter study. Ann Thorac Surg 2001;71(3):981-5.
3. Kim SH, Brennan MF, Russo P, Burt ME, Coit DG. The role of surgery in treatment of clinically isolated adrenal metastasis. Cancer 1998;82(2):389-95.
4. Mercier O, Fadel E, Perrot de M, Mussot S, Stella F, Chapelier A, et al. Surgical treatment of solitary adrenal metastasis from non-small cell lung cancer. J Thorac Cardiovasc Surg 2005;130(7):136-40.
5. Higashiyama M, Doi O, Kodama K, Yokouchı H, Imaoka S, Koyama H. Surgical treatment of adrenal metastasis following pulmonary resection for lung cancer: Comparison of adrenalectomy with palliative therapy. Int J Surg 1994;79(2):124-9.
6. Yun M, Kim W, Alnafisi N, L Lacorte, S Jang A. 18F-FDG PET in characterizing adrenal lesions detected on CT or MRI. J Nucl Med 2001;42(12):1795-9.
7. Shulkin BL, Koeppe RA, Francis IR, Deeb GM, Lloyd RV, Thompson NW. Pheochromocytomas that do not accumulate metaiodobenzylguanidine: localization with PET and administration of FDG. Radiology 1993;186(3):711-5.