Use of Ivabradine in a Patient Having Pacemaker and Inappropriate Sinus Tachycardia

Uygunsuz Sinüs Taşikardisi Nedeniyle Pacemaker Takılan Hastada Ivabradin Kullanımı

İvabradin ve Uygunsuz Sinüs Taşikardisi / Ivabradine and Inappropriate Sinus Tachycardia

Yeşim Hoşcan[1], Halil Olcay Eldem[1], Haldun Müderrisoğlu[2]
[1]Department of Cardiology, Başkent University Alanya Research and Practice Center, Alanya, Antalya, Türkiye.
[2]Department of Cardiology, Başkent University, Faculty of Medicine, Ankara, Türkiye.

Özet

Ivabradin spesifik ve doz bağımlı If inhibitörüdür, sadece kalp hızını düşürerek anti iskemik etki gösterir. Normal sinüs ritmi olan ve beta blokerler için kontrendikasyonu veya intoleransı olan hastalarda kronik stabil angina pektorisin semptomatik tedavisinde kullanılır. Ivabradini pacemaker'ı olan bir hastada hız kontrolü için kullandığımız bir olguyu sunmaktayız.

Anahtar Kelimeler

İvabradin; Pacemaker; Uygunsuz Sinüs Taşikardisi

Abstract

Ivabradine is a specific and dose dependent inhibitor of If and shows antiischemic effect only by reducing heart rate. It is used in the symptomatic treatment of chronic stable angina pectoris in patients who has normal sinus rhythm and contraindication or intolerance for beta blockers. We report a case in which we used ivabradine for rate control in a patient who has pacemaker.

Keywords

Ivabradine; Pacemaker; Inappropriate Sinus Tachycardia

DOI: 10.4328/JCAM.646 Received: 11.03.2011 Accepted: 23.03.2011 Published Online: 01/05/2013 J Clin Anal Med 2013;4(3):225-226
Corresponding Author: Yeşim Hoşcan, Department of Cardiology, Başkent University Alanya Research and Practice Center, Alanya, Antalya, Türkiye.
Fax: +902425115563 E-mail: yucarci@yahoo.com

Introduction

Inappropriate sinus tachycardia (IST) is an uncommon atrial tachycardia characterized by inappropriate tachycardia and exaggerated acceleration of heart rate with "normal" P waves. Heart rate (HR) is usually ≥100 bpm at rest or triggered by minimal physiological stress. The clinical presentation of IST is highly varied and ranges from short episodes of palpitations associated with dyspnea, atypical precordial pain, cephalalgia, fatigue, and occasional syncope and presyncope to incapacitating incessant tachycardia. In general, IST is a diagnosis made by exclusion. The therapy for IST has generally been limited to beta-blockers, calcium channel blockers, antiarrhythmic drugs, and sometimes radiofrequency ablation.[1,2]

Case Report

We present the case of a 74-year-old man with sinusal tachycardia and having a VDD pacemaker. He was referred to our center for palpitations, chest discomfort, dyspnea, and reduction in exercise capacity. His blood biochemistry and thyroid function were normal, and a transthoracic echocardiogram demonstrated a structurally normal heart. Patient was on follow up for serious chronic obstructive lung disease. At first, diltiazem was given because of the high sinusal rates (Figure I). But the patient couldn't tolerate this because of hypotension. After that, ivabradine was initiated with the dose of 2x2.5 mg and the dose was increased to 2x5 mg. Rate control was achieved in patient (Figure II). Symptoms are also improved.

Discussion

Ivabradine is a selective inhibitor of the If current that contributes to sinus node automaticity.[3] It is used in the symptomatic treatment of chronic stable angina pectoris in patients who has normal sinus rhythm and contraindication or intolerance for beta blockers or calcium channel blockers.[4-5] Blocking If channels of pacemaker cells allows HR reduction without affecting myocardial contractility, relaxation and peripheral vascular resistance.[6] This feature is crucial, as hypotensive response to other negative chronotrophic medications such as beta-blockers and calcium channel blockers may limit their widespread use as in our case. Therefore ivabradine, it has been recently suggested a new therapeutic step before invasive sinus node modulation.[7]

We used ivabradine for rate control in a patient who has pacemaker and it was successfully controlled the rate. Larger studies are needed to demonstrate the use of ivabradine in also patients with cardiac pacemaker.

References

1. Brady AP, Low PA, Shen WK: Inappropriate sinus tachycardia, postural orthostatic tachycardia syndrome and overlapping syndromes. PaceClin Electrophysiol 2005;12:1112-1121.
2. Still AM, Raatikainen P, Ylitalo A, Kauma H, Ik¨aheimo M, Antero Kes¨aniemi Y, et al: Prevalence, characteristics and natural course of inappropriate sinus tachycardia. Europace 2005;7:104-112.
3. Yusuf S, Camm AJ. The sinus tachycardias. Nat Clin Pract Cardiovasc Med. 2005; 2:44–52.
4. Borer JS, Fox K, Jaillon P, Lerebours G; Ivabradine Investigators Group. Antianginal and antiischemic effects of ivabradine, an If inhibitor, in stable angina. Circulation, 2003; 107: 817–823.
5. Tardif JC, Ford I, Tendera M Bourassa MG, Fox K; INITIATIVE Investigators.. Efficacy of ivabradine, a new selective If inhibitor, compared with atenolol in patients with chronic stable angina. Eur Heart J, 2005; 26: 2529–2536.
6. Savelieva I, Camm AJ. If inhibition with ivabradine: electrophysiological effects and safety. Drug Saf, 2008; 31: 95–107.
7. Schulze V, Steiner S, Hennersdorf M, Strauer BE. et al. Ivabradine as an alternative therapeutic trial in the therapy of inappropriate sinus tachycardia: a case report. Cardiology, 2008; 110: 206–208.

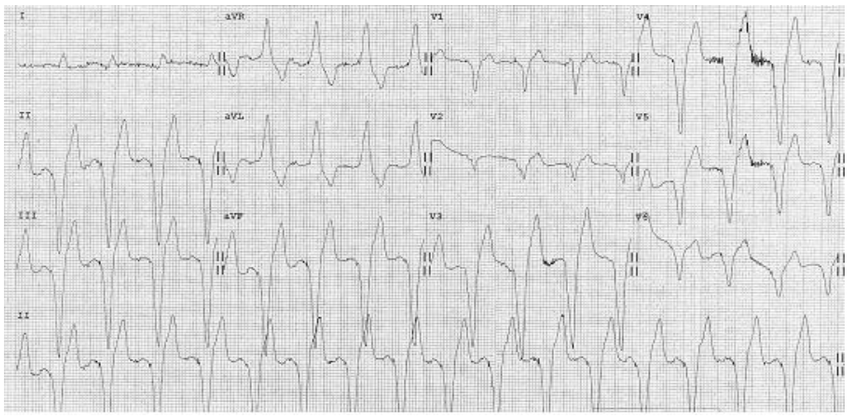

Figure 1. Electrocardiography showing inappropriate sinus tachycardia in patient with VDD pacemaker.

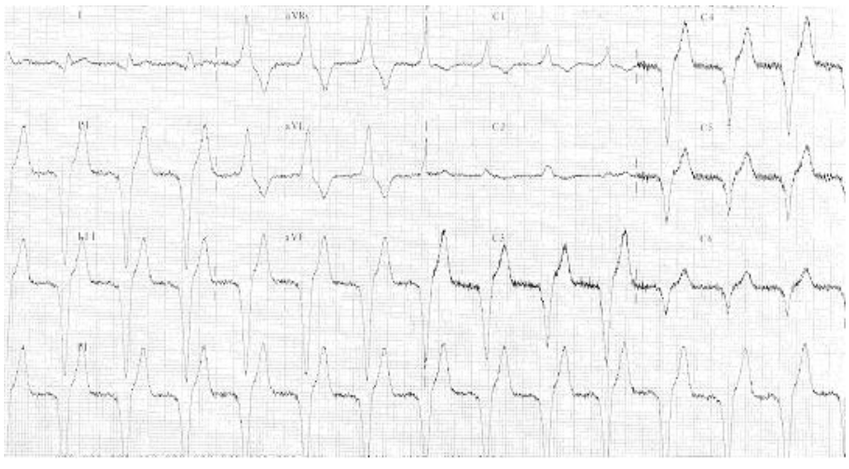

Figure 2. Electrocardiography showing heart rate control after ivabradine treatment.