A Case of Medallion-Like Dermal Dendrocyte Hamartoma with a Distinctive Size and Vascular Component

Büyük Çaplı ve Belirgin Vasküler Komponentli Madalyon Benzeri Dermal Dendrositik Hamartoma

Madalyon Benzeri Dermal Dendrositik Hamartoma / Medallion-Like Dermal Dendrocyte Hamartoma

Didem Dinçer[1], Mehmet Gamsızkan[2], Erol Koç[1], Özay Gököz[3]
[1]Department of Dermatology, GATA Faculty of Medicine, Ankara, Türkiye.
[2]Laboratory of Pathology, Ankara Military Hospital, Ankara, Türkiye.
[3]Department of Pathology, Hacettepe University Faculty of Medicine, Ankara, Türkiye.

Özet

Madolyon benzeri dermal dendrosit hamartom yeni tanımlanmış, oldukça nadir konjenital bir lezyondur. Lezyon, karakteristik olarak asemptomatik, iyi sınırlı, kırmızı-kahve renkte, atrofik madalyon şeklinde bir yama olup gövde üst yüz ve/veya boyunda gözlenir. Yüzeyi yumuşak ve kırışıktır. Ayrıca, altındaki damarlar ve telenjektaziler gözlenebilir. Histopatolojik bulguları, epidermal atrofi, CD34+ iğsi hücrelerin dermal proliferasyonu ile karakterizedir. Bu zamana kadar İngilizce literatürlerde sadece 9 olgu bildirilmiştir. Bizim olgumuz daha önce bildirilen olgularla benzer özellik göstermekle birlikte diğer olgulardan daha büyük olması ve daha belirgin vasküler komponente sahip olmasıyla farklılık göstermektedir.

Anahtar Kelimeler

Madalyon Benzeri; Dermal Dendrositik Hamartom; Kutanöz Lezyon; Konjenital

Abstract

Medallion-like dermal dendrocyte hamartoma (MLDDH) is newly described, extremely rare congenital cutaneous lesion. The characteristic features of the lesion are asymptomatic, well circumscribed, red-brown, atrophic, medallion-shaped patch on the upper trunk and/or neck. Its surface is pliable and wrinkled. Also, underlying blood vessels and telangiectasias may be visible. Histopathological findings are characterized by epidermal atrophy and dermal proliferation of CD34+ spindle cells. Only, nine cases have been reported in English literature so far. Our case had similar features as previously reported cases. On the other hand, he differed from others with huge appearance and distinctive vascular component.

Keywords

Medallion Like; Dermal Dendrocyte Hamartoma; Atrophic Cutaneous Lesion; Congenital

DOI: 10.4328/JCAM.688 Received: 29.04.2011 Accepted: 17.05.2011 Publihed Online: 01.07.2013 J Clin Anal Med 2013;4(4):324-326
Corresponding Author: Mehmet Gamsızkan, Laboratory of Pathology, Ankara Military Hospital, Ankara, Türkiye.
Phone: +903123103535 Fax:903123114609 E-mail:drgamsiz@mynet.com

Introduction

Medallion-like dermal dendrocyte hamartoma (MLDDH) is a rare congenital cutaneous lesion. It was first was a newly described by Rodriguez-Jurado et al in 2004.[1] Clinically, it presents at birth as asymptomatic, well circumscribed, red-brown, atrophic, medallion-shaped patch on the upper trunk and/or neck. Characteristic of the lesion is pliable and wrinkled surface. Also, underlying blood vessels and telangiectasias may be visible.[2] Histopathological findings are characterized by epidermal atrophy and the presence of CD34+ spindle cell proliferation in the dermis.[1-4] Nine cases have been reported in English literature so far.[1-6] Our case had similar clinical and histopathological features as previously reported cases except for distinctive size and vascular component.

Case Report

A 20 year old male patient presented to our dermatology clinic with a cutaneous lesion on his back that had been present since at birth. The lesion enlarged slightly with the normal growth of his body. Underlying blood vessels was seen below the tapering skin. Personal and family history was insignificant. He did not declare history of any systemic complaints.

On his dermatological examination, the lesion was 19x17cm in diameter, well demarcated, round, medallion like, reddish-brown atrophic patch with a subtle wrinkled appearance. Superficial veins were seen clearly on its surface (Figure 1). Full blood count, routine laboratory investigations, sedimentation rate, CRP (C-reactive protein) were within normal limits. On his soft tissue ultrasonography, dilated veins were observed under the soft tissue. Normal bone structure was determined in his lumbosacral radiography.



Figure 1. Erthematous, well demarcated, a round, a medallion like, atrophic lesion on his lumbar region of the back

Two biopsy specimens were taken. One of them was form the atrophic area and the other was over the vascular component. Histopathologically, in the skin specimens with partial epidermal atrophy, existence of loosely arranged proliferating spindle cells without atypia or mitotic figures have been noticed in dermal areas, around the dermal appendages, vascular structures and peripheral nerves (Figure 2). No vessel proliferations except partial ectatic vascular structures have been observed. Loss of dermal appendages and interstitial inflammation were not seen. Immunohistochemically, spindle cells showed widespread and strong immunoreactivity against CD34, vimentin, and fascin antibodies. Factor XIIIa, S-100, CD1a and CD68 immunoexpression were negative (Figure 3-4-5).

Discussion

Before the description of MLDDH, a congenital dermal dendrocyte hamartoma with stubby hair has been described. In that case, the lesion was a pedunculated red nodule with stubby hair on the lumbar region of the back. Immunohistochemically,

Table 1. Clinical presentations' summary of our patient and other patients [1-5]

Cases	Sex	Age	Shape	Size of the lesion	Location of lesion
Case 1[1]	F	11 year-old	Triangular	10x7 cm	The supraclavicular area
Case 2[1]	F	10 year-old	A round	8x8 cm	The presternal area
Case 3[1]	F	7year –old	Oval	6x3 cm	The right lateral aspect of the neck
Case 4[5]	F	2 month-old	Oval	6x4 cm	The left scapular area
Case 5[2]	F	19 year-old	A round	4 cm	The right breast
Case 6[4]	M	36 year-old	Dumbbell	16 cm	The presternal area
Case 7[3]	F	18 month-old	A round	2 cm	The left supraclavicular area
Case 8[3]	M	14 month-old	A round	2,5 cm	The dorsum of the hand
Case 9[3]	F	8 year-old	A round	2,5x2 cm	The right thigh
Our case	M	20 year-old	A round	19x17 cm	The back of the trunk

Table 2. Immunohistochemical profile of our patient and other patients [1-5]

Cases	CD34	Vimentin	Fascin	Factor XIIIa	HLA DR	S-100	CD 1a	CD 68 PGM 1
Case 1[1]	+	+	+	+	Rare	-	-	-
Case 2[1]	+	+	+	+	±	-	-	-
Case 3[1]	+	+	±	+	Rare	-	-	-
Case 4[5]	+	+	+	+	ND	ND	ND	ND
Case 5[2]	+	ND	ND	ND	ND	-	ND	ND
Case 6[4]	+	ND	ND	ND	ND	-	ND	ND
Case 7[3]	+	ND	ND	+	ND	ND	ND	ND
Case 8[3]	+	ND	ND	+	ND	ND	ND	ND
Case 9[3]	+	ND	ND	+	ND	ND	ND	ND
Our case	+	+	+	ND	ND	-	-	-

ND Not determined

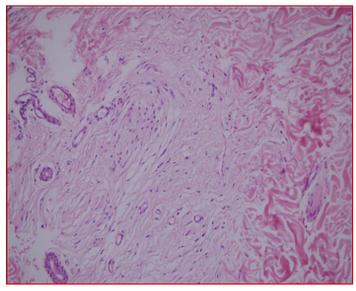

Figure 2. Spindle cells (left and middle side) without atypia or mitotic figures in dermal areas. Normal collagen bundles are at right side (HEX200).

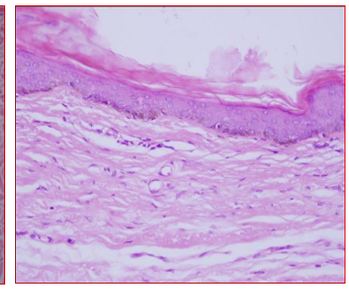

Figure 3. Epidermal atrophy (HEx100).

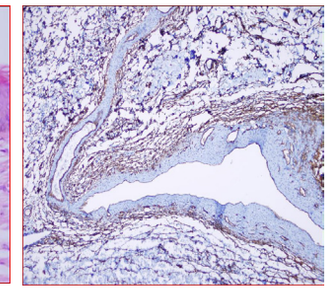

Figure 4. Spindle cells showed widespread and strong immunoreactivity against CD34 (x200).

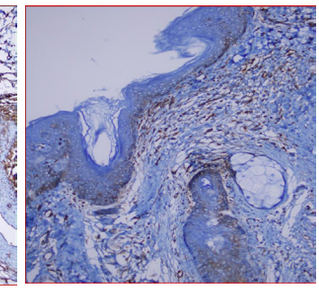

Figure 5: Fascin immunoexpression was positive in spindle cells (x200).

CD34 was positive in spindle cells. Factor XIIIa and S-100 was negative.[7] Then, Rodriguez-Jurado et al described MLDDH firstly as an atrophic lesion.[1] All previous reported cases were well-demarcated, round, triangular or oval erythematous and atrophic plaques of several centimeters in diameter.[1-5] Blood vessels and telangiectasias were seen below some of the lesions.[1,5] Summary of cases with their clinical presentations were shown in Table 1. In addition, Kutzner et al. has added new cases as plaque like CD34-positive dermal fibroma. However one case was nine years old in their series. The other cases were fifth and sixth decades. Interestingly, all lesions of their cases had been acquired over the past 2 to 7 years, whereas in the 9 years old boy the tumor had been present since birth.[6] Cases of Kutzner et al conflicted with congenital lesion definition. We did not show these cases in table 1 and 2.

In our case, the lesion size and blood vessels were distinctive. Dilated vessels were observed. Vascular component might be associated with the location of the lesion. On the atrophic surface, pressure with lying and sleeping may cause the dilatation of the veins. On the other hand, hamartoma is a benign focal malformation that resembles a neoplasm in the tissues of its origin and can be composed of tissue elements normally found that side.

Immunohistochemical profile of our case was similar with previous reports. Skin biopsy specimens of each nine patients included epidermal atrophy and presence of CD34 positive spindle cell proliferation in the dermis.[1-5] Immunohistochemical profile of the cases were shown in Table 2.

Before our case, two cases which were composed of CD34 positive and factor XIIIa negative. These cases were clinically indistinguishable from the MLDDH. Their ages were 19 and 36, respectively.[2,4] Our case was mainly similar to Ducharme's case (Case 6).[4] It is unclear whether this reflects loss of factor XIIIa with age or not. Besides, it is unknown if different dermal dendrocyte subtypes are capable of producing clinically similar lesions.[4]

Presumptive clinical diagnoses are dermatofibrosarcoma protuberans (DFSP), morphea, anetoderma, atrophoderma. MLDDH can be confused with DFSP, because both of them are positive for CD34.[3] It is a rare locally infiltrative malignant cutaneous dermal or subcutaneous tumor.[8] DFSP is composed of monomorphous population of spindle-shaped cells with a characteristic storiform or cartwheel pattern. There is mild nuclear atypia and variable number of mitosis. The deep border of the neoplasia has characteristic lace-like or stratified infiltration into subcutaneous adipose tissue.[9] In our case there was no cellular atypia and mitotic figure.[8]

Morphea is a connective tissue disorder that characterized histopathologically by a spectrum of changes culminating in expansion of the dermis with thickened collagen bundles. The inflammatory stage contains perivascular, interstitial and subcutaneous inflammatory infiltrate composed of lymphocytes, plasma cells and sometimes eosinophils amid subtly thickened collagen bundles.[10] The sclerosing stage is characterized by negligible inflammatory infiltrate with thick, sclerotic collagen bundles. Loss of skin appendages is observed. Also, immunohistochemical staining shows decreased CD34 positive dermal dendritic cells.[10] In our case, the loss of dermal appendages and interstitial inflammation were not seen. The clinical features of our case were different from anetoderma or atrofoderma. In the light of the clinical, histopathological and immunohistochemical findings; our case has been diagnosed as MLDDH accompanied by dilated vascular structures.

In conclusion; MLDD is a very rare congenital, benign disorder. Only clinical appearance is not enough to diagnose and immunohistochemical staining is essential. Herein we share this case to call to mind MLDD and to differentiate from the other similar lesions.

References

1. Rodríguez-Jurado R, Palacios C, Durán-McKinster C, Mercadillo P, Orozco-Covarrubias L, Saez-de-Ocariz Mdel M, et al. Medallion-like dermal dendrocyte hamartoma: a new clinically and histopathologically distinct lesion. J Am Acad Dermatol 2004;51(3):359-63.
2. Shah KN, Anderson E, Junkins-Hopkins J, James WD. Medallion-like dermal dendrocyte hamartoma. Pediatr Dermatol 2007;24(6):632-6.
3. Marque M, Bessis D, Pedeutour F, Viseux V, Guillot B, Fraitag-Spinner S. Medallion-like dermal dendrocyte hamartoma: the main diagnostic pitfall is congenital atrophic dermatofibrosarcoma. Br J Dermatol 2009;160(1):190-3.
4. Ducharme EE, Baribault KE, Husain S, Engler DE. Medallion-like dermal dendrocyte hamartoma in a 36-year-old male. J Am Acad Dermatol 2008;59(1):169-72.
5. Martín JM, Jordá E, Monteagudo C, Alonso V, Calduch L. Atrophic Congenital Lesion on the Back—Quiz Case. Arch Dermatol 2006;142(7):921.
6. Kutzner H, Mentzel T, Palmedo G, Hantschke M, Rütten A, Paredes BE, et al. Plaque-like CD34-positive Dermal Fibroma ("Medallion-like Dermal Dendrocyte Hamartoma"): Clinicopathologic, Immunohistochemical, and Molecular Analysis of 5 Cases Emphasizing its Distinction From Superficial, Plaque-like Dermatofibrosarcoma Protuberans. Am J Surg Pathol 2010;34(2):190-201.
7. Koizumi H, Kumakiri M, Yamanaka K, Tomizawa K, Endo M, Ohkawara A. Dermal dendrocyte hamartoma with stubby white hair: a novel connective tissue hamartoma of infancy. J Am Acad Dermatol 1995;32(2 Pt 2):318-21.
8. Feramisco J, Larsen F, Weitzul S, Cockerell C, Ghali F. Congenital atrophic dermatofibrosarcoma protuberans in a 7 month old boy treated with Mohs micrographic surgery. Pediatr Dermatol 2008;25(4):455-9.
9. Dominguez-Malagon H, Valdez-Carrillo Mdel C, Cano-Valdez AM. Dermatofibroma and dermatofibrosarcoma protuberans: a comparative ultrastructural study. Ultrastruct Pathol 2006;30(4):283-91.
10. Walters R, Pulitzer M, Kamino H. Elastic fiber pattern in scleroderma/morphea. J Cutan Pathol 2009;36(9):952-7.