A Rare Cause of Intestinal Obstruction: Partial Abdominal Cocoon

İntestinal Obstruksiyonun Nadir Bir Nedeni: Parsiyel Abdominal Koza

Parsiyel Abdominal Koza / Partial Abdominal Cocoon

Fuat Özkan[1], Mustafa Göksu[2], Nuri Özcan[1]
[1]Radyoloji AD, [2]Genel Cerrahi AD, Kahramanmaraş Sütçü İmam Üniversitesi, Tıp Fakültesi, Kahramanmaraş, Turkey

To the editor:

Intestinal obstruction can occur as the result of a different uncommon conditions [1]. Sclerosing encapsulating peritonitis (or abdominal cocoon) is a rare condition that results in an intestinal obstruction due to total or partial encapsulation of the small bowel by a fibrocollagenous membrane that looks like a cocoon [2]. We report a case of a patient who presented with a mild intestinal obstruction and showed typical computed tomography (CT) finding of an abdominal cocoon.

A 48-year-old man was admitted to our hospital with recurrent attacks of abdominal pain, bilious vomiting for one week and also had constipation. Patient has neither air-fluid level nor free intraperitoneal gas on the plain abdominal X-ray. Contrast-enhanced CT (CECT) of the abdomen showed clustered dilated small-bowel loops extending from the left upper quadrant to the right lower quadrant and encased within a thin membranelike sac. Coronal oblique-sagittal reformatted and axial maximum intensity projection (MIP) images displayed the thin membranelike sac better than normal raw images (Fig 1,2). But, there was no ascite or loculated fluid collection.

The patient underwent laparotomy. A fibrous capsule covering partially the small-bowel loops were detected (Fig 3). The capsule was resected, and adhesiolysis was performed.

Sclerosing encapsulating peritonitis (or abdominal cocoon) is characterized by recurrent acute or subacute intestinal obstruction. The patients generally have two distinct clinical presentations. Partial encasement involving distal segments of small intestines, uncommon type of abdominal cocoon, have more acute presentation with abdominal distension, because of dilatation of bowel proximal to encasement, as a prominent sign. On the other hand, palpable abdominal lump as a result of encasement of the whole edematous and matted small gut within the cocoon have been observed in the other clinical presentation [3]. Knotting and extrinsic compression of the small gut by the cocoon resulted in partial obstruction of the bowel and the symptoms in this group have less pronounced; there was absence of multiple air fluid levels in abdominal X-ray [3]. Although the plain X-ray abdomen was non-contributory in our case, the CECT abdomen provided the definitive diagnosis of abdominal cocoon by showing congregated small gut loops confined to a single area and encased in a thin membrane. Imaging is important for preoperative diagnosis. The characteristic findings of CT include those small-bowel loops congregated in a single area and encased by a soft-tissue density mantle and in some cases interbowel ascites [4].

Although, abdominal cocoon's being a rare condition, CECT is helpful in confirming the diagnosis, planning elective surgery and preventing unnecessary bowel resection in experienced hands. Careful dissection of the cocoon membrane from the gut to release the entrapped intestine and separation of the inter loop adhesions is the treatment of choice.

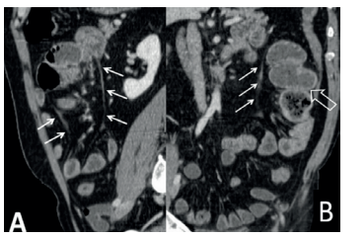

Figure 1. Sagittal (A) and coronal oblique reformatted images (B) showed clustered dilated small-bowel loops (open arrow) and thin membranelike sac (arrows).

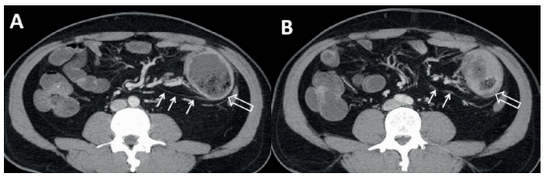

Figure 2. Axial images showed clustered dilated small-bowel loops (open arrow) and thin enhancing membrane (arrows) (A). Maximum Intensity Projection (MIP) images displayed the thin membranelike sac (arrows) better than normal axial raw images (B).



Figure 3. Intraoperative photograph: a fibrotic, cocoon-like membrane covering enteric loops.

References

1. Ozkan F, Goksu M, Yuksel M. Yaşlı Hastada Akut İntestinal Obstruksiyonun Nadir Bir Nedeni: İleoileal İnvajinasyon. JCAM. DOI: 10.4328/JCAM.795.
2. Tombak MC, Apaydin FD, Colak T, Duce MN, Balcı Y, Yazıcı M, et al. An unusual cause of intestinal obstruction: abdominal cocoon. AJR Am J Roentgenol 2010;194(2):W176-78.
3. Mohanty D, Jain BK, Agrawal J, Gupta A, Agrawal V. Abdominal cocoon: clinical presentation, diagnosis, and management. J Gastrointest Surg 2009;13(6):1160-2.
4. Xu P, Chen LH, Li YM. Idiopathic sclerosing encapsulating peritonitis (or abdominal cocoon): a report of 5 cases. World J Gastroenterol 2007;13(26): 3649-51.

DOI: 10.4328/JCAM.973 Received: 01.04.2012 Accepted: 16.04.2012 Printed: 01.07.2013 J Clin Anal Med 2013;4(4): 346
Corresponding Author: Fuat Özkan, Kahramanmaraş Sütçü İmam Üniversitesi, Tıp Fakültesi, Radyoloji AD, Yörükselim Mah. Hastane Cad. No: 32, Kahramanmaraş, Turkey.
GSM.: +905307775440 F.: +90 3442212371 E-Mail: drfozkan@yahoo.com