Adult Giant Hydonephrosis Secondary to Uretheral Obstruction: A Case Report and Review of the Literature

Üreteral Obstruksiyona Sekonder Erişkin Hidronefrozu: Olgu Sunumu ve Literatür Değerlendirmesi

Dev Hidronefroz / Giant Hidronephrosis

Cavit Ceylan, Metin Yığman, Öner Odabaş
Department of 3rd Urology, Türkiye Yüksek Ihtisas Training and Research Hospital, Ankara, Türkiye.

Özet

Dev hidronefroz vakaları, böbreğin toplayıcı sisteminin yaklaşık 2 litreye kadar idrarla dolu olabildiği nadir olgulardan biridir. Toplayıcı sistemde bu kadar fazla idrarla dolu olan dev hidronefroz, batında yer kaplayan kitle lezyonu olarak, ciddi semptomlara yol açar. Bununla birlikte, diğer batın içi yer işgal eden kistik kitlelerin ayırt edilmesi açısından önemlidir. Üreteral obtruksiyonlara bağlı olarak da gelişebilir. Biz, oldukça nadir görülen, üreteral obstrüksiyona bağlı olarak da gelişen ve toplayıcı kanallarda 4000 ml idrar ile dolu dev hidronefroz vakasını literatür bilgileri ışığında inceleyerek, bu konuda yapılacak olan çalışmalara katkıda bulunmak amacıyla sunduk.

Anahtar Kelimeler

Dev Hidronefroz; Erişkin; Nonfonksiyone Böbrek; Nefrektomi

Abstract

Giant hydronephrosis cases are extremely rare and usually contains 1-2 liters fluid in the collecting system of the kidney. Signs and symptoms are generally due to mass effect on the adjacent organs and it's important to discriminate these lesions from other intraabdominal cystic masses. The etiology can be also ureteral obstruction. Here, we report a rarely seen case with giant hydronephrosis due to ureteral obstruction which contains 4000 ml fluid in the collecting system of the kidney representing as an intraabdominal cystic mass.

Keywords

Giant Hydronephrosis; Adult; Non-Fonctional Kidney; Nephrectomy

DOI: 10.4328/JCAM.683 Received: 25.04.2011 Accepted: 24.05.2011 Publihed Online: 01.09.2013 J Clin Anal Med 2013;4(5):405-406
Corresponding Author: Cavit Ceylan, Department of 3rd Urology, Türkiye Yüksek Ihtisas Training and Research Hospital, Ankara, Türkiye.
Phone: +9005065421569 Phax: +9003123124120 E-mail: ceylancavit@yahoo.com

Introduction

Giant hydronephrosis, which is defined as the presence of more than 1 liters of fluid inside the collecting system, is a rare clinical entity.[1] Since these cystic masses develop slowly, they are mostly asymptomatic and abdominal mass is the most frequent finding in physical examination.[2] Giant hydronephrosis may compress adjacent structures such as contralateral ureter, intestine or veins. Moreover, infections, renal insufficiency, malignant change, rupture of the kidney and mechanical bowel obstruction are other reported complications of giant hydronephrosis.[3]

We report a case of giant hydronephrosis caused by an ureteral stone and suggest that, this rare condition must be considered in the differential diagnosis of intraabdominal or retroperitoneal cystic masses.

Case Report

A 63 year old male with the compliant of chronic abdominal pain and distention was admitted to our urology clinic. The patient also described fatigue, exertional dyspnea and some dyspeptic complaints. His medical history was unremarkable, except having a cardiac coronary stent implantation 18 year ago. The abdominal examination revealed a huge mass at left lumbal region which extends until midline. The serum analysis and complete blood count was performed and blood urea was 113mg/dl, creatinine was 2.38mg/dl, hemoglobin was 17.0g/dl and hematocrit was 51.4%. Results of urine analysis were normal. The levels of carcino-embriogenic antigen (CEA) was elevated (7.58ng/ml) but other tumour markers were normal.

Ultrasound revealed a grossly distended left pelvicalyxeal system which contained echogenic material inside and no signs of renal parenchyma were detected. Computed tomography (CT) scan of the abdomen revealed a huge cystic lobulated mass in the left kidney which occupied the left intraperitoneal and pelvic cavities. A 15x6mm ureteral stone was detected in the middle of the left ureter which caused the obstruction(Figure 1). No other abnormalities were found in the other organs examined with above mentioned imaging techniques.

The patient underwent nephrectomy and 25x15cm cystic mass, which contained approximately 4000 ml of liquid, was removed. The ureteral stone which caused obstruction in mid-ureter was also seen (Figure 2). The patient was discharged uneventfully at the 5th postoperative day.

Discussion

Although several giant hydronephrosis cases have been reported in the English literature, only a few of them contain more than 2 liters of fluid.[1-3] To our knowledge, the biggest giant hydronephrosis in adults was reported by Schrader et al.,[4] which was more than 15 kg and Yilmaz et al.[5] reported 13.5 liters of urine in the collecting system in a child.

Even though diagnostic instruments such as excretory, antegrade or retrograde urographies, ultrasonography, and CT scans have facilitated the diagnosis of hydronephrosis in the last decades, accurate diagnosis of giant hydronephrosis in individual cases remains challenging.[5,6] The patients with giant hydronephrosis may present with vague symptoms such as nausea, fatigue or dyspepsia, mimicking a malignant growth.[6] The list of differential diagnosis is wide and includes: ovarian cysts, retroperitoneal hematoma, hepatobiliary cysts, mesenteric and hepatobiliary cysts, pseudomyxoma, re¬nal tumour, retroperitoneal tumors, ascites and splenomegaly.[6]

Giant hydronephrosis can be treated with various surgical procedures such as pyeloplasty, nephrectomy, or percutaneous nephrostomy placement.[7] The patient reported underwent nephrectomy since there was no renal parenchyma detected with ultrasonography. However, especially in compromised patients, percutaneous drainage with a nephrostomy tube may be preferred in order to prevent hemodynamic problems due to the sudden removal of abdominal mass. Similarly, for patients with co-morbidities or solitary kidney, more conservative approaches such as observation or ureteral J stent placement may be considered. If renal parenchyma of the effected kidney is preserved reconstructive surgical procedures such as pyeloplasty, calycoureterostomy, calycocystostomy, and Boari flap calycovesicostomy can be treatment of choice.[7,8] Although there is limited data, laparoscopic approach can be a good alternative to open nephrectomy or pyeloplasty.[8] However, further studies are required to confirm the safety and efficacy of laparoscopy for giant hydronephrosis.

In conclusion, giant hydronephrosis is rare clinical entity which must be considered in patients with huge abdominal cystic masses. If the effected kidney is not functioning, simple nephrectomy may be the treatment of choice. Initial reports about laparoscopic procedures for giant hydronephrosis are promising, further studies are required to confirm their safety and efficacy.



Figure 1. The view of computed tomography scan shows right kidney inferior calyceal stone (Arrow 1), left ureteral stone (Arrow 2) and also the left giant hydronephrosis.

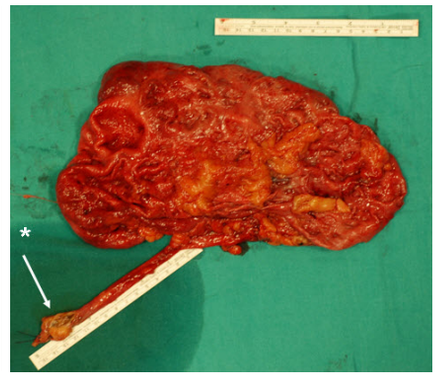

Figure 2. The view of the nephrectomy specimen.(* shows the ureteral stone)

References

1. Chiang PH, Chen MT, Chou YH, Chiang CP, Huang CH, Chien CH: Giant hydronephrosis: report of 4 cases with review of the literature. J Formos Med Assoc 1990; 89(9):811-17.
2. Wu CC, Sun GH.Giant hydronephrosis. Mayo Clin Proc. 2009 Nov;84(11):954.
3. Gschwend JE, Sauter TW, de Petriconi R, Hautmann RE: Renal pelvis rupture after blunt abdominal trauma. Urol Int 1995;55(2):108-10.
4. Schrader AJ, Anderer G, Von Knobloch R, Heiden¬reich A, Hofmann R. Giant hydronephrosis mim¬icking progressive malignancy. BMC Urol. 2003; October 18;3:4.
5. Yılmaz E, Guney S. Giant hydronephrosis due to ureteropelvic junction obstruction in a child. CT and MR appearances. Clin Imaging 2002; 26(2): 125-28.
6. Mountney J, Chapple CR, Johnson AG.Giant hydronephrosis-a diagnostic dilemma. Urol Int.1998; 61(2):121–23.
7. Mandal AK, Hemal AK, Vaidyanathan S. Boari flap calycovesicostomy: A salvage procedure for giant hydronephrosis due to ureteropelvic junction obstruction. J Postgrad Med 1990; 36(1): 38-40.
8. Mastoroudes H, Olsburgh J, Harding K, Dasgupta P. Retroperitoneoscopic nephrectomy for giant hydronephrosis in pregnancy. Nature Clinical Practice Urology 2007; 4(9): 512-15.