A Giant Lipoma Mimicking Malignancy at Thoracotomy Incision

Malign Hastalığı Taklit Eden Toraks İnsizyonu Yerleşimli Dev Lipom

Dev Lipom / Giant Lipom

Hüseyin Melek[1], Elif Torun[2], Mihriban Gürbüzel[3], Orçun Oral Şentürk[4], Mustafa Girgin[4]
[1]Göğüs Cerrahi Kliniği, [2]Göğüs Hastalıkları Kliniği, [3]Patoloji, [4]Genel Cerrahi Kliniği, Bingöl Devlet Hastanesi, Bingöl, Türkiye

2010 yılı Toraks Kongresinde Poster olarak sunulmuştur.

Özet

Lipomlar en sık görülen mezenkimal tümörlerdir. Genelde asemptomatik olup, nadiren dev boyutlara ulaşırlar ve birçok benign ve malign tümoral hastalık ile karışabilirler. Tedavide total cerrahi eksizyon yeterlidir [1-3]. Sağ torakotomi insizyonunda yaklaşık 15 cm boyutlarında, ağrılı, son bir yılda giderek büyüyen öncelikle malign tümörü düşündüren, eksizyon sonucu patolojik incelemede lipom tanısı konulan hastayı, lipomun nadiren dev boyutlara ulaşması nedeniyle fotografları ve literatür eşliğinde sunmak istedik.

Anahtar Kelimeler

Dev Lipom; Göğüs Duvarı Tümörü; Eksizyon

Abstract

Lipomas are most common mesenchymal tumors. They are generally asymptomatic and may rarely become giant masses. Differential diagnosis includes various malignant and benign tumors. Total surgical excision is the treatment of choice [1-3]. We present a case of giant lipoma of about 15 cm diameter located in the thoracotomy insicion.

Keywords

Giant Lipoma; Chest Wall Tumor; Surgical Teatment

DOI: 10.4328/JCAM.698 Received: 17.05.2011 Accepted: 17.07.2011 Printed: 01.09.2013 J Clin Anal Med 2013;4(5): 412-413
Corresponding Author: Hüseyin Melek, Uludağ Üniversitesi Tıp Fakültesi Göğüs Cerrahi Kliniği AD, Görükle, Bursa, Türkiye.
T.: +905052581772 E-Mail: hmelek@hotmail.com

Introduction

Lipomas are the most frequent benign mesenchymal soft tissue tumors. They may arise in any region containing adipose tissue [1-5]. Most occur between 30-70 years of life, with female predominance. They are most commonly located in the trunk, head and neck region [5]. They are usually asymptomatic, well-circumscribed, mobile masses. Macroscopically they are yellow to orange and encapsulated with a fine capsule [1,3,6]. Superficially located ones tend to be small, multiple and easily recognised. Deeply located lipomas are more rare, solitary and lobulated. Because of this asymptomatic presentation, early diagnosis is difficult and the growth period estimation by the patient is generally unreliable [5,7,8].

Case Report

A 30-year old male patient applied to our clinic with a painful mass lesion gradually growing over 1-year period at the site of right thoracotomy incision, performed a few years ago for empyema drainage. Physical examination revealed a 15x10 cm soft tissue lesion extending posterolaterally at right thoracotomy incision (Picture 1). Chest-X-ray was normal. Thoracic CT demonstrated a soft tissue lesion with no chest wall invasion. Fine needle aspiration biopsy was undiagnostic and patient underwent operation. Following re-thoracotomy incision, an encapsulated, smoothly margined mass of 15x10x8 cm size was extracted (Picture 2,3,4). The final histopathological diagnosis was lipoma. The patient was followed for about 1 year showing no complication or recurrence.

Discussion

Ethiopathogenesis of the lipomas is obscure, trauma, genetics and endocrine factors are generally to blame [9-11]. Microscopically, the cells resemble normal adipose cells, with slightly larger diameter [1,3]. The presence of a capsule differentiates lipomas from simple fat accumulation [12,13]. The term giant lipoma is used when the tumor is larger than 10 cm diameter in one dimension and weighs at least 1000 grams [14]. All lipomatous lesions, including giant lipomas should be diagnosed and treated [4,15,16]. The differential diagnosis of giant lipomas includes benign diseases such as epidermoid cyst, hemangioma, muscle tears, diffuse lipoblastomatosis, a well as malignant lesions such as malignant fibrous histiocytoma [4,17,18]. Liposarcomas represent the most frequent soft tissue sarcomas in adults. [2]. A fatty subcutaneous tumor exceeding a diameter of 10 cm and showing rapid growth in recent period should raise the suspicion of liposarcoma. [19,20]. Lipomas are homogeneous masses on CT and MRI views [21]. They have low density on ultrasonography and CT, unlike liposarcomas [22]. However clinical discrimination of lipomas and liposarcomas is nearly impossible. Even MRI and needle aspiration biopsy may be false negative for malignancy [23]. Giant lipomas have low probability of malignant transformation [8,24,25]. Surgical excision is the preferred treatment modality, generally because of functional or cosmetic reasons. Following surgical excision, recurrence is very rare and no additional treatment is necessary [3,6,26].

Our patient had a soft mass lesion larger than 10 cm on his thoracotomy insicion, which grew rapidly over the last year. Lipoma was thought to be the most probable diagnosis, however malignancy remained to be ruled out. Surgical excision revealed the histopathological diagnosis and postoperative follow-up yielded no complication or recurrence.

References

1. Robbins SL, Cotran Sr, Kumar V. Pathologic basis of disease, 15., W.B. Saunders Philadelphia, 1992;701.
2. Weiss SW. Lipomatous tumors. Monogr Pathol. 1996;38: 207-39.
3. Enzinger F, Weiss S. Benign lipomatous tumors. In: Enzinger F,Weiss S, eds. Soft Tissue Tumors, 3rd ed. St. Louis: CV Mosby, 1995:381–430.
4. Salvatore C, Antonio B, Del Vecchio W, Lanza A, Tartaro G, Giuseppe C. Giant infiltrating lipoma of the face: CT and MR imaging findings. Am J Neuroradiol. 2003;24: 283–288.
5. Kransdorf MJ. Benign soft-tissue tumors in a large referral population: distribution of specific diagnoses by age, sex, and location. AJR Am J Roentgenol 1995;164:395–402
6. Silistreli OK, Durmus EU, Ulusal BG, Oztan Y, Gorgu M. What should be the treatment modality in giant cutaneus lipomas? Review of the literature and report of 4 cases. Br J Plast Surg.2005: 394-8.
7. Montenegro JS, Fernandez CB, Ansio FG. Giant submuscular lipoma: clinical, diagnostic, and treatment aspects. Plast Reconstr Surg 1998;101:543–4.
8. Phalen GS, Kendrick JI, Rodriguez JM. Lipomas of the upper extremity: a series of fifteen tumors in the hand and wrist and six tumors causing nerve compression. Am J Surg 1971;121: 298–306.
9. Turc-Carel C, Dal Cin P, Boghosian L, Leong SP, Sandberg AA. Breakpoints in benign lipoma may be at 12q13 or 12q14. Cancer Genet Cytogenetic. 1988;36: 131-5.
10. Signorini M, Campiglio GL. Posttraumatic Lipomas: Where do really come from? Plastic and Recons Surg. 1998;101:699–705.
11. Meggitt BF, Wilson JN. The battered buttock syndrome: fatfractures: a report on a group of traumatic lipomata. Br J Surg 1972;59: 165–9.
12. Zhong LP, Zhao SF, Chen GF, Ping FY. Ultrasonographic appearance of lipoma in the oral and maxillofacial region. Oral Surg Oral Med Oral Pathol Oral Radiol Endod.2004;98: 738-40.
13. Rosai J. Ackerman's Surgical Pathology. 8 th ed, Mosby-Year Book, St Louis 1996; 815-857.
14. Sanchez MR, Golomb FM, Moy JA, Potozkin JR. Giant lipoma. Case report and review of the literature. Am J Acad Dermatol. 1993;28: 266-70.
15. Zografos GC, Kouerinis I, Kalliopi P, Karmen K, Evagelos M, Androulakis G. et al. Giant lipoma of the thigh in a patient with morbid obesity.Plast Reconstr Surg 2002;109:1467–8.
16. Kıyak M.V, Kopal C, Sayhan MB, Kavalcı C, Giant Lipoma: Journal of Academic Emergency Medicine Case Reports 2010;1: 28-30
17. Roger B, Delepine N, Laval-Jeantet M, Delepine G, Cabanis EA, Tobolski F. NMR examination of soft tissue tumors. J Radiol 1986;67: 367-76.
18. Harrington AC, Adnot J, Chesser RS. Infiltrating lipomas of the upper extremities. J Dermatol Surg Oncol 1990;16: 834-7.
19. Celik C, Karakousis CP, Moore R, Holyoke ED. Liposarcomas: prognosis and management. J Surg Oncol 1980;14: 245-9.
20. Deutsch AA, Bachar A, Reiss R. Hemipelvectomy for liposarcoma: an unusual case and course. Post Med J 1984;60: 70-2.
21. Tateishi U, Gladish GW, Kusumoto M, Hasegawa T, Yokoyama R, Tsuchiya R, Moriyama N. Chest wall tumors: radiologic findings and pathologic correlation: part 1. Benign tumors. Radiographics. 2003;236:1477-90.
22. Godwin J.D. Computed Tomography of the Chest. Philadelphia, Lippincott, 1984; 92.
23. Terzioglu A, Tuncali D, Yuksel A, Bingul F, Aslan G. Giant lipomas: a series of 12 consecutive cases and a giant liposarcoma of the thigh. Dermatol Surg. 2004;30: 463-7.
24. Martin HS. Massive lipoma of subcutaneous tissue of back: case report. JAMA 1928;90: 2013–5.
25. Takagi H, Kato K, Yamada E, Suchi T. Six recent liposarcomas including largest to date. J Surg Oncol 1984;26: 260–7.
26. Higgs PE, Young VL, Schuster R, Weeks PM. Giant lipomas of the hand and forearm. South Med J 1993;86: 887–90.



Figure 1. Soft tissue lesion located on thoracotomy incision

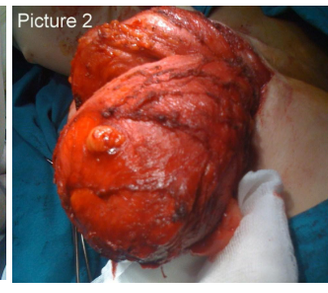





Figure 2-4. Intraoperative and postoperative photos showing the mass lesion