A Case of Chest Wall Tumor Confused with Pectus Carinatum

Pektus Karinatumla Karıştırılan Göğüs Duvarı Tümör Olgusu

Göğüs Duvarı Tümörü / Chest Wall Tumor

Erkan Akar, Tarık Candan
Bursa Şevket Yılmaz Eğitim ve Araştırma Hastanesi Göğüs Cerrahi Kliniği

Medical history of the 53-year-old male patient in whom enlargement and pain had begun in thorax for 4 months was featureless. On his physical examination, there was a significant enlargement in anterior thoracic region, pain in sternum and pectoral muscles. Biochemistry results, whole blood count and tumor markers were normal. Computed tomography of thorax (CT) performed in another institution was reported as normal and he was prescribed non-specific medications with diagnosis of pectus carinatum. The patient was admitted to our clinic as enlargement in thorax continued and his pain increased (Figure 1). On thorax CT, a mass lesion was observed on anterior chest wall (Figure 2). On positron emission tomography (PET), standardized uptake value (SUV) was measured as 37 in the mass measuring 15x6x13 cm, located in anterior thorax, destructed 4-5. ribs and invaded to bilateral pectoral structures and extended to intrathoracic region . There was malignant involvement in left axillary lymph node with 6.2 SUV (Figure 3). Biopsy result was reported as osteosarcoma.



Figure 1. Enlargement is observed in anterior thoracic region of the patient which was confused with pectus carinatum

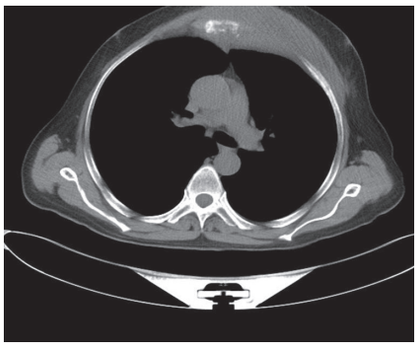

Figure 2. On computed tomography, tumoral formation which destructed sternum and ribs is seen

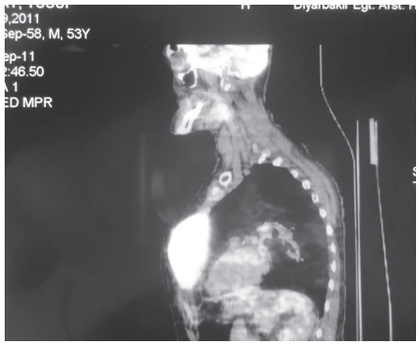

Figure 3. On PET, mass lesion which invaded sternum and ribs and showed intrathoracic extension is seen

DOI: 10.4328/JCAM.958 Received:21.03.2012 Accepted: 26.03.2012 Printed: 01.09.2013 J Clin Anal Med 2013;4(5): 435
Corresponding Author: Erkan Akar, Bursa Şevket Yılmaz Eğitim ve Araştırma Hastanesi Göğüs Cerrahi Kliniği Yıldırım, Bursa, Türkiye.
T.: +905052596901 F.: +90 2242955497 E-Mail: drerkanakar@hotmail.com