Evaluation of the Incidence and Etiological Distribution of Extraspinal Non-Traumatic Sciatica Using Computed Tomography and/or Magnetic Resonance Imaging

Bilgisayarlı Tomografi ve/veya Manyetik Rezonans Görüntüleri Kullanarak Travma Dışı Ekstraspinal Siyatikanın Sıklık ve Etiyolojik Dağılımının Değerlendirilmesi

Ekstraspinal Siyatikanın Etiyolojik Dağılımı / Etiological Distribution of Extraspinal Sciatica

Mehmet Sukru Sahin[1], Tarkan Ergun[2], Hatice Lakadamyalı[2], Gokhan Cakmak[1], Mehmet Fethi Ceylan[3]
Alanya Başkent Üniversitesi Uygulama ve Araştırma Hastanesi Ortopedi ve Travmatoloji Bölümü[1], Radyoloji Bölümü[2],
Yüzüncü Yıl Üniversitesi Ortopedi ve Travmatoloji Bölümü[3], Türkiye

Bu klinik çalışma Avrupa Radyoloji Kongresinde (1-5 Mart, 2012 Viyena, Avusturya) poster bildirisi olarak sunulmuştur.

Özet

Amaç: Bilgisayarlı tomografi (BT) ve manyetik rezonans görüntülemede (MRG) travma dışı ekstraspinal siyatika tespit edilen yirmi yedi vakayı sunmak ve travma dışı ekstraspinal siyatikanın sıklık ve etiyolojik dağılımını araştırmaktır. Gereç ve Yöntem: Siyatika şikayeti bulunan hastaların BT ve MRG tetkikleri retrospektif olarak değerlendirildi. Siyatikaya neden olabilecek patolojisi olan hastalar çalışma kapsamına alındı. Son tanı klinik bulgular, BT - MRG bulguları ve histopatolojik inceleme ile konuldu. İntraspinal (diskojenik, faset artropati, vb.) ve travmatik siyatika olguları çalışma dışı tutuldu. Bulgular : 27 hastada siyatik siniri etkileyen patoloji saptandı. Çalışmada 14 kadın 13 erkek hasta yer aldı. Ortalama yaşları 53 (17 - 91)'tü. En sık saptanan patoloji sakroileit (n = 9) idi. 7 olguda kötü huylu tümör, 3 olguda priformis sendromu, 5 olguda iyi huylu tümör, 1 olguda arteriyovenöz malformasyon, 1 olguda gluteal abse ve 1 olguda obturator arter anevrizması tespit edildi. Tartışma: Sakroileit ekstraspinal nontravmatik siyatikanın en sık nedenidir. Spinal bir patolojisi tespit edilmeyen hastalarda klinik bulgularla uyumlu olarak öncelikle sakroiliak eklem değerlendirilmelidir. Ancak diğer nadir görülen ekstraspinal patolojilerde akılda tutulmalıdır.

Anahtar Kelimeler

Siyatika; Ekstraspinal; Travma Dışı; Sakroileit

Abstract

Aim: To present 27 cases with non-traumatic extraspinal sciatica by means of computerized tomography (CT) and magnetic resonance imaging (MRI) and to investigate the frequency and etiological distribution of non-traumatic extraspinal sciatica. Material and Method: CT and MRI surveys of patients with sciatica complaints were evaluated retrospectively. Patients with pathology which might have caused sciatica were included in the study. Final diagnostic clinical findings were concluded with CT-MRI images and histopathological examination. Intraspinal (discogenic, facet arthropathy, etc.) and traumatic sciatica cases were excluded from the study. Results: Pathology affecting the sciatic nerve was detected in 27 patients. 14 of the patients were female, 13 were male; average age was 53 (18 - 91). The most frequent pathology was sacroiliitis (n = 9). It was detected that 7 cases had malignant tumor, 5 cases had benign tumor, 3 cases had piriformis syndrome, 1 case had arteriovenous malformation, 1 case had gluteal abscess, and 1 case had obturator artery aneurysm. Discussion: Sacroiliitis is the most frequent cause of extraspinal non-traumatic sciatica. In accordance with the clinical findings, primarily the sacroiliac joint should be assessed in patients without a spinal pathology. However, other rare extraspinal pathologies should also be kept in mind.

Keywords

Sciatica; Extraspinal; Non-Traumatic; Sacroiliitis

DOI: 10.4328/JCAM.1125 Received: 31.05.2012 Accepted: 08.07.2012 Printed: 01.11.2013 J Clin Anal Med 2013;4(6): 459-463
Corresponding Author: Tarkan Ergun, Radyoloji Bölümü, Alanya Uygulama ve Araştırma Hastanesi, Başkent Üniversitesi 07400 Alanya, Antalya, Türkiye.
T.: +902425112511 F.: +90 2425112350 E-Mail: tarkanergun@yahoo.com

Introduction

The term sciatica was first used in the 15th century in Florence as the foot pain originating from the ischium bone [1]. Lumbosacral plexus enables the nerve stimulation of pelvis and lower extremities. The sciatic nerve originates from L4, L5, S1, S2, and S3 nerve roots. It leaves the pelvis passing through the greater sciatic foramen, moves forward to femur and splits into the tibial and the common peroneal nerves in the lower one-third section of the femur [2].

Sciatica is the most common symptom encountered in neurosurgery practices and can be seen among the 40% of adults in any period of time during their lifetime [3].

It has been described as the pain in hip and lower extremities affecting the sciatic nerve and its branches along the intraspinal and extraspinal extension and developed after secondary pathologies [2,5]. The most significant cause of sciatica is a herniated lumbar disc which puts pressure on nerve roots or spinal stenosis. Imaging of the lumbar vertebral column reveals the causes of intraspinal non-discogenic sciatica but since the routine tests focus on the lumbar vertebra, extraspinal sciatica is frequently misdiagnosed [3]. The extraspinal causes of sciatic pain are overlooked for the most part because it is very rare and mostly intraspinal causes (herniated lumbar disc (HLD), lumbar spinal stenosis, facet joint osteoarthritis, fracture, tumors of the spinal cord and spinal canal) are considered. The mode of the pain and accompanying symptoms are the major factors determining the causes of extraspinal non-traumatic sciatica.

Although numerous diseases affecting the sciatic nerve have been characterized in a considerably successful way, the incidences of these are not entirely known. Besides, according to our literature review, there is no certain, accurate information on the etiological distribution of sciatica. For this reason, we systematically reviewed all cases without a history of trauma that had been examined using MRI and/or CT scan in our center between the years 2006 - 2011 in order to evaluate the sciatic nerve and to better understand the diseases which induce extraspinal sciatica.

The aim of this study is to present our analysis of twenty-seven patients with non-traumatic extraspinal sciatica and to investigate the frequency and the etiological distribution of extraspinal non-traumatic sciatica through the evaluation of magnetic resonance imaging and/or computed tomography scan findings.

Materials and methods

Between February 2006 and November 2011 a total of 3500 new patients were directed to our hospital for evaluation by a specialist in spinal diseases. Among these, 27 patients were diagnosed with extraspinal sciatica and lumbosacral plexus. Patients with common cause of intraspinal discogenic sciatica (discogenic, facet arthropathy, etc.) and spinal trauma were excluded from the study. The average age of the patients was 53 (between eighteen and ninety-one). 13 of them were male, and the remaining 14 were female.

We retrospectively reviewed the CT scan and/or MRI findings and clinical information of twenty-seven patients with an unexplained sciatic pain distribution who had been directed from a specialist orthopedist, a neurosurgery specialist, or a neurologist.

All of the 27 patients had pain or paresthesia symptoms along the dermatomal distribution and there were diagnosable motor defects in most of these patients. Patients with a history of trauma or whose imaging studies were not found to be suitable for evaluation were excluded from the study. All cases have been scanned (CT and/or MRI) at the same center with the same devices. All imaging studies were evaluated by a radiologist and an orthopedist and a consensus was reached in the event of incongruity. Available clinical follow-up information was also considered in determining the final diagnosis.

Examinations were performed using a 1-Tesla MRI device (Signa, GE Medical System, Milwaukee, WI, USA) and a 2-detector MDCT device (Siemens Sensation 4, Siemens, Erlangen, Germany).

Results

The causes of non-traumatic extraspinal sciatica are summarized in Table 1. Sacroiliitis was diagnosed in 9 of the 27 patients and it is the most frequent cause (33.3%) of sciatica in our study. Tumors constituted the second most frequent cause with 7 malign tumors (26%) and 5 benign tumors (%18.5) in the patients. Piriformis syndrome was the next common cause observed three patients (%11.1). The remaining 3 causes (%11.1) were found to be presacral abscess, internal iliac artery aneurysm, and arteriovenous malformation.

Table 1. Frequency of various causes of nontraumatic extraspinal sciatica

Diagnosis	Number of cases	Percentages
Sacroiliitis	9	33.3
Malignant tumors	7	26
Benign tumors	5	18.5
Piriformis syndromes	3	11.1
Presacral Abscess	1	3.7
Aneurism of internal iliac artery	1	3.7
Arteriovenous malformation	1	3.7
Total	27	100

Causes of Non-traumatic Extraspinal Sciatica

Sacroiliitis

Sacroiliitis, as one of the major causes of sciatica, must definitely be considered for those particularly with femoral back pain in the differential diagnosis of herniated lumbar disc [6]. The characteristics of patient's pain and history enable the determination of the diagnosis and etiology of sacroiliitis. The pain in sacroiliitis has an insidious onset, is commonly localized in the deep gluteal region and may refer to the posterior thigh. Pain decreases with activity, and increases later in the night [6]. Complaints of all 9 patients were treated with application of proper medical treatment combinations. Sciatica complaints were eliminated for all of the patients by the end of approximately three months. Intra-articular edema which imposes pressure on the sciatic nerve in sacroiliitis and joint is apparent in the sacroiliac MRI imaging of one of our patients (Figure 1). Symptoms of this patient were completely resolved after completion of the medical treatment.

Bone and Soft Tissue Tumors

Extraspinal entrapment of the sciatic nerve is infrequent and

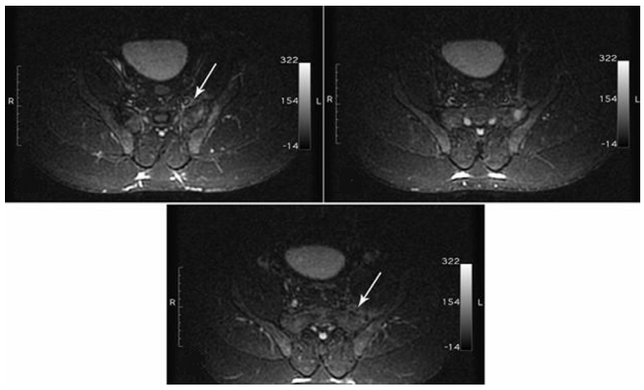

Figure1. Axial T2-weigthed fat suppression images reveal sacroiliitis of the left sacroiliac joint and neighboring edema pressing on the lumbosacral plexus (arrows).

difficult to diagnose because its symptoms are similar to more frequent causes of sciatica (i.e., herniated disc and spinal stenosis)[2]. Early diagnosis of the underlying pathology is very important because early resection plays an important role in the survival of the patient by ensuring the recovery of the symptoms and at the same time preventing unnecessary spinal surgeries. We determined 12 patients with sciatica associated with the compression of bone and soft tissue tumors along the extraspinal extent of the sciatic nerve in our study. Of these patients 7 were malign tumors and 5 were benign tumors. Tumors were extracted in the case of patients with benign tumor and complete cure was achieved whereas radiotherapy and chemotherapy were administered on patients with malign tumors in addition to the extraction of the tumor.

For example, in the MRI imaging of one of our patients, a malign soft tissue tumor was discovered as the cause of extraspinal sciatica by applying pressure on the sciatic nerve (Figure 2).

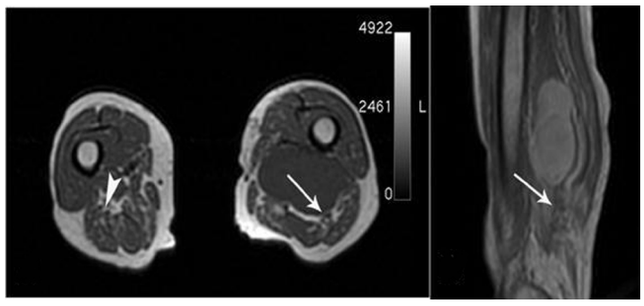

Figure2. Axial T1-weighted and sagittal T2-weighted images demonstrating a soft-tissue mass with in the posterior femoral compartment, the close relation of the mass to the sciatic nerve is seen (arrows). Normal sciatic nerve is seen in the posterior area of right thigh (arrow head).

Piriformis Syndrome

The incidence of PS is between 6% and 8% in patients with lower back pain [11]. Hypertrophy, inflammation, anatomic variations, myositis ossificans, and traumatic injuries of the piriformis muscle could cause pressure on the sciatic nerve [13, 14]. In most of the cases, this syndrome is associated with the hypertrophy of piriformis muscle due to recurrent injuries [14]. Patients with piriformis syndrome indicate very different symptoms such as buttock pain, sensitivity over the greater sciatic notch and increasing pain with movements which increase the tension on the piriformis muscle compared to those patients with discogenic sciatica [10,16]. One of these tests turns out positive, further tests such as MRI or CT scan can be performed. Physical treatment protocol was administered on three patients with piriformis syndrome. Satisfactory results were achieved without the need for any surgical intervention.

Piriformis asymmetry, bone marrow edema in the connecting area of hamstring muscle and high signal increase on the piriformis muscle level are apparent in the MRI imaging of one of our PS patients (Figure 3). Physiotherapy protocol was performed on the patients with PS [17]. Antalgic walking was arranged after the physiotherapy had ended. Freiberg's sign and FAIR test turned negative.

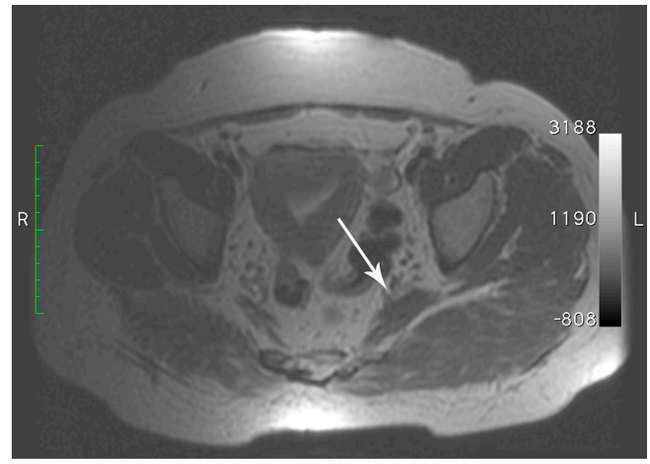

Figure 3. Axial T1-weigthed image reveals hypertrophy of the left piriformis muscle and enlarged muscle pressing on the sciatic nerve (arrow).

Presacral Abscess

Abscess is one of the rare causes of sciatica or lumbosacral plexopathy developed in the form of pain starting from the gluteal area and lower lumbar area and spanning over to hip and calf due to compression of the sciatic nerve [18]. Iliac veins, psoas, and iliac muscles are potential paths where abdominal infections spread to pelvis. In our case, the patient was admitted to our clinic for lower back pain and sciatica associated with a large presacral abscess which was caused by an osteomyelitis developed in the sacrum (Figure 4). The patient was diagnosed with presacral abscess via the pelvic MRI. Then the abscess was drained and treated with appropriate antibiotics. Pelvic abscesses which could be easily diagnosed by means of computed tomography or magnetic resonance imaging must be considered in patients with distinct pain originating from

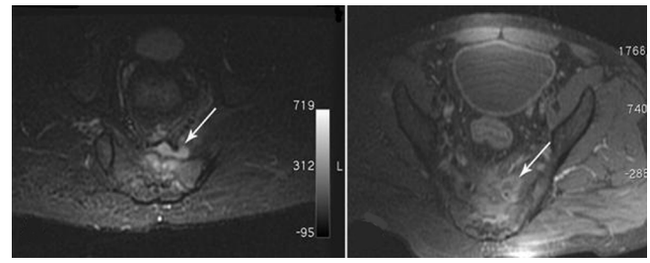

Figure 4. Axial T2-weighted fat-suppression image and T1 weighted fat-suppression image following intravenous Gd administration show a contrast-enhancing signal increase consistent with sacral osteomyelitis and associated presacral abscess. In addition, a presacral cystic mass pressing on the left lumbosacral plexus is seen (arrow).

passive hip movements and sciatica yet with no lumbar disc disease. Presacral abscess should also be considered in the differential diagnosis when low back pain and sciatica is accompanied by high fever.

Arteriovenous Malformation

Sciatica is a rather rare finding of arteriovenous malformation (AVM). AVM's are rare lesions that could develop on almost any part of the body; though extremities, head, and neck areas are more frequently affected. As the etiology may be congenital, it often develops subsequently [20]. In our case there was a large arteriovenous malformation and the performed computed tomography scan showed that the sciatic nerve was compressed between AVM and the sciatic notch (Figure 5). Patient's complaint was disappeared after surgical treatment of AVM.

Aneurysm of Internal Iliac Artery

Internal iliac artery plays a major role particularly in blood supply of lumbar and sacral plexuses via the iliolumbar, lateral sacral, superior, and inferior gluteal arterials [22].We are presenting a case with right internal iliac artery aneurysm which is a rare cause of sciatica. CT scan shows an internal iliac arterial aneurysm 3 cm in diameter that compresses the sciatic nerve. Patient was directed to vascular surgery service and operated. Aneurismal sac was repaired.

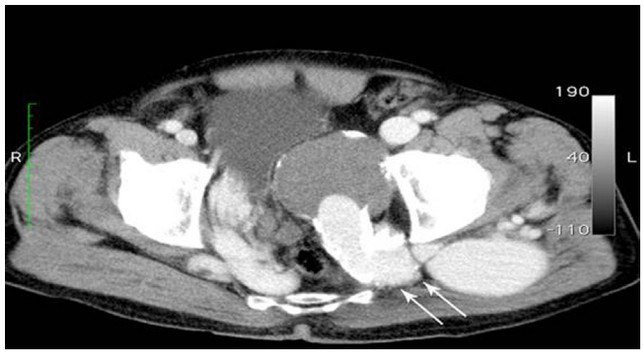

Figure 5. Axial CT image shows diffuse enlarged vascular collateral veins related to the arterio-venous malformation pressing on the left sciatic nerve at the level of great sciatic foramen (arrows).

Discussion

Evaluation of the causes of non-traumatic extraspinal sciatica presents very significant difficulties for clinicians and radiologists. Herniated lumbar disc is not the only cause of sciatica. Particularly, a detailed history focused on the characteristics of the pain is a substantial component of patient evaluation [6]. In an incoming patient admitted with sciatica complaints without any disc diseases, the evaluation should not be considered complete without performing a full scan of the sciatic nerve. The radiologist could make accurate decisions by means of being familiar with common and uncommon imaging of conditions that affect the sciatic nerve.

Identified causes of extraspinal non-traumatic sciatica may include tumors [2], sacroiliitis [6], iliac or gluteal artery aneurysms [24,25], anorectal abscesses [12], avulsion fractures of ischial tuberosity [8], endometrioma in the pelvic cavity [4], piriformis syndrome [1,6,10,11], and pseudomyxoma peritonei [7].Physical examination should include sacroiliac compression test, Gaenslen's test, and FABER (Flexion Abduction External Rotation) test. Positive FABER test may provide further information on pathology. The early clinical diagnosis of sacroiliitis may be difficult; therefore it must be diagnosed radiologically. Both the MRI and the CT scan are sensitive methods for imaging sacroiliitis [6].

Extraspinal compression of the sciatic nerve associated with a tumor is a rare cause of sciatica [2]. Sciatica causes which have been developed due to bone and soft tissue tumor compression along the sciatic nerve have been defined in the literature in the form of case reports [2]. We recommend performing MRI and/or CT imaging of the entire sciatic nerve in order to investigate bone and soft tissue tumors in patients suspected for extraspinal causes.

Piriformis syndrome (PS) has been documented for more than 70 years and now is considered as a well-known cause of sciatica [9,10]. In PS patients, unlike herniated lumbar disc, symptoms do not only consist of lateral (S1 radiculopathy) or medial (L5 radiculopathy) dermatomes; there is multiple dermatome involvement [6]. Straight leg raise test (SLR) is negative in piriformis syndrome unlike the herniated lumbar disc.]. FAIR (flexion, adduction and inner rotation of the hip) test assists the diagnosis of piriformis syndrome by performing pressure on the sciatic nerve [1l Special tests such as Pace's sign, Freiberg's sign, and deep palpation of the piriformis muscle are required during the differential diagnosis of the piriformis syndrome.

Presacral abscess is a rare musculoskeletal system complication of the Crohn's disease. Clinic manifestation is occasionally devious and a delay in diagnosis could increase morbidity [19]. Arteriovenous malformations must be considered for the differential diagnosis of unexplained sciatica. The diagnosis could easily be obtained by contrast-enhanced computed tomography [21]. Reports have been published indicating that sciatica or lumbosacral plexus disorders are developed secondarily to abdominal aortic aneurysm [23], internal iliac artery pseudoaneurysm [24], common iliac artery aneurysms [25], and right or left internal iliac arterial aneurysm [3,15].

Early diagnosis of rarely observed causes of sciatica not only relieves elongated pains but also minimizes the number of unnecessary operations on the vertebra. Moreover, this has a positive and strong effect on the lifespan of the patient.

In our study the most common cause of sciatica was sacroiliitis. Malign and benign tumors were the second most common causes. We recommend to remembering sacroiliitis in the first place for patients with suspicion of extraspinal causes. Therefore, it is very important for clinicians and radiologists to be familiar with the MRI and CT characteristics and the frequency of many benign and malign formations.

Competing interests

The authors declare that they have no competing interests.

References

1. Fishman LM, Dombi GW, Michaelsen C, Ringel S, Rozbruch J, Rosner B, et al. Piriformis Syndrome: diagnosis,treatment, and outcome-a 10-Year Study. Arch Phys Med Rehabil 2002;83(3):295-301.

2. Bickels C, Kahanovitz N, Rubert CK, Henshaw RM, Moss DP, Meller I, et al. Extraspinal bone and soft-tissue tumors as a cause of sciatica. Spine 1999;24(15):1611-6.

3. Dudeney S, O'Farrell D, Bouchier-Hayes D, Byrne J. Extraspinal causes of sci-

atica: a case report. Spine 1998; 23 (4): 494–6.
4. Takata K, Takahashi K. Cyclic Sciatica. Spine 1994(1);19:89-90.
5. Kleiner JB, Donaldson FW, Curd JG, Thorne RP Extraspinal causes of lumbosacral radiculopathy. Journal of bone and Joint Surgery 1991;73(6): 817-21.
6. Kulcu DG, Naderi S. Differential diagnosis of intraspinal and extraspinal non-discogenic sciatica. Journal of Clinical Neuroscience 2008;15(11):1246–52.
7. Lin HL, Chen JT, Liu YF, Cho DY. Sciatica caused by pseudomyxoma peritonei. J Chin Med Assoc 2009;72(1):39-41.
8. Dosani A, Giannoudis PV, Waseem M, Hinsche A, Simith MR. Unusual presentation of sciatica in a 14-year-old girl. Injury 2004;35(10):1071-2.
9. Synek VM. The priformis syndrome: review and case presentation. Clin Exp Neurol.1987;23: 31–7.
10. Hopayian K, Song F, Riera R, Sambandan S. The clinical features of the priformis syndrome: a systematic review. Eur Spine J 2010;19 (12):2095-109.
11. Lewis AM, Layzer R, Engstrom JW, Barbaro NM, Chin CT. Magnetic resonance neurography in extraspinal sciatica. Arch Neurol 2006; 63 (10):1469–72.
12. Herr OH, Williams JC: Supralevator anorectal abscess presenting as acute low back pain and sciatica. Ann Emerg Med January 1994;23 (1):132-5.
13. Parziale JR, Hudgins TH, Fishman LM.The PS. Am J Orthop.1996;25(12):819–23.
14. Ozaki S, Hamabe T, Muro T. Piriformis syndrome resulting from an anomalous relationship between the sciatic nerve and piriformis muscle. Orthopedics 1999;22 (8):771–2.
15. Graaff R, Biemans RG, Prevo RL, Koch PW. Sciatic nerve compression by an aneurysm of the internal iliac artery. Clin Neurol Neurosurg. 1985;87(3):219-22.
16. Filler AG, Haynes J, Jordan SE, Prager J, Villablanca JP, Farahani K, et al. Sciatica of nondisc origin and piriformis syndrome: Diagnosis by magnetic resonance neurography and interventional magnetic resonance imaging with outcome study of resulting treatment. J Neurosurg Spine 2005;2(2):99–115.
17. Fishman LM, Zybert PA. Electrophysiologic evidence of Piriformis syndrome. Arch Phys Med Rehabil. 1992; 73 (4): 359–64.
18. Shames JL, Fast A. Gluteal abscess causing sciatica in a patient with systemic lupus erythematosus. Arch Phys Med Rehabil. 1989;70(5):410-11
19. Aguilera V, Calvo F, Nos P, et al. Sciatica secondary to a presacral abscess as the first manifestation of Crohn's disease. Gastroenterol Hepatol. 2002;25(8):505-7.
20. Rosen RJ. and Riles TS. Arteriovenous malformations. In: Stradness, D.E., and Jr. and van Breda, A. (Eds.), Vascular Diseases Surgical & Interventional Therapy, Churchill Livingstone, New York, 1994. 1121-37.
21. Vos LD, Bom EP, Vroegindeweij D, Tielbeek. A V. Congenital pelvic arteriovenous malformation: a rare cause of sciatica. Clinical Neurology and Neurosurgery 1995;97 (3):229-32
22. Day MH. The blood supply of the lumbar and sacral plexuses in the human fetus. J Anat 1964;98(1):104–16
23. Wilberger JE. Lumbosacral radiculopathy secondary to abdominal aortic aneurysms. Report of three cases. J Neurosurg 1983;58(6):965–7
24. Melikoglu MA, Kocabas H, Sezer I, Akdag A, Gilgil E, Butun B.Internal iliac artery Pseudoaneurysm: an unusual cause of sciatica and lumbosacral plexopathy. Am Phys Med Rehabil. 2008;87 (8):681–3.
25. Gardiner MD, Mangwani J, Williams WW. Aneurysm of the common iliac artery presenting as a lumbosacral plexopathy. J Bone Joint Surg Br. 2006;88(11):1524-6