The Synergy of Medical and Surgical Treatment in Hydatid Cyst

Kist Hidatikte Tıbbi Tedavi ve Cerrahinin Sinerjik Etkisi

Kist Hidatikte Sinerjik Tedavi / The Synergic Treatment in Hydatid Cyst

Sezai Çubuk[1], Seyfettin Gümüş[2]
[1]Göğüs Cerrahisi AD., [2]Göğüs Hastalıkları AD. , GATA, Ankara, Turkey

A patient with a complicated hydatid cyst disease had admitted to our clinic. He had intact cysts in left upper and lower lobe with a perforated cyst in left lower lobe. Also he had infiltration spread over the entire left lower lobe(Figure 1). Before performing surgery, in order to cure perforated hydatid cyst and infiltration, 800 mg/day Albendazole and 1000 mg/ day Cefuroxime Axetil treatment had been administrated. Albendazole treatment was administrated with a 21- day cure and was extended to see the improvement with controlling liver enzymes. All the lesions that are in the previous CT had regressed in the control CT that is performed before surgery (Figure 2).

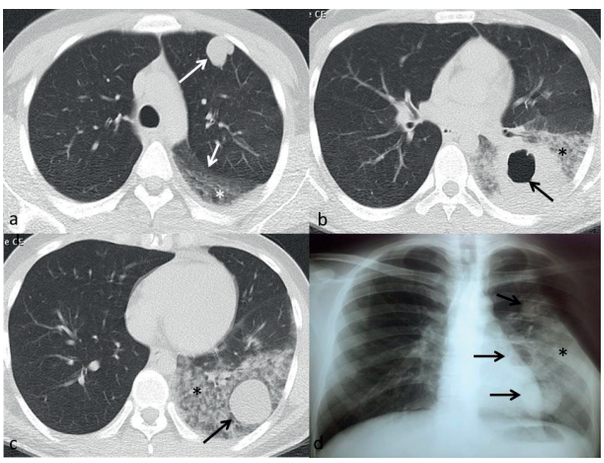

Figure 1. Lobulated intact cyst in left upper lobe (long arrow) and demarcation of the infection in lower lobe (short arrow)(A), Perforated cyst in the left lower lobe (arrow) (B), Intact cyst in the left lower lobe (arrow)(C), P\A graphy of the patient showing all the lesions (arrows). Asteriks represents infected lower lobe of left lung (D).

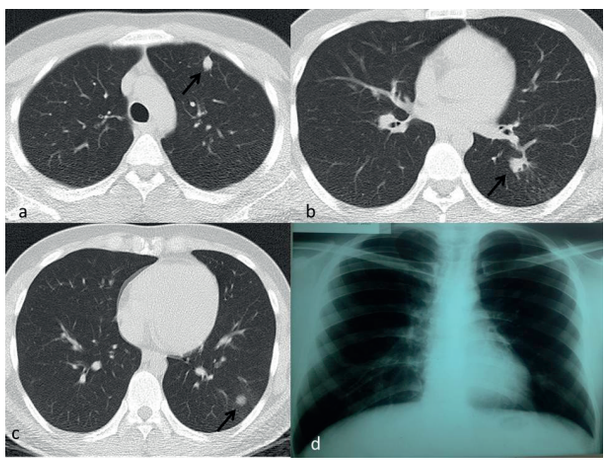

Figure 2. The effect of medical treatment, Shrinkage of intact cyst in left upper lobe (arrow)(A), Shrinkage of perforated cyst in left lower lobe (arrow) (B), Shrinkage of intact cyst in left lower lobe (arrow)(C), P\A graphy of the patient showing regression of the all lesions and cure of the inflamation (D).

DOI: 10.4328/JCAM.998 Received: 11.04.2012 Accepted: 18.04.2012 Printed: 01.11.2013 J Clin Anal Med 2013;4(6): 522
Corresponding Author: Sezai Çubuk, GATA Göğüs Cerrahisi AD, Ankara, Turkey.
T.: +90 3123045180 E-Mail: sezaicubuk@gmail.com