Leiomyoadenomatoid Tumor of the Epididymis

Epididim Yerleşimli Leiomyoadenomatoid Tümor

Leiomyoadenomatoid Tümor / Leiomyoadenomatoid Tumor

Tuba Canpolat[1], Filiz Bolat[1], Nazım Emrah Kocer[1], Tahsin Turunc[2]
[1]Department of Pathology, [2]Department of Urology,
Baskent University School of Medicine, Yuregir, Adana, Turkey

Bu olgu sunumu 19. Ulusal Patoloji Kongresi, 2009, Kıbrıs'ta yazılı poster olarak sunulmuştur.

Özet

Ebstein, leiomyoadenomatoid tümör tanımını, düz kas komponenti ön planda bulunan adenomatoid tümör için kullanmıştır. Adenomatoid tümör 3.-4. dekadda, çoğunlukla kadın ve erkek genital sisteminde bulunan, nadir, benign neoplazidir. Mikroskopik inceleme tübüler, kanaliküler pleksiform pattern de veya kistik dilate boşluklar şeklinde fibröz veya düz kas stromasına infiltrasyon gösteren vakuole, taşlı yüzük benzeri epitoloid görünümlü hücreleri gösterir. Birçok ultrastrüktürel ve immünohistokimyasal çalışma bu lezyonun mezotel hücrelerinden köken aldığını gösterir. Stromada düz kas varlığı genellikle uterustan köken alan adenomatoid tümörlerde bildirilmiştir. Biz burada, stroma içindeki düz kas dokusunun tümörün neoplastik bir komponenti olduğunu işaret eden, düz kas dokusundan fakir epididimde yerleşmiş bir adenomatoid tümör olgusunu sunacağız.

Anahtar Kelimeler

Leiomyoadenomatoid Tümor; Epididim

Abstract

Ebstein used leiomyoadenomatoid tumor description of a variant of adenomatoid tumor with a prominent smooth muscle component. Adenomatoid tumor is benign, rare neoplasm that may be found mostly in genital tract of women and men at 3rd - 4th decade. Microscopic examination reveals epitheloid appearance of vacuolated, signet-ring like cells, showing infiltrative distribution in fibrous or smooth muscle stroma in tubular, canalicular plexiform patterns or lining cystically dilated spaces. Most of the ultrastructural and immunohistochemical studies revealed mesotelial origin of this lesion. The presence of smooth muscle in stroma has been generally reported in adenomatoid tumors originated from uterus. Herein we report a case of an adenomatoid tumor located in epididimis which is poor of smooth muscle that indicates the smooth muscle tissue in the stroma is a neoplastic component of adenomatoid tumor.

Keywords

Leiomyoadenomatoid Tumor; Epididymis

DOI: 10.4328/JCAM.1909 Received: 22.05.2013 Accepted: 25.06.2013 Printed: 01.09.2013 J Clin Anal Med 2013;4(suppl 1): 18-20
Corresponding Author: Tuba Canpolat, Baskent University School of Medicine Department of Pathology, Dadaloglu Mh. 39. Sk. No:6 01250 Yuregir, Adana, Turkey.
T.: +90 3223272727-1157 F.: +90 3223271276 E-Mail: tuba.canpolat@yahoo.com.tr

Introduction

Leiomyoadenomatoid tumor was first described by Ebstein, in 1992. The term "leimyoadenomatoid" is indeed a descriptive name for the lesion, and reflects its histopathological appearance that is composed of prominent stromal smooth muscle proliferation accompanied by glandular structures [1]. Most of the ultrastructural and immunohistochemical studies indicate a mesothelial origin for the lesion . Adenomatoid tumors are benign, solitary lesions that occur mostly in genital tract of women and men at 3rd-4th decade [2]. Clinically, these lesions are usually found incidentally, and differential diagnosis of this rather rare lesion from malignant tumors which are more common in testicular region is crucial.

Case Report

A 76-year old man was admitted to urology outpatient clinic with swelling and pain in his right testis. In radiological evaluation of ultrasound showed 3.7x3.2 cm lobular mass, including echogenic areas on right testis cauda epididymis. The patient had a history of coronary by-pass surgery and was taking antihypertensive medication for 20 years. Laboratory analysis revealed ALK:126 IU/L, LDH: 179 IU/L, HCG: 1.2, PSA: 1.56 ng/ml. The patient underwent to right orchiectomy. Orchiectomy specimen was 94 g, and measured as 10.5x7.7 cm. The well circumscribed solid, firm, grayish white mass located between tunica albuginea and epididimis was 3.5x3x3 cm. Microscopically prominent fascicles of smooth muscle were infiltrated by cuboidal to flattened and vacuolated cells as well as tubular-glandular cystically dilated spaces (Figure 1,2). There was no mitoses, necrosis or pleomorphism. In immunohistochemical analysis the epithelial like cells were strongly positive for cytokeratin and calretinin (Figure 3a, 3b). Fascicles of prominent spindle cells were positive for smooth muscle actin (Figure 4). The lesions were diagnosed as leiomyoadenomatoid tumor.

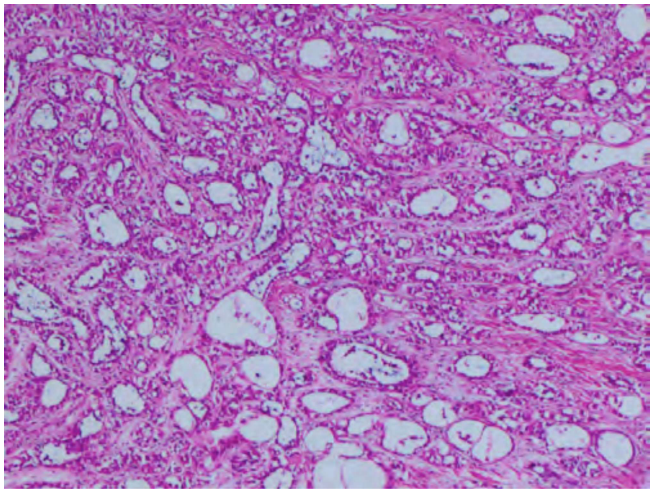

Figure 1. Adenomatoid component of leiomyoadenomatoid tumor composed of cystically dilated tubules and gland like structure (Hematoxylin –eosin X 100)

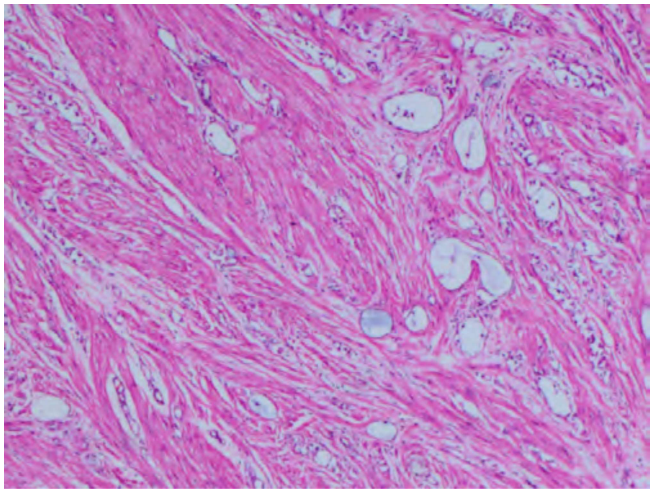

Figure 2. Smooth muscle components of leiomyoadenomatoid tumor (Hematoxylin –eosin X 100)

Discussion

Adenomatoid tumors are benign lesions located most frequently in paratesticular region, epididymis, spermatic cord and tunica albuginea in males and uterus, fallopian tubes and ovary in females. Besides genital region, pleura, lymph nodes and intestinal mesothelium localizations have been reported in both sexes [2,3,4]. Our case was localized in epididymis. Most of the adenomatoid tumors are well circumscribed, grayish white colored solid lesions, smaller than 3 cm in size, and include no hemorrhage or necrosis [5]. In our case, the lesion was also well circumscribed and 3.5x3x3 cm in dimension.

Histopathologically, leimyoadenomatoid tumors consist of mostly cuboidal cells with epitheloid appearance, sometimes accompanied by vacuolated, signet-ring like cells, showing infiltrative distribution in fibrous or smooth muscle stroma in tubular, canalicular plexiform patterns or lining cystically dilated spaces. Epithelial cells have small round-oval shaped nuclei, without prominent nucleoli and bright eosinophilic cytoplasm. Since the lesion may present with variable histopathologic patterns, differential diagnosis may be challenging. The presence of glandular pattern may mimic infiltrative epithelial and mesothelial lesions, while small-transparent cells with vacuolated

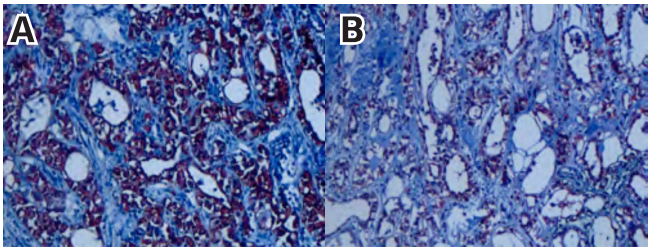

Figure 3. Immunohistochemical stains for cytokeratin are diffusely positive in tubules epitelium (A), Immunohistochemical stains for calretinin are diffusely positive in tubules epitelium (B)

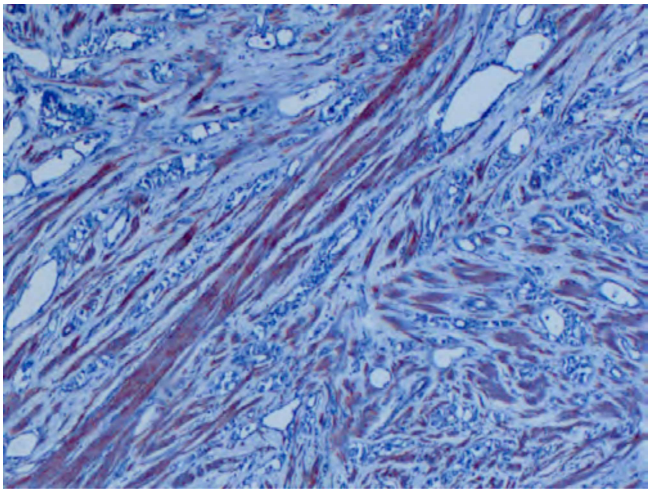

Figure 4. Immunohistochemical stains for smooth muscle actin positivity in spindle cell bundles (SMA X 200).

cytoplasm may resemble liposarcoma, and signet-ring like cells may resemble signet- ring adenocarcinoma. In ovary, Leydig cell adenocarcinoma should also be included in the differential diagnosis because of the presence of cells with large, eosinophilic cytoplasm [1-4].

The cases are generally clinically asymptomatic and usually found in radiological scans incidentally. Radiologic evaluations cannot distinguish other benign lesions like leiomyoma [6]. Most other lesions located in the testis have malignant nature; it is important to distinguish adenomatoid tumor of the testis from malignant lesions with frozen section during surgery while the therapy of adenomatoid tumor is enucleation of the mass only. In cases which proper differential diagnosis could not be made, overtreatment with orchiectomy may be performed.

Although Akhtar et al. has reported that inter glandular stroma in adenomatoid tumor may only be consist of smooth muscle tissue, stromas of most of the reported adenomatoid tumors are not rich of smooth muscle tissue [7]. Ebstein et al. has used the term 'leiomyoadenomatoid tumor' for adenomatoid tumors that has stroma with prominent smooth muscle tissue. Cases with leiomyoadenomatoid tumor reported in the English literature are rather few. Kausc et al. has reported a leiomyoadenomatoid tumor localized in epididymis [8]. It is not clear whether the presence of smooth muscle tissue is a component of the lesion or a marker of myometrial adjacency in adenomatoid tumors localized in uterus. On the other hand, prominent smooth muscle proliferations in the stroma of adenomatoid tumors localized in ovarian stroma, testis, and adrenal glands which are poor of smooth muscle tissue encourage the leiomyoadenomatoid tumor definition.

Although almost all of the studies indicate a mesothelial origin, histogenesis of adenomatoid tumors is still not clear. Immunohistochemically, the epithelial cells are positive for vimentin, cytokeratin, calretinin, HMBE-1 and negative for EMA and CEA [1-4]. Mesothelial cell origin is comprehensible for the adenomatoid tumors that are located in serosa-related organs. In locations which are not directly related with mesothelial lining, such as subserosal myometrium, adenomatoid tumors may be originated from mesothelial inclusions. Another theory in adenomatoid tumor histogenesis is that the lesion may be developed from mesenchymal tissues. This theory can explain the presence of smooth muscle, fibrous tissues and vascular structures as a component of tumor along with the glandular structures [8].

In conclusion, most of the studies endorse the mesothelial cell origin of adenomatoid tumors. In the literature, the presence of smooth muscle in stroma has been generally reported in adenomatoid tumors originated from uterus. As is seen in our case, prominent smooth muscle tissue in the stroma of adenomatoid tumors located in organs like testis and ovary, that are normally poor of smooth muscle tissue, indicates that the smooth muscle tissue is a neoplastic component of adenomatoid tumor. We want to emphasize that defining this benign lesion, which has no clinical, radiological or prognostic difference from adenomatoid tumors, as "leiomyoadenomatoid tumor", explains morphological features much more clearly.

Competing interests

The authors declare that they have no competing interests.

References

1. Ebstein JI. Urologic Disorders: Differential Diagnosis in Pathology. New York, NY: Igaku- Shoin; 1992:173-4.
2. Delahunt B, Eble JN, King D, et al. Immunohistochemical evidence for mesotelial origin of paratesticular adenomatoid tumor. Histopathology 2000;36(2):109-15.
3. Stephenson TJ, Mills PM.Adenomatoid tumors: an Immunohistochemical and ultrastructural appraisal of their histogenesis. J Pathol 1986;148: 327-35.
4. Nogales F.F, Isaac MA, Hardisson D, et al. Adenomatoid tumors of the uterus : an analysis of 60 cases. Int J Gynecol Pathol 2002; 21. 34-40.
5. Samad A.A, Pereiro B, Badiola A. Adenomatoid tumor of intratesticular localization. Eur Urol 1996;30: 127-8.
6. Amre R, Constantino J, Lu S, Charney D. Pathologic quiz case: a 52 year-old woman with a uterine mass. Arch Pathol Lab Med2005; 129:77-8.
7. Akhtar M, Reyes F, Young I. Elastogenezis in adenomatoid tumor histochemical and ultrastructurel observation. Cancer 1976;37;338-45.
8. Kausch I, Galle J, Buttner H, Bohle A, Jochan D. Leiomyo-Adenomatoid tumor of the epididymis. The Journal of Urology 2002;168:636.

How to cite this article:
Canpolat T, Bolat F, Kocer NE, Turunc T. Leiomyoadenomatoid Tumor of the Epididymis. J Clin Anal Med 2013;4(suppl 1): 18-20.