A Case of Periventricular Nodular Heterotopia with Late Onset Seizures

Geç Başlangıçlı Nöbetler ile Seyreden Periventriküler Nodüler Heterotopi Olgusu

Periventriküler Noduler Heterotopi / Periventricular Nodular Heterotopia

Mustafa Tansel Kendirli[1], Hakan Tekeli[1], Mehmet Güney Şenol[1], Semih Alay[2]
[1]Nöroloji Servisi, GATA Haydarpaşa Eğitim Hastanesi, İstanbul,
[2]Nöroloji AD, GATF, Ankara, Türkiye

48. Ulusal Nöroloji Kongresi'nde, (Antalya-2012) poster bildirisi olarak sunulmuştur.

Özet

Periventriküler noduler heterotopi, kendini genellikle 2 ve 3. dekadlarda başlayan epileptik nöbetler ile gösterebilen bir nöronal migrasyon anomalisidir. Hastaların birçoğu fiziksel ve mental olarak normaldir ancak bir kısmında hafiften ağıra değişebilen mental retardasyon, lisan bozuklukları ve kısa barsak sendromu gibi anormallikler mevcut olabilir. Biz, burada dördüncü dekadan sonra nöbet geçirmeye başlayan bir bilateral periventriküler heterotopi olgusunu sunduk ki bizim bilgimiz dâhilinde bu rahatsızlıkta bildirilmiş en geç nöbet başlangıç yaşıdır.

Anahtar Kelimeler

Nodüler Heterotopi; Periventriküler; Epilepsi; Migrasyon Bozuklukları; Nöronal

Abstract

Periventricular nodular heterotopia is a neuronal migration disorder that may manifest itself by epileptic seizures starting generally at 2nd and 3rd decades. Most patients appear mentally and physically normal, but some of them may have multiple findings, including short-gut syndrome, language disturbances, and mild to severe mental retardation. Here, we present a case with bilateral periventricular nodular heterotopias that starts to seize after fourth decade which in our knowledge, is the oldest age to experience the first seizure in this circumstances.

Keywords

Nodular Heterotopia; Periventricular; Epilepsy; Migration Disorder; Neuronal

DOI: 10.4328/JCAM.1934 Received: 05.06.2013 Accepted: 04.07.2013 Printed: 01.09.2013 J Clin Anal Med 2013;4(suppl 1): 24-6
Corresponding Author: Mustafa Tansel Kendirli, Nöroloji Servisi, GATA Haydarpaşa Eğitim Hastanesi, Üsküdar, İstanbul, Türkiye.
T.: +90 2165422020/3804 GSM: +905325887935 E-Mail: mtkendirli@hotmail.com

Introduction

Since the invention of imaging modalities, periventricular nodular heterotopia (PNH) has become one of the well known causes of epilepsy among other neuronal migration disorders (NMDs). Female preponderance, absence of major neurological or mental deficits, late-onset seizures usually in their twenties are some of the clinical characteristics in patients with PNH which are previously reported [1,2]. Although the nodular masses themselves may be the origin of epileptogenic discharges, some of the patients may have other structural abnormalities (cortical dysplasia, thin corpus callosum, hippocampal sclerosis, etc.) and these can cause epilepsy as well [3]. Both focal and generalized seizures can be observed. Seizures, particularly focal ones, are generally resistant to treatment [1].

We wish to present a patient who has bilateral PNH and easily controlled rare nocturnal seizures starting at age 41.

Case Report

A 51-year-old right handed woman with a feel like to have a seizure last night while sleeping was admitted to our policlinic for evaluation. She had another seizure almost ten years ago when she was 41. An eyewitness described her to this first episode as uncontrollable body shaking while she was sleeping and lasting nearly a minute. After the seizure she looked confused and felt asleep. On the morning of that night she had a dull headache and fatigue which is the same feelings she has today that brings her to our hospital. In her first episode some electroencephalography (EEG) abnormalities like mild background slowing with focal teta activities have been found. She told that she diagnosed with epilepsy after the first episode although she experienced only one attack and used carbamazepine (CBZ) 400 mg/daily up to three years without any recurrence and then gradually stopped. In her past medical history there was breast cancer with bilateral prophylactic mastectomy. There weren't a history of epilepsy in her family.

A general medical examination revealed nothing abnormal. At her neurological examination, she was alert, oriented with a mini-mental score of 30/30. There was no evidence of language disturbances. All cranial nerve functions were normal. Muscles were normal tone and strengths 5/5 throughout. There were neither reflex nor sensory abnormalities. Coordination and fine motor abilities were also normal. Her gait demonstrated a normal base and arm swing. All laboratory tests including complete blood count, chemistry panel and urinalysis were in normal ranges. Although EEG showing some subtle EEG abnormalities (Figure-1) which are nonspecific, the magnetic resonance imaging (MRI) scan supported the diagnosis of bilateral PNH (Figure-2)

She was living alone and has concern of to experience another seizure. Therefore we began treatment with CBZ (400 mg/day) which is previously well tolerated and has an effect to prevent seizures. She has been seizure free without any intolerable adverse events for eight months.

Discussion

PNH (also known as subependymal nodular hetrotopia) is a malformation due to abnormal neuronal migration. It characterized by the presence of round clusters of neurons that line the

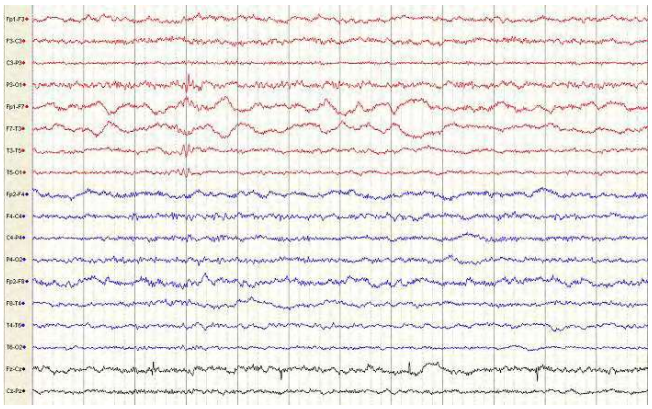

Figure 1. EEG of the patient demonstrates few spike like discharges on the left posterior temporal region with a generalized low amplitude background activity.

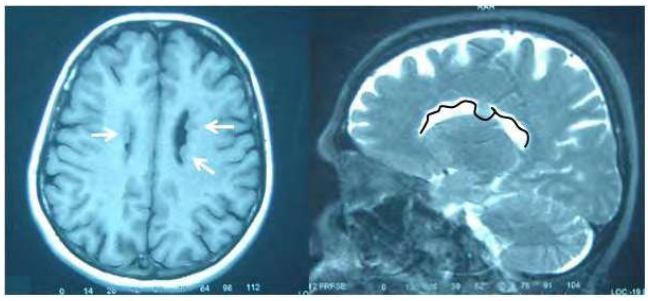

Figure 2. (A) Axial T1-weighted and (B) Sagittal T2-weighted images showing bilateral periventricular nodular heterotopias (white arrows) and the wavy form of the superior wall of the lateral ventricles (black line) with mild cortical atrophy.

walls of the lateral ventricles bilaterally or unilaterally, instead of properly migrating to the cortex [2,3,]. The prevalences of nodular heterotopia in the general population and in patients with epilepsy are unknown. In a large series of adult epileptic patients, about 2% had nodular heterotopias [4]. The pathogenesis of NMDs is multi-factorial. Genetic mutations as well as environmental factors (e.g. toxic agents, irradiation, viral infection) may all contribute to the development of these syndromes. So far, X-linked dominant mutations in FLNA (Filamin A or FLN1) and autosomal recessive mutations in ARFGEF2 (ADP-ribosylation factor guanine exchange factor 2) have been shown that are associated with PNH [5].

In clinical practice, to diagnosis the cause of the epilepsy is very important for further prognostic and therapeutic considerations. Less than half of all newly diagnosed cases of epilepsy have a known structural or metabolic cause and among them, the predominant known causes are stroke, neurodegenerative diseases such as dementia and multiple sclerosis and brain tumors [6]. World Health Organization (WHO) also reports that in developing countries, common causes of epilepsy are trauma, infections, brain tumors, alcohol, vascular diseases, metabolic and neurodegenerative disorders between the ages of 20 to 60 [7]. Although NMDs and particularly PNH are rarely seen as a reason of epilepsy in adult ages, high resolution imaging techniques dramatically improved our recognition of them. For these and other structural reasons, MRI is obligatory in all epilepsies starting at adulthood as a current concept.

In the diagnosis of epilepsy it is generally accepted that the patient must have repeated seizures without massive provocation due to abnormal electrical discharges in the neurons. The neuron clusters in PNH are capable of generating their own epileptic activity. But functional imaging studies suggest that

seizures were generated by the overlying cortex but not the heterotopias. Nonetheless, EEG can often help to demonstrate anatomic localization of PNH. Multifocal or posterior epileptiform activities as well as diffuse fast activities superimposed on focal multiple spike discharges may have been seen in bilateral or even in the unilateral patients. During slow-wave sleep, diffuse bursts of polyspikes were also reported [1,3].

The rationale for starting treatment is to have a reduced risk of seizure recurrence and better quality of life compared to no treatment. Overall seizure recurrence risk following a first seizure was found as 46% [8]. Regression analysis showed that there are some factors contributing to seizure recurrence. According to these results; low risk patients were those with a single seizure, no neurological deficit, and a normal EEG. Medium-risk was seen in those with either 2-3 seizures or neurological signs or an abnormal EEG. All patients who had more seizures or more than one additional factor belonged to the high-risk group [8]. Current evidence and consensus suggest that treatment should be started following a single seizure if the patient is in the medium or high recurrence risk group and the patient wishes to start it.

In conclusion, this case has taught us epileptic seizures starting at adult ages may be due to congenital malformations. Therefore, we have to evaluate every detail carefully.

Competing interests

The authors declare that they have no competing interests.

References

1. Battaglia G, Tiziana G, Farina L, D'Incerti L, Franceschetti S, Avanzini G. Periventricular nodular heterotopia: Epileptogenic findings. Epilepsia 1997;38(11): 1173-1182.

2. Raymond AA, Fish DR, Stevens JM, Sisodiya SM, Alsanjari N, Shorvon SD. Subependymal heterotopias: A distinct neuronal migration disorder associated with epilepsy. Journal of Neurology, Neurosurgery and Psychiatry 1994;57:1195-1202.

3. Acar G, Acar F, Öztura I, Baklan B. A case report of surgically treated drug resistant epilepsy associated with subependymal nodular heterotopia. Seizure 2012;21(3): 223-226.

4. Tassi L, Colombo N, Cossu M, Mai R, Francione S, Lo Russo G, Galli C, Bramerio M, Battaglia G, Garbelli R, Meroni A, Spreafico R. Electroclinical, MRI and neuropathological study of 10 patients with nodular heterotopia, with surgical outcomes. Brain. 2005;128(2):321-337.

5. Chevassus-au-Louis N, Represa A. The right neuron at the wrong place: biology of heterotopic neurons in cortical neuronal migration disorders, with special reference to associated pathologies. Cellular and Molecular Life Sciences 1999;55(10):1206-1215.

6. Hauser WA, Annegers JF, Kurland LT. Incidence of Epilepsy and Unprovoked Seizures in Rochester, Minnesota: 1935–1984. Epilepsia 1993;34(3):453-8.

7. Report, WHO/AFRO. Epilepsy in Africa: Bridging the gap. The global campaign against epilepsy "Out of Shadows". 2004

8. Schmidt D, Beyenburg S. Starting, choosing, monitoring and stopping AEDs in epilepsy. Evidence-based Management of Epilepsy. Ed: Steven C. Schachter. Tfm publishing Limited, UK, 2011;p:1-20.

How to cite this article:

Kendirli MT, Tekeli H, Şenol MG, Alay S. A Case of Periventricular Nodular Heterotopia with Late Onset Seizures. J Clin Anal Med 2013;4(suppl 1): 24-6.