An Unusual Case of a Giant Left Ventricular Pseudoaneurysm

Nadir Bir Dev Sol Ventrikül Yalancı Anevrizma Olgusu

Dev Sol Ventrikül Yalancı Anevrizması / Giant Left Ventricular Pseudoaneurysm

Özgül Uçar Elalmış[1], İlker Şahin[2], Selçuk Kanat[1], Havva Tuğba Gürsoy[1], Ahmet Karagöz[3]
[1]Ankara Numune Education and Research Hospital, Department of Cardiology, Ankara, [2]Çankırı State Hospital, Cardiology Clinic, Çankırı,
[3]Giresun Prof. Dr. A. Ilhan Ozdemir State Hospital, Cardiology Clinic, Giresun, Turkey

Özet

Sol ventrikül yalancı anevrizması miyokard infarktüsünün geç komplikasyonlarından biridir. Ayrıca kardiyovasküler cerrahi, travma ve nadiren de infektif endokardit ile ilişkili olabilir. Dev boyutta bir sol ventrikül yalancı anevrizması ise oldukça nadirdir. Bu yazıda, kalp yetersizliği belirtileri ile başvuran, muhtemelen sessiz miyokard infarktüsünü takiben gelişmiş dev boyutta sol ventrikül yalancı anevrizması saptanan bir hasta tartışılacaktır. Ne yazık ki, tanısal çalışmalar devam ederken hastada kalp rüptürü ve tamponad gelişmiştir. Hastaya acilen cerrahi anevrizma ve mitral kapak onarımı yapılsa da, cerrahi sonrası genel durumu düzelmemiştir. Biz, bu olguya dayanarak semptomatik dev sol ventrikül yalancı anevrizmalarında tanı konduğunda zaman kaybetmeden cerrahi yapılmasını öneriyoruz.

Anahtar Kelimeler

Sol Ventrikül; Yalancı Anevrizma; Miyokard İnfarktüsü; Kalp Yetersizliği; Ekokardiyografi

Abstract

Left ventricular pseudoaneurysm is one of the late mechanical complications of myocardial infarction, which also can be associated with cardiothoracic surgery, trauma, and, rarely, infective endocarditis. A giant pseudoaneurysm is a rare presentation. We report a patient with a giant left ventricular pseudoaneurysm probably following a silent myocardial infarction, who presented with congestive heart failure symptoms. Unfortunately, cardiac rupture and tamponade developed during diagnostic studies. The patient had surgical repair of the aneurysm and the mitral valve, but could not recover fully after surgery. We suggest urgent surgery whenever a giant left venricular pseudoaneurysm is diagnosed.

Keywords

Left Ventricle; Pseudoaneurysm; Myocardial Infarction; Heart Failure; Echocardiography

DOI: 10.4328/JCAM.1999 Received: 01.08.2013 Accepted: 31.08.2013 Printed: 01.09.2013 J Clin Anal Med 2013;4(suppl 1): 64-6
Corresponding Author: Ahmet Karagöz, Giresun Professor Doctor Atilla Ilhan Ozdemir State Hospital, Department of Cardiology, Ataturk Street No:323, Giresun, Turkey. T.: +90 4543102000 F.: +90 4542155146 GSM: +905052518702 E-Mail: drahmetkgz@hotmail.com

Introduction

Left ventricle (LV) pseudoaneurysm is a late mechanical complication of myocardial infarction (MI), which can develop within a few days or even much later (2 years). It can also be associated with cardiothoracic surgery, trauma, and, rarely, infective endocarditis [1]. A giant LV pseudoaneurysm is a rare presentation. We report a patient with a giant LV pseudoaneurysm probably following a silent myocardial infarction, who presented with congestive heart failure symptoms. The patient had surgical repair of the aneurysm and the mitral valve.

Case Report

A 57-year-old man presented to emergency department with dyspne and congestive heart failure symptoms. He had no hypertension, hyperlipidemia or diabetes mellitus. He was not aware of any cardiovascular disease. He had no history of chest trauma. On electrocardiogram, the rhythm was sinus and there were Q waves and T negativity in lateral derivations [Figure 1].



Figure 1. The 12-lead electrocardiogram of the patient.

Cardiothoracic ratio was increased on chest X-ray. His vitals were stable. On physical examination, a pansystolic murmur could be heard at the cardiac apex and there were fine rales in pulmonary auscultation. The admission blood tests were as follows: Blood fasting glucose: 134 mg/dl (70-109), blood urea: 55 mg/dl (10-50), creatinin 1.24 mg/dl (0.7-1.2), total cholesterol:136 mg/dl (N<200), LDL-C: 76 mg/dl (<100), HDL: 51 mg/dl (35-55), CK-MB: 30 U/L (7-25), ALT: 11 U/L (<50), LDH: 499 U/L (240-480), hemoglobin A1c: 6.7 % (4-6) and troponin I: 0.186 ng/ml (N: 0-0.15). CK-MB or troponin I levels showed no elevation during follow-up. Transthoracic echocardiogram showed a giant pseudoaneurysm involving the posterior, inferior, lateral and apical walls of the left ventricle with depressed systolic functions (Left ventricular ejection fraction 35%) [Figure 2]. There was severe mitral regurgitation. The diameter of aorta, which can be suggestive about a long previous history of cardiovascular disease, was within normal limits. A layer of organized thrombus lined the aneurysm sac. Antiaggregant, antithrombotic therapy with beta-blocker and angiotensin-converting-enzyme inhibitor were started. Multidetector computerized tomography (MDCT) confirmed a pseudoaneurysm with the size of 90*68*96 mm, communicating with the left ventricular cavity [Figure 3]. Coronary angiography revealed a muscular bridge on

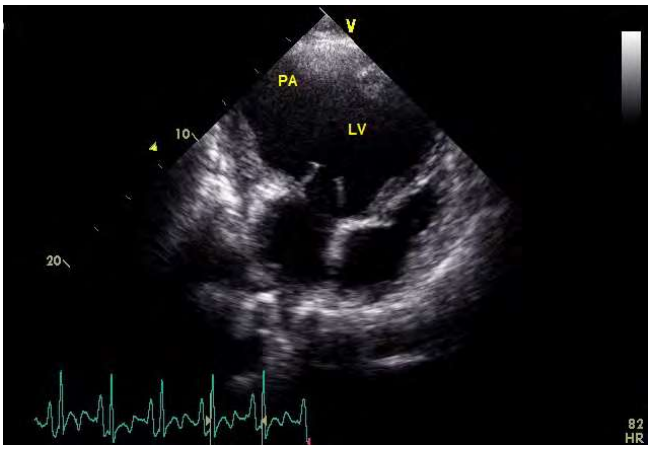

Figure 2. Apical 4-chamber view on transthoracic echocardiogram reveals a giant pseudoaneurysm (PA) in the left ventricular (LV) cavity extending from lateral wall to apex.



Figure 3. Multiplanar reformatted image of the giant pseudoaneurysm on cardiac multidetector computerized tomography.

the left anterior descending artery (LAD) and total stenosis of the circumflex artery after the first obtus marginal branch. On the third day of hospitalization, the patient became hypotensive and emergent echocardiography revealed echodense pericardial effusion surrounding the heart chambers. Intraaortic baloon counterpulsation was inserted and pericardiocentesis was performed. The patient underwent emergent cardiac surgery. The aneurysmal sac was repaired by plication and mitral valve was repaired by a ring annuloplasty. The patient weaned-off from the bypass pump gradually, but he stayed unconscious and maintained on mechanical ventilation. A cranial computerized tomography showed multiple ischemic areas. After three months he is still followed in the reanimation clinic with tracheostomy and support therapy.

Discussion

We presented a case of giant pseudoaneurysm probably after silent myocardial infarction. He was admitted with symptoms of heart failure and the pseudoaneurysm was diagnosed during routine echocardiography. LV pseudoaneurysms form when cardiac rupture is contained by adherent pericardium or scar tissue. The main causes of pseudoaneurysm formation are as follows: LV free wall rupture in the course of myocardial infarction (55%), after cardiac surgery (33%), chest trauma (7%), infective

endocarditis sequele (5%) and rarely due to purulan pericarditis, infiltrating heart tumor or Behcet's disease [1]. In the index case, electrocardiographic and echocardiographic findings together with exclusion of other causes suggested that the giant pseudoaneurysm had developed after a silent myocardial infarction. In a recent study, the prevalence of silent myocardial infarction was 23.3% and diabetes mellitus was an independent predictor for the presence of silent myocardial infarction [2]. Our patient had no history of diabetes mellitus, but blood tests during hospitalization suggested the presence of this clinical condition. Patients with a pseudoaneurysm usually present with anginal chest pain, heart failure symptoms, ventricular arrhythmias, thromboembolic complications, hypotension or syncope. However 10% of patients can be asymptomatic. In a series of 52 patients with pseudoaneurysms, 48% were diagnosed incidentally [3]. Physical examination may reveal a murmur in 70% of patients [1]. Our patient also presented with heart failure symptoms and had a pansystolic murmur due to mitral regurgitation.

Echocardiography is the first-line diagnostic tool. Pseudoaneurysms are usually round or saccular in shape. The most prominent feature is presence of a myocardial tissue defect. True aneurysms have a wide connection with left ventricular cavity. An orifice dimension over the cavity dimension smaller than 0.5 suggests pseudoaneurysm, whereas a value above 0.9 suggests a true aneurysm [4]. Additional diagnostic techniques are transesophageal echocardiography, ventriculography, MDCT, magnetic resonance imaging (MRI) and radionuclide scintigraphy. Coronary angiography almost always reveals some abnormality in patients with a pseudoaneurysm (98%) [1]. Our patient had total stenosis of the circumflex artery after the first obtus marginal branch and a muscular bridge on LAD. Myocardial bridging accompanying a LV pseudoaneurysm is a rare finding. The pseudoaneurysm in our case extended through the apex and in recent years myocardial bridging is also shown to be related with apical balooning syndrome, which is characterized by transient apical aneurysms [6].

Because of its rarity, the natural course of a left ventricular pseudoaneurysm is not well established. In pseudoaneurysms related with acute myocardial infarction, timing of the surgery depends on the age of the myocardial infarction. Surgery is urgently recommended in acute pseudoaneurysms, which are discovered within 2 to 3 months after a myocardial infarction, because the onset of rupture is unpredictable [7]. In patients with acute myocardial infarction, surgery is associated with a 23-35.7 % mortality rate, but the risk of rupture is 50% [1,7]. Early postoperative mortality is associated with poor LV functions rather than surgical techniques. However, when the diagnosis is made years after the myocardial infarction, the urgency or need of the operation is determined by symptoms rather than risk of rupture. In a review by Frances and colleagues, of 31 patients with chronic pseudoaneurysm, 16 were alive at a median time of 156 weeks [1]. In another study, the probability of being free of cardiac death was 88.9% at both 1 and 4 years in 10 patients with postinfarction left ventricular pseudoaneurysm [8]. Symptomatic patients or those with a large (>3 cm) or gradually enlarging pseudoaneurysm should be treated surgically [8]. MDCT and cardiac MRI can provide a full depiction of the left ventricle and the adjoining pseudoaneurysm, enhancing the preoperative evaluation of the lesion. Regular echocardiographic evaluations should be performed to detect any increase in size for small and asymptomatic pseudoaneurysms.

Competing interests

The authors declare that they have no competing interests.

References

1. Frances C, Romero A, Grady D. Left ventricular pseudoaneurysm. J Am Coll Cardiol 1998; 32: 557-61.
2. Arenja N, Mueller C, Ehl NF, Brinkert M, Roost K, Reichlin T, et al. Prevalence, Extent, and Independent Predictors of Silent Myocardial Infarction. Am J Med. 2013 Apr 15. pii: S0002-9343(13)00101-0. doi: 10.1016/j.amjmed.2012.11.028. [Epub ahead of print]
3. Yeo TC, Malouf JF, Oh JK, Seward JB. Clinical profile and outcome in 52 patients with cardiac pseudoaneurysm. Ann Intern Med. 1998; 128: 299-305.
4. Brown SL, Gropler RJ, Harris KM. Distinguishing left ventricular aneurysm from pseudoaneurysm. A review of the literature. Chest 1997; 111:1403-9.
5. Michels R, Brueren G, van Dantzig J-M, Pijls N, Peels CH, Post H. ACS, myocardial bridging, Tako-tsubo syndrome and mitral regurgitation. Netherland Heart Journal 2005; 13: 57-61.
6. Shabbo FP, Dymond DS, Rees GM, Hill IM. Surgical treatment of false aneurysm of the left ventricle after myocardial infarction.Thorax 1983; 38:25-30.
7. Eren E, Bozbuga N, Toker ME, Keles C, Rabus MB, Yildirim O, et al. Surgical treatment of post-infarction left ventricular pseudoaneurysm: a two-decade experience. Tex Heart Inst J 2007; 34: 47-51.
8. Moreno R, Gordillo E, Zamorano J, Almeria C, Garcia-Rubira JC, Fernandez-Ortiz A, et al. Long term outcome of patients with postinfarction left ventricular pseudoaneurysm. Heart. 2003; 89: 1144-6.

How to cite this article:
Elalmış ÖU, Şahin İ, Kanat S, Gürsoy HT, Karagöz A. An Unusual Case of a Giant Left Ventricular Pseudoaneurysm. J Clin Anal Med 2013;4(suppl 1): 64-6.