Kounis Syndrome Associated with Non-ST Elevation ECG Changes

ST Elevasyonsuz EKG Değişiklikleri ile Birlikte olan Kounis Sendromu

Kounis Sendromu / Kounis Syndrome

Orçun Çiftci[1], Fatma Çiftci[2], Cemil Kavalcı[3], Gülsüm Kavalcı[4]
[1]Başkent University Faculty of Medicine Department of Cardiology, [2]Ankara University Faculty of Medicine Department of Chest Diseases,
[3]Başkent University Faculty of Medicine Department of Emergency Medicine, [4]Yenimahalle State Hospital, Department of Anesthesiology, Ankara, Turkey

Özet

Kounis sendromu genellikle EKG'de ST segment elevasyonu ile birlikte olmasına rağmen ST segment depresyonu ve/veya T dalga inversiyonu ile giden akut koroner sendromlar da olası, ancak çok nadirdir. Bu vaka, bu nadir sendromun ve sendromun kendisinden de nadir olan ve alerjik olayın tedavisi sonrası düzelen ST elevasyonsuz EKG değişiklikleri ile giden formunun bilinmesinin önemini göstermektedir. Elli beş yaşında kadın hasta, amoksisilin alımını takiben eşzamanlı akut ürtiker ve göğüs ağrısı ile başvurdu. Seri EKG'leri iskemik ST segment depresyonları ve T dalga inversiyonları gösterdi. Aspirin ve antialerjik medikasyonlar ile tedavi sonrası semptom ve bulguları geriledi. İlk EKG'den 6 saat sonra ST segment depresyonları ve T dalga inversiyonları normale döndü. CK/MB ve troponin I'yı kapsayan kardiyak enzimleri başvuru, 6. ve 12. saatte normal geldi. Kounis sendromu ile ilişkili kararsız angina pektoris tanısı konuldu. Koroner anjiyografiyi ve deri alerji testini reddeden hasta kendi isteği ile taburcu oldu.

Anahtar Kelimeler

Allerji; Kounis Sendromu; EKG; Akut Koroner Sendrom

Abstract

Although Kounis syndrome is typically associated with ST segment elevation on ECG, acute coronary syndromes with ST segment depression and/or T wave inversion are also possible, albeit very rare. This case illustrates the importance of awareness of this rare syndrome and its even rarer form with non-ST segment elevation ECG changes that normalize with elimination of acute allergic insult. A 55-year-old woman admitted with simultaneous acute urticaria and chest pain following ingestion of oral amoxicillin. Her serial ECGs showed ischemic ST segment depressions and T wave inversions. After treatment with aspirin and antiallergic medications her signs and symptoms abated. ST segment depressions and wave inversions normalized 6 hours after the first ECG. Cardiac enzymes including CK/MB and troponin I at presentation, and 6th and 12th hours were negative. She was diagnosed with unstable angina pectoris associated with Kounis syndrome. She refused coronary angiography and skin allergy test and was discharged on her own request.

Keywords

Allergy; Kounis Syndrome; EKG; Acute Coronary Syndrome

DOI: 10.4328/JCAM.2002 Received: 03.08.2013 Accepted: 31.08.2013 Printed: 01.09.2013 J Clin Anal Med 2013;4(suppl 1): 67-9
Corresponding Author: Orçun Çiftci, Başkent University Faculty of Medicine Department of Emergency Medicine, Fevzi Çakmak Caddesi 10. Sokak No:45 Bahçelievler, Çankaya, Ankara, Türkiye. T.: +90 3122126868 (6705-6724) GSM: +905325946822 E-Mail: orucun@yahoo.com

Introduction

Kounis syndrome is a rare co-occurence of acute allergic reactions with acute coronary syndromes, most commonly with ST segment elevation [1]. ECG changes without ST elevation are very rare, although reported [2]. This paper reports a middle-aged woman with non-ST segment elevation changes and a clinical picture consistent with unstable angina pectoris, which resolved after treatment of allergic insult.

Case Report

A 55-year-old woman admitted to emergency department with simultaneous symptoms of redness of skin and pruritus, and chest pain following ingestion of oral amoxicillin. Her vital signs were as follows: blood pressure 130/75 mmHg, pulse rate: 98 bpm, respiratory rate: 20/min, body temperature: 36.8ºC. On physical examination, she had urticarial plaques all over the body with a tendency to coalesce. Her first ECG was normal and the subsequent ECGs showed ischemic ST segment depressions and T wave inversions (Table 1). She was treated with methyl prednisolone 1mg/kg, phenyramine 45.5 mg I.V., ranitidine 100 mg I.V, and aspirin 300 mg P.O. Urticarial signs and symptoms abated and chest pain subsided. ST segment depressions and T wave inversions normalized in the final ECG taken approximately 6 hours after the first ECG (Table 1). Her cardiac enzymes including CK/MB and troponin I at presentation, at 6th and 12th hours were negative. She was diagnosed with unstable angina pectoris associated with Kounis syndrome. After an overnight monitorization she was offered coronary angiography but refused to undergo any intervention. She also refused to take any skin allergy test or other tests and was discharged at the same day on her own request. She was discharged on antihistaminic therapy along with daily aspirin 100 mg PO, a calcium channel blocker, and a statin. She did not attend a follow-up nor admit again with similar complaints.

Discussion

Acute coronary syndrome induced by allergy is a less known clinical entity. Kounis syndrome is described as the co-occurence of acute coronary syndrome with allergic insults including allergic and hypersensitivity reactions, and anaphylaxis [1]. It is caused by mast cell activation; resulting in mast cell degranulation and release of chemical mediators, including histamine, leukotrienes as well as tryptase and chymase that activate metalloproteinases which degrade collagen and induce plaque rupture [3]. Histamine is known to be a powerful vasodilator in the peripheral circulation but it exerts a constrictor action on smooth muscle of coronary arteries via H1 receptors, leading to vasospasm [3].

Two types of Kounis syndrome have been defined. Type 1 occurs in people with normal coronary arteries. Type 2, on the other hand, includes patients with preexisting coronary artery disease with plaques or flow-limiting stenoses which are eroded or ruptured by inflammatory mediators or coronary vasospasm.

A variety of food or environmental substances have been reported to cause Kounis syndrome [4,5]. Our patient had a history of penicillin intake.

So far, most of reported cases had an ECG presentation that is characterized by ST segment elevation and associated with cardiac ischemia and/or infarction. Our patient, to the contrary, presented with ST segment depressions and T wave inversions. Furthermore, no detectible rise in cardiac biomarkers occurred. To our knowledge, it is rare in literature to encounter patients with Kounis syndrome presenting with unstable angina pectoris characterized primarily by ST segment depression rather than ST segment elevation. Kounis syndrome is normally expected to occur with temporary or permanent ST segment elevation since the primary mechanism of acute coronary syndromes associated with this syndrome involves histamine-induced coronary vasospasm and hence transmural injury pattern (ST segment elevation). However, chymase and tryptase activate metalloproteinases and cause plaque rupture that can cause USAP and non-ST elevation myocardial infarction (NSTEMI). Calogiuri et al [6] reported a case with Kounis syndrome associated with intravenous administration of piperacillin/tazobactam, leading to unstable angina with ST depressions and normal troponin level. Although we could not document the coronary anatomy with coronary angiography, the present case was consistent with acute coronary syndrome secondary to plaque rupture/erosion induced by mast cell activation, leading to unstable angina pectoris and ST segment depression rather than ST segment elevation. It is also possible to speculate that this patient had Type 2 Kounis syndrome such that preexisting coronary plaques were eroded or ruptured by the aforementioned effects. This shows that it is well possible to encounter patients with Kounis syndrome exhibiting ST depression or T inversions without ST elevation.

In conclusion, Kounis syndrome should be remembered in patients with simultaneous allergic reactions and chest pain. Clinicians should also be aware that this syndrome may present with ST segment depression and/or T wave inversion which are even rarer.

There are some limitations to our report. First, we have no information about eosinophil count and levels of specific Ig E, serum histamine, tryptase, complement proteins (c4 and c1 elastase). The patient was first seen in the emergency department and followed in coronary care unit thereafter. It could ideally be considered to measure these parameters to confirm an allergic insult, but as the patient presented close to midnight and refused further workup at the morning we could not make such measurements. Since Kounis syndrome is a clinical entity combining acute allergic reactions and acute coronary syndromes, a clinical picture consistent with chest pain and objective ST-T changes in the context of acute allergic reactions usually suffice for diagnosis. In fact, resolution of chest pain with abating allergic signs and symptoms made our diagnosis quite secure. We thus think that, while being a limitation, not having performed such tests did not violate our diagnosis. Second limitation to our report is that invasive coronary angiography, the gold standard diagnostic modality for coronary artery disease was not performed because the patient refused coronary angiography and left hospital. As our clinical picture was very consistent with Kounis syndrome we could reliably diagnosed the latter although we could not ascertain the type of Kounis syndrome (type I vs Type 2).

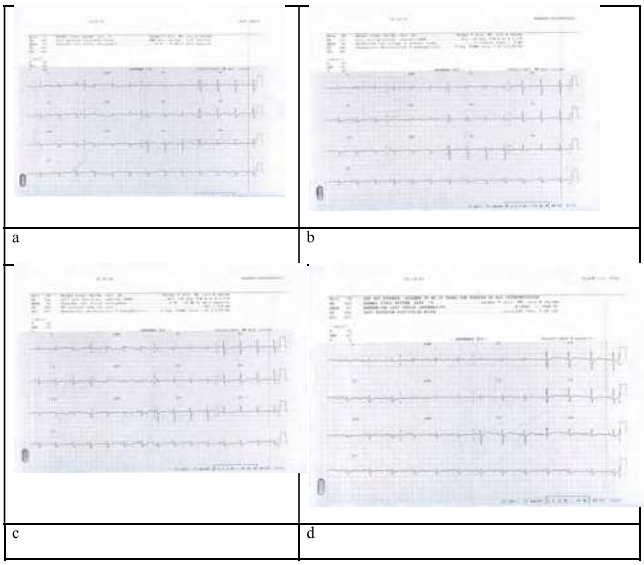

Table 1. Serial ECG's of the patient. Admission ECG (A) did not show ST-T changes, however, follow-up ECG's in 25 and 50 minutes after presentation (B,C) showed T wave flattening in V2, V6, D1, aVF and aVL, symmetrical T wave inversions in V3-V5, and 0.5 mm ST depressions in V5-V6. These changes showed minor temporal variability. Final ECG taken after resolution of symptoms at 6 hour (D) showed normalized ST-T segments

Competing interests

The authors declare that they have no competing interests.

References

1. Kounis NG, Zavras GM. Histamine-induced coronary artery spasm: the concept of allergic angina. Br. J. Clin. Prac1991;45:121-128,
2. Gázquez V, Dalmau G, Gaig P, Gómez C, Navarro S, Mercé J. Kounis syndrome: report of 5 cases. J Investig Allergol Clin Immunol. 2010;20(2):162-5.
3. Toda N. Mechanism of histamine actions in human coronary arteries. Circ Res 1987;61:280-286,
4. Brener Z, Zhuravenko I, Bergman M. Acute myocardial injury following penicillin-associated anaphylactic reaction in a patient with normal coronary arteries. Am JMed Sci. 2007;334 :305-7.
5. Mytas DZ, Stougiannos PN, Zairis MN, et al. Acute anterior myocardial infarction after multiple bee stings. A case of Kounis syndrome. Int J Cardiol. 134:e129-31. 2009.doi: 10.1016/j.ijcard.2008.01.050. Epub 2008 Jun 12.
6. Calogiuri G.F, Nettis E , Di Leo E , et al. Kounis Syndrome induced by intravenous administration of piperacillin/tazobactam: A case report. Int J Cardiol. 155:e42-4,2012.doi: 10.1016/j.ijcard.2011.07.049. Epub 2011 Aug 11.

How to cite this article:
Çiftci O, Çiftci F, Kavalcı C, Kavalcı G. Kounis Syndrome Associated with Non-ST Elevation ECG Changes. J Clin Anal Med 2013;4(suppl 1): 67-9.