Multiple Hydatid Cysts Settled in Lung, Liver, Mediastinum and Front Abdominal Wall

Akciğer, Karaciğer, Mediasten ve Batın Ön Duvarında Yerleşimli Multiple Kist Hidatik Olgusu

Multiple Yerleşimli Kist Hidatik Olgusu / A Hydatid Cyst with Multiple Localization

Nurhan Köksal[1], Hasan Kahraman[2], Canan Eren Dağlı[3], Mahmut Tokur[4], Hasan Türüt[5]
[1]Ondokuzmayıs University, Faculty of Medicine, Chest Disease, Samsun, [2]Kahramanmaraş Sütçü İmam University, Faculty of Medicine, Chest Disease, Kahramanmaraş, [3]Gaziantep University, Faculty of Medicine, Chest Disease, Gaziantep, [4]Kahramanmaraş Sütçü İmam University, Faculty of Medicine, Chest Surgery, Kahramanmaraş, [5]Rize University, Faculty of Medicine, Chest Surgery, Rize, Türkiye

Özet

Kistik ekinokokkoz, Echinococcus granulosus'un larva evresinin (metacestode) oluşturduğu koyun yetiştirme bölgelerinde endemik olan ve en sık ihmal edilen hastalıklar arasındadır. Parazit yumurtaları yutulduktan sonra, bağırsağı penetre edebilir ve portal dolaşım yolu ile tüm vücuda özellikle major filtreleme organları olan karaciğer ve akciğerlere yerleşebilir. Bizim vakamız, vücudun değişik bölgelerinde çok sayıda kistlerle presente olmasından dolayı ilginç bir olgudur. Albendazol tedavisi aldıktan sonra bazı kistlerin radyolojik regresyona ve bazılarında ise perforasyon oluşması ile birlikte cerrahi tedavi gerektirdi.

Anahtar Kelimeler

Kistik Ekinokokkoz; Hidatik Kist; Benzimidazoller

Abstract

Cystic echinococcosis, caused by the larval stage (metacestode) of Echinococcus granulosus, is endemic in sheep raising areas and is among the most neglected diseases. Once ingested, parasitic eggs may penetrate intestine and settled via portal circulation to whole body especially to liver and lung as being major filtering organs. Our case is a interesting case, because of presenting multiple cysts in different regions of the body. With Albendazol treatment, some radiologic regression was shown, but also perforation of some hydatid cysts, surgery was needed for treatment.

Keywords

Cystic Echinococcosis; Hydatid Cyst; Benzimidazoles

DOI: 10.4328/JCAM.2019 Received: 12.08.2013 Accepted: 31.08.2013 Printed: 01.09.2013 J Clin Anal Med 2013;4(suppl 1): 70-2
Corresponding Author: Kahraman Hasan, Kahramanmaraş Sütçü İmam Üniversitesi, Tıp Fakültesi, Göğüs hastalıkları AD, Yörükselim Mah. Hastane Cad. No:32, Kahramanmaraş, Türkiye. T.: +90 3442212371 GSM: +905338164036 E-Mail:drhasankahraman@hotmail.com

Introduction

Cystic echinococcosis (CE) is a zoonostic disease produced by the larval stage of the cestode, Echinococcus granulosus. Tapeworms live in the intestine of dogs or other canines (definitive host) and their eggs are passed out with faeces. The eggs disperse widely and can survive for at least 1 year in external environment. Once ingested by a suitable intermediate host (sheep, cattle, goats, pigs, horses, or camels), eggs transform to embryos in intestine, penetrate the intestinal lining, spread through the portal circulation, and lodge into tissues, mostly to liver and lung as being major filtering organs. Embryos then transform to cystic metacestodes in which the infective protoscolices will develop. When a canine eat the cystic visceral organ, protoscoleces attached to the intestine of canine and develop into mature adult tapeworms in about 40–45 days. Human beings can act as intermediate hosts if they ingest the eggs and after many years large cyst develop [1,2,3,4]. In 40-60% of patients, there were no symptoms and sign. The presenting symptoms of pulmonary CE are duo to the mass effect of cyst. The common presenting symptoms are as follows: Cough (53–62%), chest pain (49–91%), dyspnea (10–70%), and hemoptysis (12–21%). Other symptoms described less frequently include dyspnea, malaise, nausea and vomiting, and thoracic deformations [5]. Cysts can leak to bronchi and become infected [6]. Radiological studies are the primary step in the detection and evaluation of pulmonary CE, the role of serology is mostly limited to case confirmation. Ultrasonography of the abdomen still remains the major noninvasive screening and may confirm the diagnosis of CE, by demonstrating the pathognomic daughter cysts [7]. The computerized tomography (CT) does not confirm the diagnosis of CE, as it may mimic malignant and benign conditions such as congenital cyst, pseudocyst, or hematomas [8]. However, the presence of daughter cysts, germinal epithelium detachment and calcification may confirm the diagnosis. Similarly, MRI can reveal a cystic mass containing daughter cysts, with rim sign and “water lily sign” [9]. Surgery is the main therapeutic approach [10]. The use of presurgical medical treatment reduces the chances of seeding and recurrence [2]. WHO guidelines for CE stated that treatment containing benzimidazoles (mebendazole or albendazole) are preferred when surgery is not available or complete removal is not feasible. Medical treatment can result in reduction of the cyst size, but may not effective for large cyst. Long term treatment of albendazole, with dose of 400 mg twice a day, is somewhat effective for pulmonary CE [2].

Case Report

A 30-year-old woman presented cough and sputum with 4 months period in the 27th week of pregnancy. Physical examination of respiratory system was normal. With abdominal ultrasonography, multiple cysts with 5 cm the largest diameter were revealed and suggested the diagnosis of CE and the patient was followed-up during pregnancy. After vaginal delivery, CT was shot and multiple cysts were detected in liver, lung and also in the mediastinum and the abdominal wall (Figure 1A, 1B, 1C). Fine needle aspiration was performed to the cyst settled at the abdominal wall, scolexes of EG were determined in microscopic examination of the cystic fluid. Albendazol (10-15 mg/kg/day) treatment was started. At the 12 th day of the treatment, patient complained from clear liquid and membrane particles coming from mouth by coughing. After that, she complained from recurrent purulent sputum and hemoptysis. At the 3rd month of the treatment, thorax and abdominal CT were shot and shown that some of the cysts disappeared completely, some of them significantly reduced in diameter, some of them drained off via bronchus, and some of them were persistant (Figure 2A, 2B, 2C, 2D). Because of recurrent infections and hemoptysis, operation was planed. First cystotomy and capitonnage were performed to the right thorax and one month later same procedures were performed to the left thorax. No operation was considered and performed to the cysts in the liver, at the mediastinum, and at the abdominal wall.

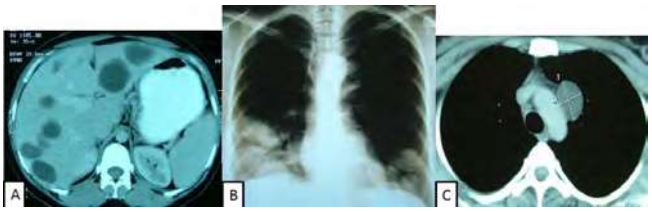

Figure 1. Mediastinal window of computerized tomography (CT) showing multiple hepatic cysts with different diameters(A); P-A chest graph showing multiple cysts at bilateral lower lung fields(B); Mediastinal window of CT showing solitary cystic lesion near the arcus aorta(C)

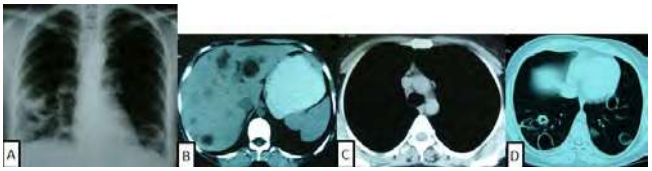

Figure 2: Three month later; P-A chest graph showing perforated multiple cysts at bilateral lower lung fields(A); Mediastinal window of computerized tomography (CT) showing regression in diameter and activity of liver cysts(B); Mediastinal window of CT disappearing cystic lesion that previously presented near the arcus aorta(C); Parenchymal window of CT showing that some cysts were stable and others perforated(D)

Discussion

Cystic echinococcosis is a common entity in the sheep-farming areas of Europe, the Mediterranean region, South America, Australia, New Zealand, the Middle East, and Turkey [11]. Human infection occurs by ingestion of the eggs of Echinococcus granulosus inadvertently with food, especially unwashed vegetables and water contaminated with faeces of infected canines [12]. The embryos may enter portal circulation from the upper intestine and may lodge to the liver, the lung and other organs where they develop into cysts [1]. In Turkey, the incidence of CE has been estimated at 1/2.000 in the general population and nearly one-third of all reported cases from Turkey are under the age of 20 years [13]. In our case because of multiple presentations of cysts at lung, liver, mediastinum, and abdominal wall, we began to treat first medically. During medical treatment rupture of some cysts were occurred. Although radiologic improvement of cysts presented at liver, abdominal wall, and mediastinum were satisfactory, existing the recurrent infections, hemoptysis and persistence of some lung cysts drove us to surgical treatment. Operation was first performed to the right than to the left thorax. Although promising results have been reported with the albendazole treatment, surgery is still first choice for the treatment of CE [11]. We think that our case was interesting

for having multiple cysts in different regions of the body, for showing radiologic regression and perforation of cysts during albendazol treatment and for requiring the surgical treatment.

Competing interests

The authors declare that they have no competing interests.

References

1. Brunetti E, Junghanss T. Uptade on cystic hydatid disease.Current Opinion in İnfectious Disease 2009; 22;497-502.
2. Santivanez S, Garcia HH. Pulmonary cystic ecinococcosis.Current Opinion in Pulmonary Medicine 2010; 16:257-61.
3. Moro P, Schantz PM. Echinococcosis: a review. Int J Infect Dis 2009; 13:125–33.
4. Garcia HH, Moro PL, Schantz PM. Zoonotic helminth infections of humans: echinococcosis, cysticercosis and fascioliasis. Curr Opin Infect Dis 2007; 20:489–94.
5. Arinc S, Kosif A, Ertugrul M, Arpag H, Alpay L, Unal O, Devran O, Atasalihi A. Evaluation of pulmonary hydatid cyst cases. Int J Surg 2009; 7:192–5.
6. Turgut AT, Altinok T, Topcu S, Kosar U. Local complications of hydatid disease involving thoracic cavity: imaging findings. Eur J Radiol 2009; 70 :49–56.
7. Niron EA, Ozer H. Ultrasound appearances of liver hydatid disease. Br J Radiol 1981; 54:335-8.
8. Czermak BV, Unsinn KM, Gotwald T, Gotwald T, Niehoff AA, Freund MC, Waldenberger P, Vogel W, Jaschke WR. Echinococcus granulosus revisited Radiologic patterns seen in pediatric and adult patients. Am J Roentgenol 2001; 177:1051-6.
9. Comert RB, Aydingoz U, Ucaner A, Arikan M. Waterlily sign on MR imaging of primary intramuscular hydatidosis of sartorius muscle. Skeletal Radiol 2003; 32:420-3.
10. Tatar D, Senol G, Gunes E, Gunes E, Unsal S, Perim G. Diagnosis and treatment of pulmonary cystic hydatidosis. Indian J Pediatr 2008; 75:1003–7.
11. Köseoğlu B, Bakan V, Onem O, Bilici S, Demirtas I. Pulmonary Hydatid Disease in Children. Surg Today 2002; 32:779–83.
12. Amr SS, Amr ZS, Jitawi S, Annab H. Hydatosis in Jordan. An epidemiological study of 306 cases. Ann Trop Med Parasitol 1994; 88:623-27.
13. Demirbilek S, Sander H, Atayurt F, Aydın G. Hydatid disease of the liver in childhood: the succes of medical therapy and surgical alternatives. Pediatr Surg Int 2001; 17:373-7.

How to cite this article:
Köksal N, Kahraman H, Dağlı CE, Tokur M, Türüt H. Multiple Hydatid Cysts Settled in Lung, Liver, Mediastinum and Front Abdominal Wall. J Clin Anal Med 2013;4(suppl 1): 70-2.