Invasive Inflammatory Myofibroblastic Tumor of the Kidney with Anaplastic Lymphoma Kinase (ALK) Expression. A Case Report

Böbreğin Anaplastik Lenfoma Kinaz (ALK) Eksprese Eden İnvaziv İnflamatuar Miyofibroblastik Tümörü. Bir Olgu Sunumu

Böbreğin İnvaziv İnflamatuar Miyofibroblastik Tümörü / Invasive Inflammatory Myofibroblastic Tumor of the Kidney

Şirin Başpınar[1], Nilgün Kapucuoğlu[1], Eylem Çaloğlu[1], Alper Özorak[2], Ahmet Güzel[2], Bumin Değirmenci[3]
[1]Department of Medical Pathology, [2]Department of Urology, [3]Department of Radiology,
Suleyman Demirel University School of Medicine, Isparta, Turkey

Özet

İnflamatuar miyofibroblastik tümör (İMT) prolifere miyofibroblastlar ve inflamatuar hücreleri içeren bir neoplazmdır. Vücutta neredeyse her bölgede bildirilmiş olsa da renal yerleşim oldukça nadirdir. Böbrekte ortaya çıkan diğer benign ve malign iğsi hücreli lezyonlardan histolojik olarak ayrılması gerekir. Burada 78 yaşında kadın hastada perirenal doku ve pankreasa lokal invazyon gösteren ve başlangıçta klinik ve radyolojik incelemelerde renal hücreli karsinom olarak yorumlanan sol böbrek yerleşimli İMT olgusu sunuldu. Tümör hücrelerinin immunhistokimyasal olarak düz kas aktini, anaplastik lenfoma kinaz ve vimentin pozitifliği göstermesi İMT tanısını destekledi. Bu ender görülen tümörün histopatolojik özellikleri ve ayırıcı tanısı literatür gözden geçirilerek tartışıldı.

Anahtar Kelimeler

İnflamatuar Miyofibroblastik Tümör; Böbrek; Anaplastik Lenfoma Kinaz

Abstract

Inflammatory myofibroblastic tumor (IMT) is a neoplasm of proliferating myofibroblasts, with inflammatory cells. It has been reported in nearly every site of the body, but renal location is extremely rare. Histologically it needs to be differentiated from other benign and malignant spindle cell lesions occurring within the kidney. Here, we presented a 78-year-old woman who had IMT of the left kidney with local invasion to perirenal tissue and pancreas that was initially misinterpreted as a renal cell carcinoma upon clinical and radiographic examinations. The tumor cells which were positive immunohistochemically for smooth muscle actin, anaplastic lymphoma kinase and vimentin supported the diagnosis of IMT. We discussed the histopathological features and differential diagnosis of this rare neoplasm in the review of the literature.

Keywords

Inflammatory Myofibroblastic Tumor; Kidney; Anaplastic Lymphoma Kinase

DOI: 10.4328/JCAM.2026 Received: 24.08.2013 Accepted: 02.09.2013 Printed: 01.09.2013 J Clin Anal Med 2013;4(suppl 1): 77-80
Corresponding Author: Sirin Baspinar, Süleyman Demirel Üniversitesi Tıp Fakultesi Tıbbi Patoloji AD, Isparta, Türkiye.
T.: +90 2462119290 F.: +90 2462371762 E-Mail: sirinbaspinar@gmail.com

Introduction

Inflammatory myofibroblastic tumor (IMT) is a slow growing lesion with an unknown malignant potential which is most commonly found in the lung; however, it may also arise in a variety of tissues and organs including the respiratory tract, gastrointestinal tract, central nervous system, orbit, soft tissues, spleen, lymph nodes, thyroid, uterus, and heart [1,2]. In the genitourinary tract, IMT most commonly occurs in the bladder. Also case studies of IMT of the kidney, renal pelvis, and ureter have been previously reported [3]. IMT occurs primarily in children and young adults but can occur at any age [4]. It is composed of inflammatory infiltrate of plasma cells, histiocytes, lymphocytes, and eosinophils in a matrix of myofibroblastic mesenchymal spindle cells [4]. Although the etiology of this tumor is unclear, an exaggerated inflammatory reperative reaction to trauma, autoimmune reaction or infection has been suggested as etiologic factors of these lesions [1]. IMT was initially thought to be of purely inflammatory origin but recently, these lesions have been perceived as low-grade mesenchymal neoplasms associated with secondary inflammatory changes. Also further studies suggested a neoplastic nature which is evidenced by clonal cytogenetic abnormalities and more aggressive clinical behavior such as local recurrence, and even distant metastases [5]. In addition, approximately 50 – 70% of IMTs have been shown to harbor clonal cytogenetic aberrations of the anaplastic lymphoma kinase (ALK) gene on the short arm of chromosome 2 at 2p23, and these patients had a higher frequency of recurrence, confirming the neoplastic nature of this subset of IMT [4]. IMT has been reported rarely in the kidney, and all the IMFTs of kidney reported in literature did not show ALK-1 expression. However, this is the first report of ALK-1 positive IMT of the kidney with pancreas invasion which may emphasize the role of immunohistochemical overexpression of ALK-1 protein in establishing the diagnosis of IMT and the relation between ALK-1 gene expression and IMT's malignant biological behavior such as local invasion.

Case Report

A 78 year-old woman presented to our hospital with complaints of abdominal pain. There was no previous trauma, and the medical history was unremarkable. Laboratory examinations of routine blood and urine tests revealed no abnormalities. During the clinical evaluation, a left renal mass detected on ultrasonography measuring 25×25×20 cm which located in the upper pole of the left kidney, with an extension to the perinephric fat tissue. Computed tomography (CT) scan also confirmed an intrarenal mass involving the upper region of the left kidney with possible extension into spleen and pancreas tail (Figure 1). The contralateral kidney was normal. On the basis of the clinical and radiologic findings, a malignancy such as renal cell carcinoma was suspected. The patient underwent left radical nephrectomy, splenectomy and partial pancreas resection for presumed renal cell carcinoma.

On macroscopic examination, the mass appeared to be a solid, firm, white tumor measuring 17×15×6.5cm, and replaced both the cortex and the medulla, compressing the pelvis in the upper pole of the kidney. The tumor extended to the perinephritic fat tissue and showed adherence and invasion to pancreas. It was also densely adherent to the spleen but had no spleen involvement on gross examination. No gross necrosis or hemorrhage was noted. Examination of the microscopic section showed a spindle cell proliferative lesion arranged mainly in a short fascicular pattern among a fibrous stroma, rich in mixed inflammatory cells composed of plasma cells, histiocytes, lymphocytes, and eosinophils. The spindle cell proliferation consisted of relatively uniform cells with no nuclear atypia and rare mitoses (Figure 2A, 2B). Epithelial structures, such as tubules or glomeruli, were not found within the tumor. Multiple sections studied from the resection materials showed tumor invasion in pancreas (Figure 2C). Surgical margins were clear and no histologic evidence of extension into the renal vein, artery, or ureter was found.

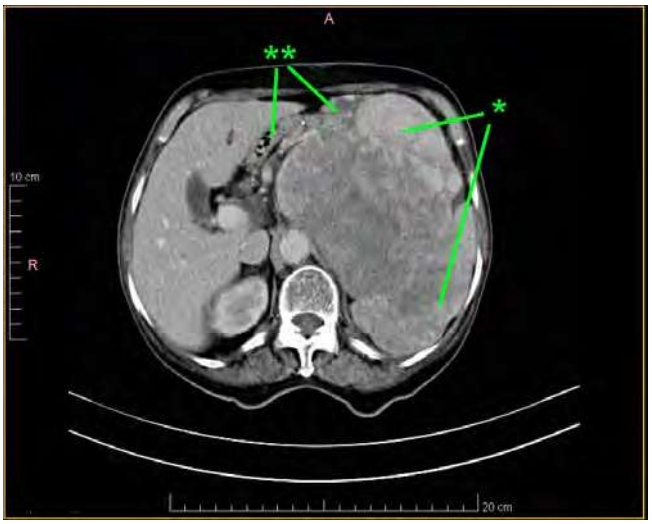

Figure 1: Preoperative CT scan demonstrates a left renal parenchymal mass with extension to the pancreas (* indicates the tumor, ** indicates the pancreas tail)

Immunohistochemically, the spindle-shaped cells expressed smooth muscle actin (SMA) (Figure 3A), ALK-1 (Figure 3B), and vimentin. HMB-45, desmin, CD34, and pan-keratins were negative. Ki-67 proliferative index was 10% (Figure 3C). On the basis of the histopathologic and immunohistochemical findings, a diagnosis of IMT was made. No adjuvant treatment was given after surgical excision and she presented 2 months later with recurrent abdominal pain, and pleural effusion and assit was

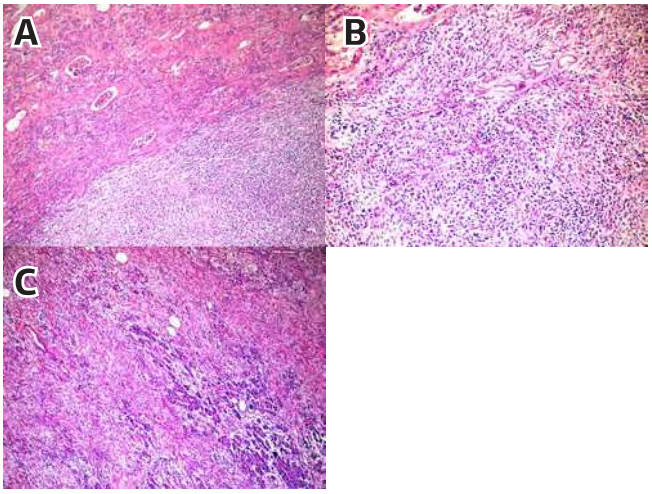

Figure 2: (A) Tumor composed of spindle cells admixed with inflammatory cells (HE; 100×) and, (B) high power shows a distinctive inflammatory cell infiltrate composed of plasma cells and lymphocytes (HE; 200×). (C) Tumor invasion to pancreas (HE; 100×).

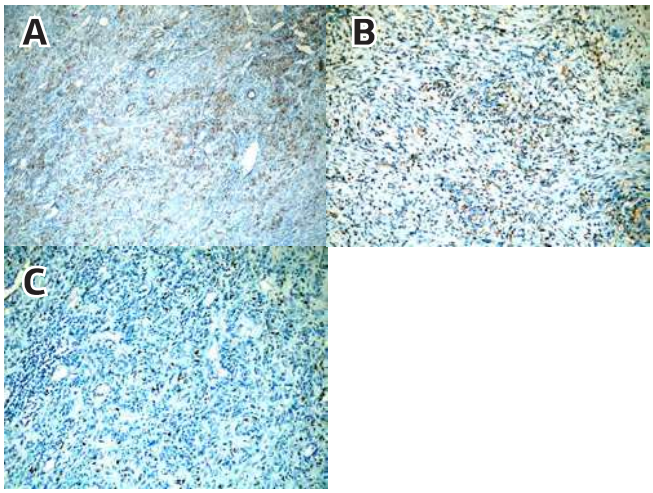

Figure 3. Immunohistochemical expression of (A) SMA (DAB; 100×), (B) ALK-1 (DAB; 200×) and, (C) Ki-67 (DAB; 200×) in tumor cells.

noted on abdominal USG. USG guided thoracentesis and paracentesis were performed and the diagnosis was benign cytology, but seven months after surgery, the patient died because of complications related to tumor invasion and treatment.

Discussion

Urinary tract IMTs are uncommon and may mimic other more common malignancies. Most patients present with a solitary mass, although in some patients multiple masses involving one region have been reported [2]. There are only a few reports in the literature reporting IMT in the kidney. In all these reports, IMTs were non-invasive and confined to organ borders. We report the clinicopathological features of an intrarenal IMT presenting as a large mass in the upper region of the left kidney with extension into pancreas. The mass was initially considered an aggressive malignant neoplasm according to radiological and clinical examinations.

Three histologic patterns have been identified in IMT, including a myxoid vascular pattern, a compact spindle cell pattern and a hypocellular fibrous pattern [2]. In the majority of tumours, one pattern dominates with some representation from the other patterns. Nuclear pleomorphism and mitotic figures are not prominent, but occasional atypical cells with large nuclei can be seen [6]. Immunohistochemically, most cases of IMT express SMA and muscle-specific actins. Some cases have desmin and cytokeratin reactivity [6]. ALK immunostaining is detected in 40%–60% of cases [7]. The histology in our case is consistent with the second pattern. Immunohistochemical studies, including our study, support the myofibroblastic nature of this lesion with consistent expression of vimentin and SMA.

IMT may also be differentiated from malignant tumors such as sarcomatoid renal cell carcinoma, myxoid leimyosarcoma, fibrosarcoma, rhabdomyosarcoma, malign fibrous histiocytoma, and malignant nerve sheath tumors, by the absence of dense cellularity, cellular pleomorphism, necrosis, severe atypia, high mitotic rates and with the help of immunohistochemical staining of IMTs for ALK-1 [8].

Histologically, IMT usually lacks mitoses, atypia, and pleomorphism of cells. Presence of a polymorphous inflammatory infiltrate supports the diagnosis of IMT [2]. The histopathologic features that are associated with aggressive behavior remain undetermined, although the presence of cellular atypia, ganglion-like cells, increased mitotic figures, multinodularity, DNA aneuploidy, elevated Ki-67 proliferative index, and oncogenic protein overexpression, such as ALK, p53, and bcl-2 may identify a subset of tumors that have the potential for recurrence or malignant transformation [9]. In our case cellular atypia, ganglion-like cells and, multinodularity were not observed. Mitotic figures and Ki-67 proliferative activity were low; however we observed ALK expression in spindle shaped tumor cells.

Coffin et al. [4] demonstrated that ALK-positive IMTs were diagnosed in younger patients and had a tendency to recur. However, ALK-negative IMTs were associated with the presence of metastases [4]. They concluded that, ALK reactivity may be a favorable prognostic indicator in IMT and abdominopelvic IMTs recur more frequently [4]. Recently in the study of Kapusta et al. [3] all of the cases of IMT of kidney were negative for ALK-1 [3]. Inconsistent with the findings of Coffin et al. [4] our patient was an old woman, and the tumor with local invasion to pancreas, showed ALK-1 immunoreactivity. Although the follow up has been 7 mounths during this time neither recurrences nor metastases have been observed in our patient.

ALK-1 negative IMT of kidney may represent a subset of IMT with different disease process or subset that may be reactive in nature [3]. The relation between ALK-1 gene expression and IMT's agressiveness such as tendency to recur, infiltrative local growth, vascular invasion, and malign transformation has not been clarified. Further investigation is necessary to determine whether IMT has a different transforming mechanism or if different regions of the ALK-1 gene are involved in the pathogenesis of this lesion [4,7]. As in our case, ALK-1 positive immunoreactivity can be correlated with aggressive clinical features such as infiltrative growth.

The clinical course of IMT is usually relatively indolent but recurrences are documented especially in the extrapulmonary lesions, which are larger than 8 cm and which are locally invasive [2]. A small subset of IMT (10–15%) shows a more aggressive and metastatic phenotype, and also malignant transformation has been reported, ranging from 8% to 18% in some investigations [2,4,6,9]. Complete surgical resection, if possible, is the treatment of choice for most IMTs and, radiation therapy or chemotherapy has been tried in unresectable cases. In the literature review of renal IMTs, surgical excision has been the course of therapy with no evidence of recurrence or metastatic disease reported [2].

IMT can be confused with both reactive processes as well as potentially malignant neoplasm, therefore considering its existence in the kidney is of utmost clinical significance. The morphologic and immunohistochemical features of these neoplasms emphasize the difficulties in distinguishing these benign neoplasms from more aggressive spindle cell tumors of the kidney. The demonstration of ALK-1 expression in renal IMT may contribute to confirm the diagnosis of IMT in the wide spectrum of spindle cell tumors of the kidney, also its expression may give an idea about the behavior of the tumor in collaboration with morphological findings.

Competing interests

The authors declare that they have no competing interests

References

1. Dehner LP. The enigmatic inflammatory pseudotumors: The current state of our understanding, or misunderstanding. J Pathol 2000; 192: 277-279.
2. Coffin CM, Watterson J, Priest JR, Dehner LP. Extrapulmonary inflammatory myofibroblastic tumor (inflammatory pseudotumor). A clinicopathologic and immunohistochemical study of 84 cases. Am J Surg Pathol 1995; 19(8): 859-872.
3. Kapusta LR, Weiss MA, Ramsay J, Lopez-Beltran A, Srigley JR. Inflammatory myofibroblastic tumors of the kidney: a clinicopathologic and immunohistochemical study of 12 cases. Am J Surg Pathol 2003; 27(5): 658-666.
4. Coffin CM, Hornick JL, Fletcher CD. Inflammatory myofibroblastic tumor: Comparison of clinicopathologic, histologic, and immunohistochemical features including ALK expression in atypical and aggressive cases. Am J Surg Pathol 2007; 31: 509-520.
5. Griffin CA, Hawkins AL, Dvorak C, Henkle C, Ellingham T, Perlman EJ. Recurrent involvement of 2p23 in inflammatory myofibroblastic tumors. Cancer Res 1999; 59: 2776-2780.
6. Fisher C. Myofibroblastic malignancies. Adv Anat Pathol 2004; 11: 190-201.
7. Cessna MH, Zhou H, Sanger WG, Perkins SL, Tripp S, Pickering D, et al. Expression of ALK1 and p80 in inflammatory myofibroblastic tumor and its mesenchymal mimics: a study of 135 cases. Mod Pathol 2002; 15(9): 931-938.
8. Grignon DJ, Ayala AG, Ro JY, el-Naggar A, Papadopoulos NJ. Primary sarcomas of the kidney. A clinicopathologic and DNA flow cytometric study of 17 cases. Cancer 1990; 65(7): 1611-1618.
9. Hussong JW, Brown M, Perkins SL, Dehner LP, Coffin CM. Comparison of DNA ploidy, histologic, and immunohistochemical findings with clinical outcome in inflammatory myofibroblastic tumors. Mod Pathol 1999; 12: 279-286.

How to cite this article:
Başpınar Ş, Kapucuoğlu N, Çaloğlu E, Özorak A, Güzel A, Değirmenci B. Invasive Inflammatory Myofibroblastic Tumor of the Kidney with Anaplastic Lymphoma Kinase (ALK) Expression. A Case Report. J Clin Anal Med 2013;4(suppl 1): 77-80.