Primary Sjogren's Syndrome Associated with Basal Cell Carcinoma: Case Report

Bazal Hücreli Karsinom ile İlişkili Primer Sjögren Sendromu: Olgu Sunumu

Sjögren Sendromu ve Malignite / Sjogren's Syndrome and Malignancy

Tuğba Aktan Köşker[1], Şükran Erten[2], Hayriye Tatlı Doğan[3]
[1]Ankara Atatürk Eğitim ve Araştırma Hastanesi, İç Hastalıkları,
[2]Yıldırım Beyazıt Üniversitesi ve Atatürk Eğitim ve Araştırma Hastanesi, Romatoloji,
[3]Ankara Atatürk Eğitim ve Araştırma Hastanesi, Patoloji, Ankara, Türkiye

Özet

Sjögren sendromu, 'sicca semptomları' olarak bilinen ağız kuruluğu ve göz kuruluğu ile karakterize kronik otoimmün bir hastalıktır. Sjögren sendromu hastalarında, ekzokrin bezlerin lenfositik infiltrasyonu nedeniyle, karakteristik olarak nükleer ve sitoplazmik antijenler, özellikle Anti-Ro/SSA ve Anti-La/SSB pozitiftir. Primer Sjögren sendromunda sistemik komplikasyonlar gelişebilir, ki bunlardan en korkulanı non-Hodgkin lenfomadır. Biz burada, burun sırtında ülsere lezyon ile presente olan bazal hücreli karsinom ile birlikte olan Sjögren sendromu olgusundan bahsettik.

Anahtar Kelimeler

Sjögren Sendromu; Bazal Hücreli Karsinom; Malignite

Abstract

Sjogren's syndrome is a chronic autoimmune disease characterized by xerostomia and xerophthalmia, known as the 'sicca symptoms'. Patients with Sjogren's syndrome, characteristically have positive nuclear and cytoplasmic antigens, typically Anti-Ro/SSA and Anti-La/SSB because of lymphocytic infiltration of the exocrine glands. Patients with primary Sjogren's syndrome, develop systemic complications, non-Hodgkin lymphoma being the most feared of these. We describe here a case of Sjogren's syndrome with basal cell carcinoma, which presented with an ulcerated lesion on nasal dorsum.

Keywords

Sjogren's Syndrome; Basal Cell Carcinoma; Malignancy

DOI: 10.4328/JCAM.2030 Received: 22.08.2013 Accepted: 15.09.2013 Printed: 01.10.2013 J Clin Anal Med 2013;4(suppl 2): 111-3
Corresponding Author: Tuğba Aktan Köşker, Atatürk Eğitim ve Araştırma Hastanesi, İç Hastalıkları Kliniği, Bilkent Yolu 3. Km. 06800, Çankaya, Ankara, Türkiye.
T.: +90 3122912525-4804 F.:+90 3122912705 E-Mail: tubaaktan@hotmail.com

Introduction

There has been known association of rheumatic disease with malignancy for many years. Autoimmune rheumatic diseases have a higher risk of malignancy by themselves. Also, they may be associated with malignancy as paraneoplastic conditions or because of the immunosuppressant treatments. It has been shown that there is an increased risk of haematological malignancies, particularly non-Hodgkin's lymphoma and lymphoma of mucosal-associated lymphoid tissue (MALT), in patients with SS.

We describe the first case of Sjögren's syndrome with BCC in a 45-year-old woman. As with other malignancies , SS may be associated with BCC.

Case Report

A 45-year-old woman visited the outpatient department in our hospital in November 2008 presenting with artraljia, xerostomia and xerophthalmia. Her tenderness was widespread in all the joints of metacarpophalangeal, wrists, elbows and shoulders.

Serological tests revealed positive antinuclear antibody (ANA) of 1:100 (homogeneous) and elevated C-reactive protein (CRP). But other serological tests were negative for anti-Ro (SS-A), anti-La (SS-B), antibodies against DNA, ribonucleoproteins (RNP), Sm and antineutrophil cytoplasmic antibodies. All of the other blood levels were normal.

A minor salivary gland biopsy showed focal lymphocytic infiltration (an area of 4 mm2 in size, 2 and more focus, and each in focus, more than 50 lymphocyte) and an ophthalmological examination demonstrated a positive Schirmer's test of <5mm bilateral. These findings were consistent with a diagnosis of primary SS.

Low-dose methyl prednisone and hydroxychloroquine therapy were given at that time. After the symptoms were controlled, methyl prednisolone was discontinued and patient was treated with only hydroxychloroquine.

During the past 4 years, the patient started to complain about an ulcerated lesion on nasal dorsum, rapidly growing for the last 6 months. Examination revealed an ulcerated tumor, measuring about 0.5 cm in diameter with elevated borders, on the nasal dorsum. Its surface was irregular and was the same color as the skin. There were no enlarged lymph nodes on her examination and her general physical condition was stable.

Skin biopsy was performed on December 2012 and the patient was diagnosed with BCC. (Figure 1). The patient was taken up for a complete resection of the lesion, involving a 0.5 cm safe margin. The site of the defect was reconstructed using a dorsonasal flap.

Discussion

Sjögren's syndrome (SS) is an autoimmune disease of the exocrine glands, characterized by lymphocytic infiltration of salivary and lacrimal glands which causes the progressive destruction of these glands, and by the production of autoantibodies [1]. It preferentially affects the exocrine glands, causing structural harm to these organs that results in secretory dysfunction. Dryness of the eyes (xerophthalmia leading to keratoconjunctivitis sicca) and mouth (xerostomia) constitute the typical clinical components of the syndrome [2].

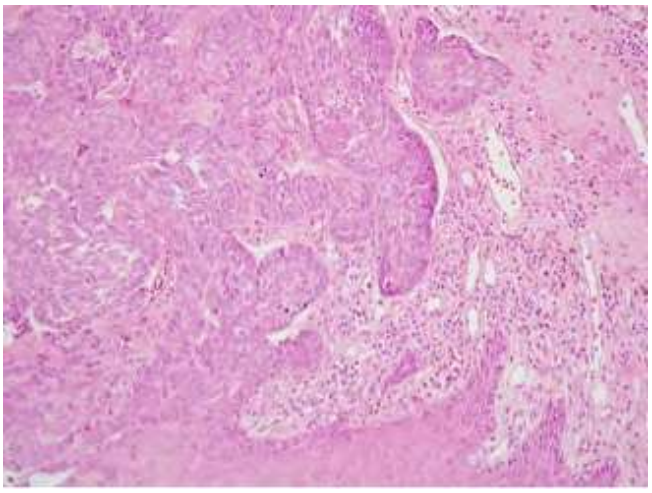

Figure 1. Basal cell carcinoma with peripheral palisading basaloid cells in nasal dorsum

Patients with SS characteristically have high levels of immunoglobulins, nuclear and cytoplasmic antigens, typically Anti-Ro/SSA and Anti-La/SSB. These autoantibodies are usually detected at the time of diagnosis and are related to early disease onset, longer disease duration and extraglandular manifestations. SS is more common in fourth and fifth decades. It commanly affects females, with 9:1 female: male ratio [3].

There has been known the association of rheumatic disease with malignancy for many years, but the explanation of this association remains unclear [4]. Several factors, including autoimmune disease itself, genetics factors, viruses (EBV) and smoking have been implicated in the pathogenesis of tumor development. On the other hand, they may be associated with malignancy as paraneoplastic conditions or because of the immunosuppressant treatments [5].

There are many studies which demonstrate that there is an increased risk of malignancies, particularly non-Hodgkin's lymphoma in patients with rheumatoid arthritis, lung cancer in patients with systemic sclerosis, who have underlying pulmonary fibrosis [4]. In patients with SS, lymphoproliferative diseases, mostly non-Hodgkin's lymphoma; more rarely, Waldenstrom macroglobulinemia, chronic lymphocytic leukemia and multiple myeloma have been reported [5].

The risk of developing non-Hodgkin's lymphoma in patients with SS is approximately 40–44 times greater than that in the general population [2]. As with other malignancies , SS may be associated with BCC. Here, we reported a case of SS with BCC, which has not been documented before.

BCC is the most common cutaneous tumor, accounting for approximately 70% of all malignant diseases of the skin [6]. BCC occurs frequently in the head-and-neck regions (%80), common sites of occurrence include the nose and eyelid. In addition, BCC exhibits a varied morphology such as adenoid, keratotic, sebaceous, basosquamous or fibroepithelial.

Its well-known etiologic factors include excessive exposure to radiation- especially ultraviolet (UV) exposure, arsenal exposure, pollution (effects of preservatives in food, artificial and natural radiation and cigarette smoke) and genetic predisposition. [7]

Immunohistochemistry, with clinical findings, helps to reach an

accurate diagnosis. Surgical excision has been considered the gold standard of treatment. For primary tumors not involving the head, surgical excision is generally curative with 5-year cure rates of more than 99% [8]. This cancer is characterized by the slow growth and it is well known that metastasis is relatively rare (less than 0.01% of cases) [6].

While the lifetime risk of basal cell carcinoma is high, for patients with metastatic disease, morbidity and mortality remain exceedingly high. The most important risk factors for metastasis are tumor size, depth, and recurrence. Primary basal cell carcinoma metastasizes usually via lymphatics. Metastasis most commonly occurs in regional lymph nodes, lungs, and bone [8].

In conclusion, rheumatic diseases have been associated with various malignancies. In patients with rheumatoid diseases, chronic inflammation is believed to be a major risk factor for the development of neoplasm [5]. Recognizing that a relationship between malignancy and rheumatic diseases is important to our future understanding of the pathogenesis. In this report, we encountered the first case of SS complicated with BCC. We recommend that patients with SS be carefully evaluated for other malignancies, and besides lymphoma, BCC should also be kept in mind. A special attention must be given to atypical symptoms, in patients with SS.

Therefore, it is necessary to monitor patients with SS for the onset of the other malignancies and prospective studies are necessary to define its prognosis.

Competing interests

The authors declare that they have no competing interests.

References

1. Fox RI, Howell FV, Bone RC, Michelson P. Primary Sjögren syndrome:Clinical and immunopathologic features. Semin Arthritis Rheum 1984;14: 77-105.
2. Lima I, Carneiro ASB, Anorim CA. Hodgkin lymphoma as a complication of primary Sjögren's syndrome. Mod Rheumatol 2008;18:200-2.
3. Soldevilla HF, Molina RM, Navarra SV. Breast lymphoma in Sjögren's syndrome complicated by acute monocular blindness. Int J Rheum Dis. 2010 May;13(2):164-70.
4. Sultan SM, Ioannou Y, Isenberg DA. Is there an association of malignancy with systemic lupus erythematosus? An analysis of 276 patients under long-term review.
Rheumatology (Oxford). 2000;39(10):1147-52.
5. Bojinca V, Janta I. Rheumatic diseases and malignancies. Maedica (Buchar). 2012;7(4):364-71.
6. Więckiewicz W, Bieniek A, Więckiewicz M, Sroczyk L. Interdisciplinary Treatment of BCC Located on the Nose - Review of Literature. Adv Clin Exp Med 2013 ;22(2):289.
7. Jetley S, Jairajpuri ZS, Rana S, Talikoti MA. Adenoid basal cell carcinoma and its mimics. Indian J Dermatol 2013;58(3):244.
8. Vu A, Laub D Jr. Metastatic Basal cell carcinoma: a case report and review of the literature. Eplasty. 2011;11:ic8.

How to cite this article:
Köşker TA, Erten Ş, Doğan HT. Primary Sjogren's Syndrome Associated with Basal Cell Carcinoma: Case Report. J Clin Anal Med 2013;4(suppl 2): 111-3.