Laparoscopy-Assisted Cystectomy: Management of a Large Ovarian Cyst with Torsion

Laparoskopik Asiste Kistektomi: Torsiyone Olmuş Büyük bir Over Kistinin Yönetimi

Laparoskopik Asiste Kistektomi / Laparoscopy-Assisted Cystectomy

Emin Üstünyurt, Müzeyyen Duran,
Bursa Şevket Yılmaz Eğitim ve Araştırma Hastanesi, Kadın Hastalıkları ve Doğum Kliniği, Bursa, Türkiye

Özet

Over kistleri kadınlarda pelvik kitlelerin en sık nedenidir. Over kistlerinin altın standart tedavisi laparoskopik cerrahi olarak düşünülmesine karşın, pek çok büyük over kisti, teknik güçlükler nedeni ile laparotomi ile tedavi edilmeye devam etmektedir. Bu tür olguların yönetiminde laparoskopik asiste kistektomi alternatif bir operasyondur. Bu yazıda 21 yaşında bakire bir hastada torsiyone olmuş büyük bir over kisti olgusu sunulmaktadır. Bu olguda intraoperatif bir komplikasyon olmadan laparoskopik asiste kistektomi gerçekleştirimiştir. Postoperatif dönem sorunsuz idi. Patoloji benign seröz kistadenom olarak rapor edildi. 6 aylık takipte hasta asemptomatik olmaya devam etti ve sonografide hastalığa ilişkin bir rekürrens gözlenmedi. Laparoskopik asiste kistektomi büyük adneksiyal kistler için etkin ve güvenli bir prosedürdür.

Anahtar Kelimeler

Laparoskopi; Laparoskopik Asiste Cerrahi; Büyük Over Kisti

Abstract

Ovarian cysts are the most common cause of pelvic masses in women. Although laparoscopic surgery is considered the gold standard treatment for ovarian cysts, most of the large ovarian cysts continue to be treated by laparotomy due to technical difficulties. Laparoscopic-assisted cystectomy is an alternative operation type for managing such cases. A case of large ovarian cyst with adnexal torsion in a 21-year-old virgin patient is presented in this report. In this case laparoscopic-assisted cystectomy was performed without intraoperatif complication. Postoperative course was uneventful. Pathology revealed a benign serous cystadenoma. At 6 months follow up, she continued to be asymptomatic, and sonography showed no recurrence of her disease. Laparoscopic-assisted cystectomy is a safe and effective procedure for large adnexal cysts.

Keywords

Laparoscopy; Laparoscopy-Assisted Surgery; Large Ovarian Cyst

DOI: 10.4328/JCAM.2040 Received: 30.08.2013 Accepted: 28.09.2013 Printed: 01.10.2013 J Clin Anal Med 2013;4(suppl 2): 120-2
Corresponding Author: Emin Üstünyurt, Saygınkent Sitesi B-Blok No=41, Nilüfer, 16120, Bursa, Türkiye.
T.: +905057571874 E-Mail: dreminustunyurt@yahoo.com.tr

Introduction

Ovarian cysts are the most common cause of pelvic masses in women, and in the majority of the cases, women are in their fertile age [1]. Today, the surgical treatment has become more conservative and less invasive; hence, a laparoscopic approach in the presence of benign cysts has become a gold standard [2]. Most of the large ovarian cysts, however, continue to be treated by laparotomy because of large tumor size, suspicion of malignancy or inadequate surgeon experience. Laparoscopic-assisted cystectomy is an alternative operation type for managing such cases [3].

In this report we present a 14 cm serous cystadenoma managed by laparoscopic-assisted cystectomy

Case Report

A 21- year-old virgin patient presented with severe right- sided pelvic pain. Abdominal sonography revealed a 14 × 8 centimeters large cystic lesion occupying nearly the entire right side of the abdomen. There was no sign of calcification or papillary projection. A moderate amount of free intraperitoneal fluid was present in the cul-de-sac. Sonographic findings were suggestive of adnexal torsion. The levels of serum tumor markers were normal.

Both laboratory studies and imaging findings supported the benign nature of the cystic mass. Assuming the cyst to be benign in nature, laparoscopic excision was planned. Two ports with the diameter of 10 mm were used. After creating pneumoperitoneum by Verres needle we introduced a 10 mm trocar in to the abdominal cavity from the lower border of the umbilical fold. A second 10 mm trocar was inserted at the mid-line 2 cm above the pubic margin. The cyst wall was punctured and drained by suction device through this supra-pubic entry. When the cyst became flaccid, the puncture site on the cyst was grasped with forceps. After visualization of pelvic structures completely, detorsion of the twisted adnexa was performed. Later the cyst was pulled out under direct telescopic vision (Figure 1). At that time supra-pubic incision was widened to 3 cm. Extracorporeal cystectomy was performed successfully (Figure 2). After achieving adequate hemostasis, the edges of ovary tissue were approximated by 3-0 vicryl and placed into its original site. The estimated blood loss was 50 ml. The operative time was 15 minutes. Postoperative course was uneventful. The patient was discharged on the postoperative day 2 without any complications. Pathology revealed a benign serous cystadenoma. At 6 months follow up, she continued to be asymptomatic, and sonography showed no recurrence of her disease.

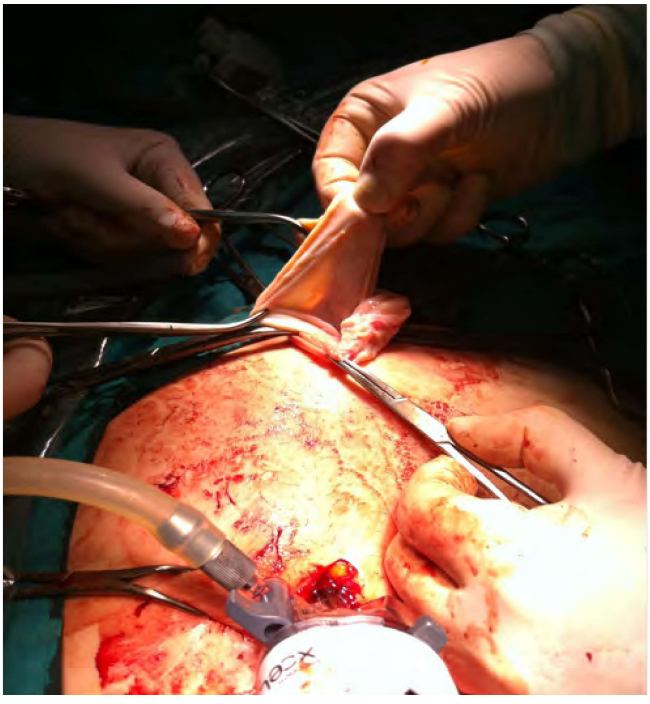

Figure 1. Extirpation of cyst capsule



Figure 2. Cyst capsule

Discussion

In the present case, the patient is a virgin and both aesthetic and fertility results of the operation are important issues. Although laparoscopy is commonly chosen in such cases, sometimes laparotomy is preferred because of large tumor size, suspicion of malignancy or inadequate surgeon experience.

The extremely large ovarian cyst presents a major challenge for the endoscopic surgeon. Increased probability of malignancy, technical problems related to the removal of such cysts and perioperative problems related to cardiorespiratory functional changes may complicate surgery for such cysts [4]. Some surgeons limited laparoscopic surgery to ovarian cyst of size less than 10 cm [5-6]. For apparently benign, extremely large ovarian cysts; only few surgeons advocate laparoscopic management [7,8]. Salem [8] reported 15 cases of large benign ovarian cysts reaching above the level of the umbilicus, which were managed laparoscopically. Sagiv et al. [9] reported the outcomes of 21 patients with extremely large ovarian cysts who were managed laparoscopically. They concluded that with proper patient selection the size of an ovarian cyst is not necessarily a contradic-

tion for laparoscopic surgery.

During the laparoscopic excision of large ovarian cysts, sometimes the cyst wall cannot be removed completely without damaging the normal ovarian tissue leading to inadequate cure rates. Additionally satisfactory hemostasis could not be managed easily thus more than required tissue is coagulated resulting more functional tissue lost from the ovary.

Laparoscopic assisted surgery is an alternative procedure for large adnexal cysts. Panici et al. [10] compared laparoscopy with laparoscopically guided minilaparotomy for large adnexal masses. They concluded that laparoscopically guided minilaparotomy should be considered in women desiring a minimally invasive strategy for large cysts. Gocmen et al. [11] reported the surgical outcome of 46 women underwent laparoscopy-assisted surgery for large adnexal cysts. The authors suggested that laparoscopy-assisted surgery is feasible and safe for women with large benign adnexal cysts and results in a short surgery time.

In contrast to laparoscopy, complete extirpation of the cyst wall and satisfactory hemostasis could be managed easily by laparoscopic assisted cystectomy. In this procedure the operative time is shorter which is crucial for patients with cardiorespiratory problems and the cosmetic results of the operation is comparable with laparoscopy.

In conclusion laparoscopic-assisted cystectomy is a safe and effective procedure for large adnexal cysts and possibly be superior to the laparoscopy in terms of preservation of normal ovarian tissue.

Competing interests

The authors declare that they have no competing interests.

References

1.Pavlik EJ, Ueland FR, Miller RW, Ubellacker JM, Desimone CP, Elder J, Hoff J, Baldwin L, Kryscio RJ, van Nagell JR Jr. Frequency and disposition of ovarian abnormalities followed with serial transvaginal ultrasonography. Obstet Gynecol 2013; 122:210-7.

2. Chapron C, Dubuisson JB, Fritel X, Rambaud D. Diagnosis and management of organic ovarian cysts: indications and procedures for laparoscopy. Hum Reprod Update 1996; 2:435-46.

3. Eltabbakh GH, Charboneau AM, Eltabbakh NG. Laparoscopic surgery for large benign ovarian cysts. Gynecol Oncol 2008; 108:72-6.

4.Nagele F, Magos A. Combined ultrasonographically guided drainage and laparoscopic excision of a large ovarian cyst. Am J Obstet Gynecol 1996; 175:1377-8.

5. Pittaway DE, Takacs P, Bauguess P. Laparoscopic adnexectomy: A comparison with laparotomy. Am J Obstet Gynecol 1994; 171:385-91.

6. Nezhat F, Nezhat C, Welander CE, Benigno B. Four ovarian cancers diagnosed during laparoscopic management of 1011 women with adnexal masses. Am J Obstet Gynecol 1992; 167:790-6.

7. Lin P, Falcone T, Tulandi T. Excision of ovarian dermoid cyst by laparoscopy and by laparotomy. Am J Obstet Gynecol 1995; 173:769-71.

8. Salem HA Laparoscopic excision of large ovarian cysts. J Obstet Gynaecol Res 2002; 28:290-4.

9. Sagiv R, Golan A, Glezerman M. Laparoscopic management of extremely large ovarian cysts. Obstet Gynecol 2005; 105: 1319-22.

10. Panici PB, Palaia I, Bellati F, Pernice M, Angioli R, Muzii L. Laparoscopy compared with laparoscopically guided minilaparotomy for large adnexal masses: a randomized controlled trial. Obstet Gynecol 2007; 110: 241-8.

11. Göçmen A, Atak T, Uçar M, Sanlikal F. Laparoscopy-assisted cystectomy for large adnexal cysts. Arch Gynecol Obstet 2009; 279: 17-22.

How to cite this article:

Üstünyurt E, Duran M. Laparoscopy-Assisted Cystectomy: Management of a Large Ovarian Cyst with Torsion. J Clin Anal Med 2015; DOI: 10.4328/JCAM.2040.