Endoscopic Removal of the Tooth Brush Which Was Impacted in Stomach: Case Report

Mideye İmpakte Olmuş Diş Fırçasının Endoskopik Olarak Çıkartılması: Olgu Sunumu

Yabancı Cisim Yutulması / Swallowed Foreign Body

Fevzi Cengiz[1], Erkan Oymacı[2], Baha Zengel[1], Nazif Erkan[1], Mehmet Yıldırım[1]
[1]Genel Cerrahi Bölümü, [2]Gastroenteroloji Cerrahi Bölümü,
İzmir Eğitim ve Araştırma Hastanesi, İzmir, Türkiye

Bu çalışma Ekim 2013 Bodrum – Muğla 11. Ulusal Endoskopik Laparoskopik Cerrahi Kongresi'nde poster olarak sunulmuştur.

Özet

Özet: Kaza ile yutulan uzun, rijit ve keskin yabancı cisimler gastrointestinal sistemde impakte olarak, perforasyon veya tıkanma gibi komplikasyonlara neden olabilmektedir. Nadiren izlenen bu olgularda madde bağımlılığı, şizofreni veya anoreksiya gibi ciddi sağlık problemleri sorgulanmalıdır. Bu tarz cisimlerin cerrahi veya endoskopik olarak en kısa sürede çıkartılması gereklidir. 23 yaşında erkek hasta acil servise diş fırçası yutma yakınması ile başvurmuştur. Yazımızda kaza ile yutulan diş fırcasının, altı saat sonra impakte olduğu mideden sedoanaljezi altında endoskopik yöntem ile çıkarılması sunulmuştur.

Anahtar Kelimeler

Endoskopi; Diş Fırçası; Araştırma; Tedavi

Abstract

Long, rigid and sharp foreign objects which are swallowed by accident can be impacted in gastrointestinal system causing complications like obstruction or perforation. Serious health problems like anorexia or schizophrenia should be considered in those cases which are seen rarely. The foreign objects which were impacted in gastrointestinal system must be removed immediately either surgically or endoscopically. 23 year old male patient arrived at emergency with the complaint of swallowing a toothbrush. In this report we present endoscopic removal of a tooth brush under sedation and using analgesics six hours after it was swallowed accidentally and impacted in stomach

Keywords

Endoscopy; Toothbrush; Investigation; Management

DOI: 10.4328/JCAM.2113 Received: 24.10.2013 Accepted: 12.11.2013 Printed: 01.10.2013 J Clin Anal Med 2013;4(suppl 2): 172-4
Corresponding Author: Erkan Oymacı, Çankaya Mah. 131 Sok. No:61 Kat:1 İzmir, 35280, Türkiye.
T.: +905052692741 F.: +90 2322614444 E-Mail: erkan.oymaci@hotmail.com

Introduction

Esophageal foreign body impaction often requires urgent evaluation and treatment and the majority of patients presented to the emergency department [1]. The difficult points in endoscopic management were perforating esophageal foreign bodies, impacted esophageal foreign bodies with sharp points, and those with impaction for more than 24 hours [2]. Swallowed foreign objects like toothpicks, meat or fish bones, screws, coin, metal clips, teeth, dentures and spoon handle were reported [3, 4]. Etiological factors are curiosity in children, loss in visual accuracy, mental illness, alcohol and drug addiction, dentures and eating too fast in adults [3, 5]. Even if the swallowed foreign objects pass through the alimentation tract without any problems and without morbidity, outpatient follow up is needed. Long, rigid and sharp foreign objects have high risk of causing complications at the sharp angled points of gastrointestinal system. In those cases the foreign object must immediately be removed endoscopically or surgically. Our report presents the case of endoscopic removal of an19 cm toothbrush successfully which was swallowed accidentally.

Case Report

23 year old male patient arrived at emergency with the complaint of swallowing a toothbrush. The patient told that he swallowed the toothbrush accidentally while brushing his teeth and no alcohol or drug use were present. There is no history of medical problems like psychiatric illness, mental retardation and alcoholism or drug addiction during psychiatric consultation. Results of the physical examination of the patient were normal. Laboratory results revealed that glucose was 103 mg/dl, hemoglobin level was 13.4 gr/dL, hematocrit level was 40.9, white blood cell was 5.0 x 109/L and amylase level was 124 u/L. Typical shape of toothbrush was clearly visualized in standing posture plain abdominal x-ray (Figure 1). Upon the arrival of the patient, we performed endoscopic intervention by applying local anesthetics on oropharingeal mucosa in addition to sedatives and analgesics administration. Since the stomach was full clear visualization was not possible and the operation ended without taking the toothbrush out. After six hours of fasting endoscopic intervention was repeated by an experienced endoscopic surgical team using local anesthetics under sedation and administering analgesics. During the endoscopic procedure we observed that the brush part of the toothbrush entered the pyloric hole and the grip was impacted in corpus of the stomach (Figure 2). Since both ends of the toothbrush were not reachable, the tip of the endoscope was passed through the two fixed points of toothbrush in retroflexed position, and then the grip of the toothbrush was released by using the tip of the endoscope making it recognizable at cardioesophageal level (Figure 3). The toothbrush which was hold by its grip with the help of snare was pulled back by endoscope and is taken out successfully. The procedure ended after endoscopically controlling esophagus, stomach and duodenum for any possible damage. The removed toothbrush was19cm long (Figure 4). The patient was discharged after two hours of observation in good physical condition and without any complications.

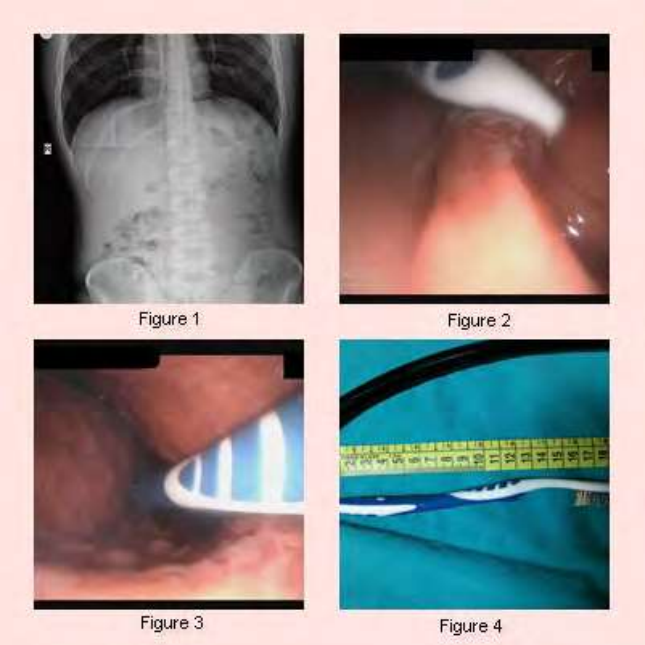

Figure 1. Plain X-ray of chest and abdomen six hours later.
Figure 2. The endoscopic view of the impacted toothbrush location in the stomach after six hours.
Figure 3. Liberalized toothbrush after maneuvering with the shaft of endoscope.
Figure 4. Outside view and the measurement of the removed toothbrush.

Discussion

Swallowing foreign objects is a frequently seen case in emergency departments. Swallowed objects rarely cause impaction, perforation or obstruction in gastrointestinal system. The difficult points in endoscopic management were perforating esophageal foreign bodies, impacted esophageal foreign bodies with sharp points, and those with impaction for more than 24 hours. Impacted esophageal foreign bodies should be treated as early as possible, and their endoscopic management is safe and effective [2]. Inflammation, abscess, peritonitis, obstruction, fistula, mortality and morbidity as a result of hemorrhage may occur in relation to the shape of the swallowed object. In addition to those, on rare occasions migration of the foreign objects to the neighboring organs is seen [3, 5, 6].

Swallowed tooth brush is a rare occasion and 34 cases have been reported in the literature till today. As in our case, lack of additional health problems of the patient, early diagnosis and intervention, endoscopically removal of toothbrush is possible without facing any potential complications. However, in some cases problems like mental retardation, schizophrenia and anorexia among young women cause delays in diagnosis and lead to complications and as a result surgical intervention may be needed [5, 7]. Since duodenum is fixed to retro peritoneum and anatomically shaped as C-loop, it is a trap for long and sharp objects. In our case, although the stomach is emptied after 6 hours, it was found that brush part of the toothbrush was impacted to stomach by attaching to pylori without reaching to the intestines. It is obvious that the objects which impacted to this area will cause pressure necrosis and then perforation, fistula or abscess. Therefore, removing the large gastric foreign objects longer than 6 cm without waiting for a long time is suggested [3]. There is no reported case of swallowing toothbrush in the literature which passes through gastrointestinal system spontaneously. For this reason, efforts should be made

without delay for removing long, rigid and sharp objects from gastrointestinal system. Endoscopic removal of the toothbrush for the first time was carried out by Ertan et al. in 1983 [8]. To be able to complete the endoscopic procedure successfully it is needed to determine the right time, strategy and an experienced team should be recruited. There are unsuccessful endoscopic procedures due to the size and shape of the toothbrush [9]. If the toothbrush has become impacted upside down in the esophagus, it is wise to push the toothbrush into the stomach first, and pull it out with a snare after correcting the direction of toothbrush [10]. It would be more difficult to bend the handle of toothbrush than to bend the head of toothbrush. Also esophagus complications have been reported during extraction of the foreign objects [4]. Therefore during extraction, it is important that the longitudinal axis of toothbrush is parallel to the esophagus. While pulling the object out extreme care should be taken passing gastroesophageal junction, otherwise, mucosal damage or penetration injury can occur. As foreign object reaches the oropharynx, maneuver in this area is the second most important stage of the procedure. Taking the patient's head to extension position, toothbrush must be pulled out by reaching with endoscopist's hand to avoid injury at oropharynx. In our case, at this stage by taking the patient's head to extension position, removing procedure was carried out without any need for manual maneuver. The shape of foreign object and the medical status of the patient will specify the type of intervention and the follow-up procedure.

As a result, removing of large, rigid and sharp objects from the gastrointestinal system within the shortest time, without causing morbidity and mortality is essential. While removing these kind of objects without the need for surgery, proper execution of the procedures by a team who are experienced in endoscopic intervention increases the chances of success.

Competing Interests

The authors declare that they have no competing interests.

References

1. Crockett SD, Sperry SLW, Mille CB, Shaheen NJ, Dellon ES. Emergency care of esophageal foreign body impactions: timing, treatment modalities, and resource utilization. Diseases of the Esophagus 2013;26:105–112.
2. Chen T, Wu HF, Shi Q, Zhou PH, Chen SY, Xu MD et al. Endoscopic management of impacted esophageal foreign bodies. Diseases of the Esophagus 2012 Sep 13. doi: 10.1111/j.1442-2050.2012.01401.
3. Chao HH, Chao TC. Perforation of the duodenum by an ingested toothbrush. World J Gastroenterol 2008;14:4410-2.
4. Mosca S, Manes G, Martino R, Amitrano L, Bottino V, Bove A et al. Endoscopic management of foreign bodies in the upper gastrointestinal tract: report on a series of 414 adult patients. Endoscopy 2001;33:692–696.
5. Lee MR, Hwang Y, Kim JH. A case of colohepatic penetration by a swallowed toothbrush. World J Gastroenterol 2006;12:2464-5.
6. Eisen GM, Baron TH, Dominitz JA, Faigel DO, Goldstein JL, Johanson JF et al. Guideline for the management of ingested foreign bodies. Gastrointest Endosc 2002;55:802–806.
7. Faust J, Schreiner O. A swallowed toothbrush. Lancet 2001;357:1012.
8. Ertan A, Kedia SM, Agrawal NM, Akdamar K. Endoscopic removal of a toothbrush. Gastrointest Endosc 1983;29:144-145.
9. Wishner JD, Rogers AM. Laparoscopic removal of a swallowed toothbrush. Surg Endosc 1997;11:472-3.
10. Lu XL, Cao HL, Qian KD. Endoscopic removal of an accidentally swallowed toothbrush. Inter Med 2008;47:1797-1798.

How to cite this article:
Cengiz F, Oymacı E, Zengel B, Erkan N, Yıldırım M. Endoscopic Removal of the Tooth Brush Which Was Impacted in Stomach: Case Report. J Clin Anal Med 2013;4(suppl 2): 172-4.