Diffuse Myocardial Tc99m HDP Uptake in a Hemodialysis Patient: A Rare Case

Hemodiyalize Giren Hastada Diffüz Miyokardiyal Tc99m HDP Tutulumu: Nadir Bir Olgu

Hemodiyalize Giren Hastada Miyokardiyal Tc99m HDP Tutulumu / Myocardial Tc99m HDP Uptake in a Hemodialysis Patient

Murat Sadıç, Hasan İkbal Atılgan, Gökhan Koca, Koray Demirel, Meliha Korkmaz
Ministry of Health Ankara Training and Research Hospital, Department of Nuclear Medicine, Ankara, Turkey

Özet

Kemik sintigrafisinde kemik patolojilerinin yanı sıra yumuşak dokuda da tutulum izlenebilmektedir. Neoplastik, hormonal, inflamatuar, iskemik, travmatik ve artefakta bağlı olarak anormal yumuşak doku tutulumları olabilmektedir. Bu olguda kronik böbrek yetmezliği nedeniyle hemodiyalize giren hastadaki kemik sintigrafisinde nadir gözlenen kardiyak kalsinozise bağlı miyokardiyal Teknesyum99m hidroksimetilen difosfonat (Tc99m HDP) tutulumunu sunulmaktadır.

Anahtar Kelimeler

Hemodiyaliz; Teknesyum99m Hidroksimetilen Difosfonat (Tc99m HDP); Kardiyak Kalsinozis; Metastatik Kalsifikasyon

Abstract

In addition to bone pathologies, soft tissue uptake may also be seen with bone scintigraphy. Abnormal soft tissue uptake may be due to neoplasia, hormonal changes, inflammation, ischemia, trauma and artifacts. A case is here presented of cardiac calcinosis detected incidentally by Technetium99m hydroxymethylene diphosphonate (Tc99m HDP) in a patient undergoing hemodialysis for chronic renal failure.

Keywords

Hemodialysis; Technetium99m Hydroxymethylene Diphosphonate (Tc99m HDP); Cardiac Calcinosis; Metastatic Calcification

DOI: 10.4328/JCAM.2186 Received: 25.11.2013 Accepted: 22.12.2013 Printed: 01.10.2013 J Clin Anal Med 2013;4(suppl 2): 211-3
Corresponding Author: Murat Sadıc, Department of Nuclear Medicine, Ministry of Health, Ankara Training and Research Hospital, 06340, Ankara, Turkey.
T.: +90 3125953608 F.: +90 3125953856 E-Mail: mdmuratsadic@gmail.com

Introduction

Technetium99m hydroxymethylene diphosphonate (Tc99m HDP) bone scintigraphy has high sensitivity but low specificity for the imaging of the skeletal system [1]. Abnormal soft tissue uptake is a rare finding with an incidence of 2% [2]. It may be due to neoplasia, hormonal changes, inflammatory, ischemic, traumatic and artifact. The mechanism of increased extraosseous uptake of Tc99m HDP is thought to be due to an increase in extracellular fluid, regional vascularity, permeability and tissue calcium concentration [3]. Metastatic calcification and heterotopic bone formations are the most common causes. In the case reported here, incidentally detected cardiac calcinosis in a patient with chronic kidney failure undergoing hemodialysis is presented.

Case Report

A 65-year old female patient who had been undergoing hemodialysis due to chronic kidney failure for two years was admitted to hospital with back pain that had been ongoing for one month. A lumbar spine radiograph was taken and a height loss of the L5 vertebra was observed. Osteomyelitis-like infectious etiologies were considered in L5 vertebra and L4-5 disc space from magnetic resonance imaging (MRI). The patient was referred to the Nuclear Medicine Department for three phase bone scintigraphy with a pre-diagnosis of osteomyelitis.

The biochemical parameters of the patient were as follows: BUN: 101 mg/dL (N: 17-43 mg/dL) and creatinine: 5.8 mg/dL (N: 0.81-1.44 mg/dL), Ca: 9.3 mg/dL (N: 8.8-10.6 mg/dL), corrected Ca: 9.94, P: 6.5 mg/dL (N: 2.5-3.5 mg/dL), Mg: 0.8 mmol/L (N: 0.73-1.06 mmol/L), PTH: 129 pg/ml (N: 10-60 pg/ml), Na 137 mmol/L (N: 135-150 mmol/L), K: 5.5 mmol/L (N: 3.5-5 mmol/L). Serum CPK, ALT, AST, LDH levels were within normal limits.

The left atrium was dilated and calcification focus was not detected on the chest X-Ray. There was no pathology in the ECG. Left ventricule hypertrophy and left atrial dilatation were detected with echocardiography.

Informed consent was obtained from the patient and 740 mBq (20 mCi) Tc99m HDP was injected. After a 10-minute waiting period following the injection, early whole body blood pool images were taken. Anterior and posterior late whole body and static images were taken two hours later. Hyperemia and increased activity accumulation were observed in the L5 vertebra, left superior pubic ramus and superior pubic region in the early and late images [Figure 1]. Diffuse myocardial uptake of Tc99m HDP was also detected in the late images [Figure 1c and 2a]. There was no pathological activity accumulation in other soft and visceral tissues. The activity accumulation had disappeared in the 24-hour images [Figure 2b]. No abnormality was detected in the quality control testing and there was no unexpected abnormal finding in other patients, which excluded the possibility of unattached radiopharmaceuticals.

Discussion

Technetium99m hydroxymethylene diphosphonate is used for the evaluation of skeletal system pathologies. Soft tissue uptake is a rare finding with an incidence of 2% [2]. Extra-skeletal uptake of bone radiopharmaceuticals provides important information to identify the specific clinical situations and achieve

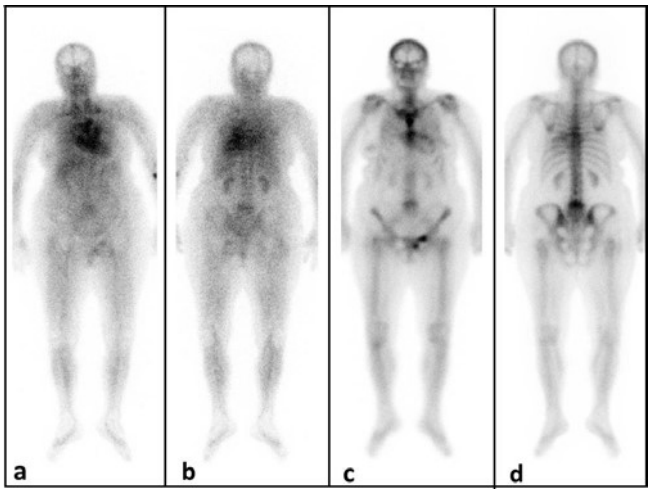

Figure 1. Myocardial 99mTc-HDP accumulation in anterior (A) and posterior (B) early whole body blood pool images, anterior (C) and posterior (D) late whole body images.

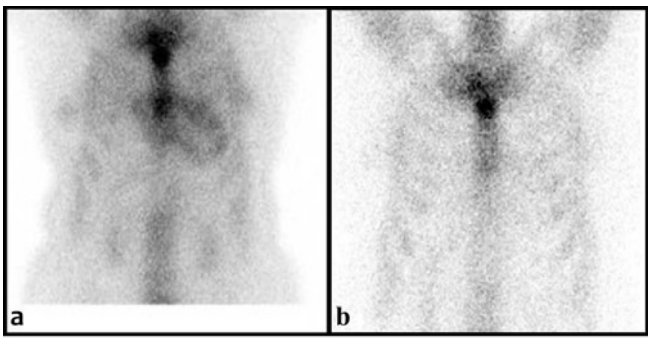

Figure 2. Diffuse myocardial uptake of Tc99m- HDP was seen in 2-hour anterior statik image (A) the cardiac accumulation disappeared in 24-hour anterior statik image (B).

the correct differential diagnosis [4]. Many disease and causes have been reported for this unexpected pattern although the mechanism of uptake has not yet been fully elucidated. The most common accepted mechanism is the chemoabsorption of bone radiopharmaceutical to hydroxiapatite crystals and calcium salts [5]. Cardiac calcinosis, which includes calcified heart valve disease, metastatic calcification, hemodialysis cardiomyopathy and aortic calcification in long term hemodialysis patients, is a common and life threatening complication. In addition, this phenomenon is closely associated with atherosclerotic cardiovascular disease and venous thromboembolism. Therefore, early diagnosis and treatment of cardiac calcinosis is life saving. Eguchi et al mentioned that bone scintigraphy is a non-invasive method for the diagnosis and treatment of cardiac calcinosis [6]. Isolated myocardial uptake of bone radiopharmaceuticals is rare in hemodialysis patients and is usually accompanied by soft tissue and other visceral organ uptake [7, 8]. Isolated and/or diffuse myocardial uptake can be seen in other diseases and situations such as multiple myeloma, amyloidosis, primary/secondary hypercalcemia, primary/secondary hyperparathyroidism, metastatic calcification, uremic pericarditis, malignant pericardial effusion/calcification, myocardial contusion and cardiac valve calcification [9].

To the best of our knowledge, there is no data about the disappearance of the myocardial uptake in the 24th hour. Myocardial uptake has been reported to be accompanied by soft tissue and visceral organ involvement in similar cases in literature [6-10]. In the current case, while diffuse myocardial uptake of Tc99m

HDP was seen in 2-hour anterior statik image [Figure 2a] the cardiac accumulation disappeared in 24-hour anterior statik image [Figure 2b] and there was no other soft tissue uptake. Other causes of diffuse cardiac uptake were excluded with the medical history, laboratory and echocardiographic findings. The diffuse myocardial uptake was considered to be cardiac calcinosis as has been reported in similar cases in literature.

Competing interests

The authors declare that they have no competing interests.

References

1. Kaye J, Hayward M. Soft tissue uptake on 99mTc methylene diphosphonate bone scan imaging: pictorial review. Australas Radiol. 2002;46:13-21.
2. Gentili A, Miron SD, Bellon EM. Nonosseous accumulation of bone-seeking radiopharmaceuticals. Review. Radiographics. 1990;10:871-81.
3. Peller PJ, Ho VB, Kransdorf MJ. Extraosseous Tc-99m MDP uptake: a pathophysiologic approach. Radiographics. 1993;13:715-34.
4. Tuncel M, Erbas B, Mahmoudian B. Gamut: soft tissue uptake of bone radiopharmaceuticals. Semin Nucl Med. 2003;33:334-7.
5. Janowitz WR, Serafini AD. Intense myocardial uptake of 99mTc-diphosphonate in a uremic patient with secondary hyperparathyroidism and pericarditis: case report. J Nucl Med. 1976;17:896-8.
6. Eguchi M, Tsuchihashi K, Takizawa H, Nakahara N, Hagiwara M, Ohnishi H, et al. Detection of cardiac calcinosis in hemodialysis patients by whole-body scintigraphy with 99m-technetium methylene diphosphonate. Am J Nephrol. 2000;20:278-82.
7. Braga FJ, Miranda JR, Lucca LJ, Garcia TM, Ferraz AS. Heart and lung accumulation of Tc-99m MDP with normal radiographs in patients undergoing hemodialysis. Clin Nucl Med. 2000;25:377-8.
8. Soni S, Leslie WD. Bone scan findings in metastatic calcification from calciphylaxis. Clin Nucl Med. 2008;33:502-4.
9. Demirel K, Sadic M, Korkmaz M, Comak A, Atilgan HI, Koca G. "Diffuse Myocardial Uptake of 99mTc-HDP in Multiple Myeloma." Nuclear Medicine and Molecular Imaging 2013;47:208–11.
10. Sahin A, Seven B, Yildirim M, Varoglu E. Heart and soft-tissue uptake of Tc-99m MDP in a hemodialysis patient. Clin Nucl Med. 2004;29:854-5.

How to cite this article:
Sadıç M, Atılgan Hİ, Koca G, Demirel K, Korkmaz M. Diffuse Myocardial Tc99m HDP Uptake in a Hemodialysis Patient: A Rare Case. J Clin Anal Med 2013;4(suppl 2): 211-3.