A Case Report of Anterior Ethmoid Mucocele Showing Intraorbital Extension

İntraorbital Uzanım Gösteren Anterior Etmoid Mukoselli Bir Olgu Sunumu

Türkçe ve İngilizce kısa başlık
Lütfen secretary@jcam.com.tr gönderiniz

Harun Arslan[1], Metin Saylık[2]
[1]Radyoloji Bölümü, [2]Göz Hastalıkları Bölümü, Van Bölge Eğitim ve Araştırma Hastanesi, Van. Türkiye

Özet

Mukoseller, paranazal sinüslerin kronik kistik lezyonlarıdır. İyi huylu olmalarına rağmen etraf dokularda kemik destrüksiyonuna ve basıya neden olabilen expansil iezyonlardır.Orbital bölgeye yayılım yapmış frontoetmoid mukoselli hastalarda yaygın başvuru şikayetleri gözde dışa itilme, diplopi ve başağrısıdır. Burada, lamina papriseada destrüksiyona yol açarak orbita içine yayılım göstermiş frontoetmoidol mukoselli bir olguyu klinik ve radyolojik bulguları ve aynı zamanda literatür incelemesi ile sunduk.

Anahtar Kelimeler

Mukosel; Etmoidal Sinüs; Bilgisayarlı Tomografi

Abstract

Mucoceles are chronic cystic lesions of the paranasal sinuses. Although they are benign, they are expansile lesions which can lead to bony destruction and compression of surrounding structures. Common complaints for admission to hospital in patients with ethmoid mucocele extending the orbital region are proptosis, diplopia and headache. Herein, we presented a case of ethmoid mucocele which extended into intraorbital region through by destruction of the lamina papyracea with its clinical and radiological findings and also with a review of the literature.

Keywords

Mucocele; Ethmoid Sinus; Computed Tomography

DOI: 10.4328/JCAM.2229 Received: 11.12.2013 Accepted: 31.12.2013 Printed: 01.11.2013 J Clin Anal Med 2013;4(suppl 3): 237-9
Corresponding Author: Harun Arslan, Van Bölge Eğitim ve Araştırma Hastanesi Radyoloji Bölümü, Van Türkiye.
E-Mail: harun.ars75@gmail.com

Introduction

Mucoceles are slow-growing cystic lesions covered with respiratory epithelium and occur as a result of clogging of paranasal sinus ostia. They occur most frequently in the frontal sinus and less frequently in the ethmoid, maxillary and sphenoid sinuses [1-2]. Unless infected they are filled with clear yellowish mucoid secretion. Although mucoceles are benign, over time, they can show extension into the orbit and cranium by pushing the surrounding bony structures with the pressure which they cause and/or by destroying bony tissues with the effect of prostanglandin E2 and collagenases enzymes secreted from inflamatory cells [1-3].For this reason,untreated mucoceles may be an important cause of morbidity and mortality according to their locations. In this paper, we aimed to present radiological and ophthalmological findings of a mucocele case which is originated from anterior ethmoidal region and extended into the intraorbital region with a review of literature.

Case Report

35 year old female patient admitted to the eye clinic with increasing complaints of diplopia, proptosis of the left eye, left sided hedache, obstruction and intermittent discharge in the the left nasal passage within the last month. Visiual acuity was 100/100 in both eyes. Dipliopia was present in the Worth's four dot test. Intraocular pressure and fundus examinations were normal. The left eye was proptotic and deviated to outward and also downward (figure 1) and also there was minimal upwards and inwards eye movement restriction. Laboratory tests for thyroid function were normal and orbital Magnetic Resonance Imaging (MRI) and paranasal sinuses Computed Tomography (CT) showed a cystic mass originated from paranasal region and extended into the orbital region.

In the nasal endoscopic examination, a cystic lesion covered with normal mucosa occupying the left middle meatus was observed. There was no evidence of active infection in the nasal mucosa. The patient had no history of trauma or nasal surgery. Axial CT and orbital MRI showed a cystic lesion extending from ethmoidal sinus into into the ethmoid cells and then by destroying lamina papyracea extended into orbit.This dense signaling cystic mass in the orbit located extraconally and was indenting the left medial rectus and superior oblique muscle. It was observed as hyperintense in T1WI slice, hyperintense in T2WI slice and slightly peripheral contrast enhancement was seen after administration of intravenous contrast material.(figure2, 3,4)..

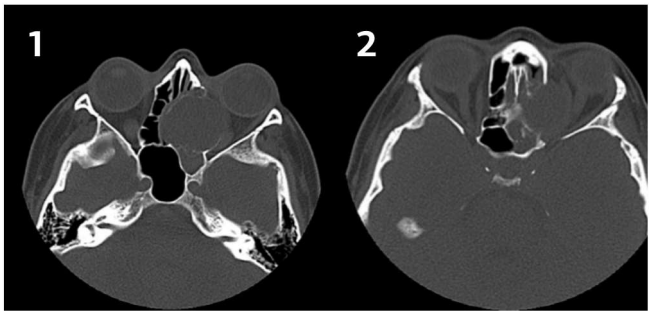

Figure1-2. Axial CT, anterior ethmoid sinus mucocele

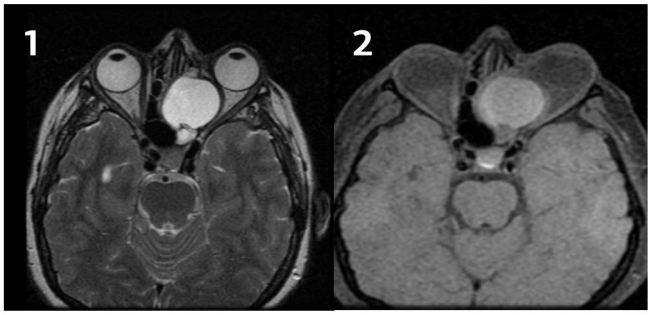

Figure 3,4. Axial T1-T2 WI Hyperintense cystic mass(anterior ethmoid sinus mucocele)

Discussion

Mucoceles occur as a result of blockage of the sinus ostia with the accumulation of secretions. Although there is often no apparent cause, a history of chronic sinusitis, allergic and other mucosal inflammatory lesions, previous surgery and trauma have been present in some patients.It is often seen as equal in both sexes between the ages of 40-70[4]. It is rare in the pediatric age group and if it is detected, cystic fibrosis should be investigated. Increased mucus secretion and accumulation with time can lead to compression on the neighboring bone tissue, occurence of inflammation between two surfaces, and ultimately can result in the growth of mucocele into the the space in the adjacent tissues at the area of least resistance. Chronic inflammation and increased osteoclastic and osteoblastic activity at the surrounding bone tissue is reported in histopathological researches[5,6]. Therefore,while a mucocele of the frontal sinus can extend from the roof of the frontal sinus into the intracranial location, frontoethmoid sinus mucocele can show growth into the orbita by destructing the lamina papyracea like as our case. Clinical picture in patients varies according to the location of the mucocele. In orbital involvement, patients may present with proptosis,visual loss ,diplopia or headache. The most important complications are visual loss, diplopia and orbital mucopyocele. Mucocele extending into the brain from frontal sinus can cause subdural empyema, epidural or brain abscess, and pneumoencefalocel. Posterior ethmoid sinus mucoceles can cause headache, nasal occlusion, visual impairment and diplopia. Mucoceles of the sphenoid sinus can cause damage to important surrounding structures, such as the dura mater, pituitary gland, the cavernous sinus, sfenopalatine ganglion and cranial nerves.Extention into orbital region can cause restriction of eye movements, diplopia, proptosis and headache. The diagnosis is usually put forth by neuroimaging after the medical history is taken and physical examination is made. Unless infected, they are monitored as in the form of air-free, contrast-free, homogeneous and isointense soft tissue masses with in Computed tomography (CT). Changes in the surrounding bone tissue like as expansion, thinning or erosion are better visualized with CT [3,6]. Magnetic resonance imaging (MRI) provides information about the surrounding soft tissue and it is more useful in critical locations involvement such as intracranial and intraorbital extension. Also contrast-enhanced MRI is the most preferred imaging modality in distinguishing paranasal sinus tumors from mucoceles [7]. Treatment options vary according to the case but the surgical removal or drainage is the only way to prevent intracranial and/or orbital complica-

tions. Surgery aproaches can be external, endoscopic or both. Surgical treatment consists of functional endoscopic sinus surgery, craniotomy and craniofacial approaches applied with or without sinus obliteration. More aggressive interventions may be needed for cases where middle fossa or orbita infiltrated by the mucocele[8-9].

The preference of imaging modalities (CT and MRI) is very useful in reaching a correct diagnosis of mucocele.

Çıkar Çakışması ve Finansman Beyanı

Bu çalışmada çıkar çakışması ve finansman destek alındığı beyan edilmemiştir.

Kaynaklar

1. Arrue p, Kany MT, Serrano E, et al. Mucoceles of the paranasal sinuses: uncomon location. J Laryngol Otol 1998; 112: 840-4.
2. Kennedy DW, Josephson JS, Zinreich SJ, Mattox DE, Goldsmith MM. Endoscopic sinus surgery for mucoceles: A viable alternative, Laryngoscope 99:885-895, 1989.
3. Neuenschwander MC, Pribitkin E, Lacombe V, Maus M, Rao V, Roth M. Frontoethmoid mucocele complicating Graves' ophthalmopathy. Ann Otol Rhinol Laryngol.1998;107: 433-5.
4. Serrano E, Klossek JM, Percodani J, Yardeni E, Dufuour X. Surgical management of paranasal sinus mucoceles: a long term study of 60 cases. Otolaryngol Head Neck Surg 2004; 131: 133-40.
5. Uzun L, Kalaycı M,, Uğurbaş SH, Çağavi F, Açıkgöz B. Komplike frontoorbital mukosel olgusu. KB-BBC Dergisi 2004; 12(1): 11-15.
6. Lee TJ, Li SP, Fu CH, Huang CC, Chang PH, Chen YW, Chen CW. Extensive paranasal sinus mucoceles: a 15-year review of 82 cases. Am J Otolaryngol. 2009 ;30(4):234-8.
7. Sautter NB, Citardi MJ, Perry J, Batra PS. Paranasal sinus mucoceles with skull-base and/or orbital erosion: is the endoscopic approach suffi cient? Otolaryngol Head Neck Surg.2008t;139(4):570-4.
8. Chiarini L, Nocini PF, Bedogni A, Consolo U, Giannetti L, Merli GA. Intracranial spread of giant frontal mucocele: a case report, Br J Oral Maxillofacial Surg 2000; 38:637-640.
9. Aynali G , Sivrice M E, Ünal F, Doğan M, Ünlü E N, Yarıktaş M. A Giant Mucocele of Nasal Septum: Case Report and Literature Review. DOI: 10.4328/JCAM.1885.

How to cite this article:
Arslan H, Saylık M. A Case Report of Anterior Ethmoid Mucocele Showing Intraorbital Extension. J Clin Anal Med 2013;4(suppl 3): 237-9.