Intrapericardial Gossypiboma in an Elderly Patient

Yaşlı Bir Hastada İntraperikardiyal Gossipiboma

İntraperikardiyal Gossipiboma / Intrapericardial Gossypiboma

Berkant Özpolat[1], Nesimi Günal[1], Rasih Yazkan[2], Koray Dural[1]
[1]Kırıkkale Üniversitesi Tıp Fakültesi, Göğüs Cerrahisi AD, Kırıkkale,
[2]Süleyman Demirel Üniversitesi Tıp Fakültesi, Göğüs Cerrahisi AD, Isparta, Türkiye

15. Toraks Derneği Kongresi, Nisan 2012, Antalya'da sunulmuştur.

Özet

Koroner arter hastalığı nedeniyle dört yıl önce bypass operasyonu geçiren 82 yaşındaki bir hastada unutulan perikardiyal "sponge" sunulmaktadır. Operasyon sonrası akciğer grafisinde retrokardiyak bölgede radyoopak filamentler görüldü. Bu vaka takdimi bilgisayarlı tomografi görüntülerinde sol ventrikülün arkasında iyi sınırlı ve içinde radyoopak filamentler bulunan, dört yıllık takipte pseudokistik değişiklikler gösteren kitleyi göstermektedir. Hastanın cerrahiyi reddetmesi neticesinde, gossipibomada zaman içinde meydana gelen değişikliklerin gösterilmesi bildiğimiz kadarıyla literatürde bir ilktir.

Anahtar Kelimeler

Perikardiyum; Komplikasyonlar; Bilgisayarlı Tomografi; X Ray; Medikolegal Bakış Açısı

Abstract

We report a case of surgically retained pericardial sponge in an 82-year-old man who underwent sternotomy for coronary artery bypass operation four years ago. After the operation the chest x-ray showed a radiopaque filament at the retrocardiac region. This case report shows the serial radiological examinations by computed tomographic scans over 4 years demonstrating a well-defined mass adjacent to left ventricle with a radiopaque filament inside with pseudocystic changes in time. As far as we know this case is the first one in the literature showing the changes in a case of gossypiboma, as the patient refused surgery.

Keywords

Pericardium; Complications; Computed Tomography; X Ray; Medicolegal Aspects

DOI: 10.4328/JCAM.2261 Received: 29.12.2013 Accepted: 13.01.2014 Printed: 01.11.2013 J Clin Anal Med 2013;4(suppl 3): 272-4
Corresponding Author: Berkant Özpolat, Kırıkkale Üniversitesi Tıp Fakültesi Hastanesi, Göğüs Cerrahisi AD, Yahşihan, Kırıkkale, Türkiye.
GSM: +905058395247 E-Mail: berkantozpolat@yahoo.com

Introduction

Gossypiboma or textiloma is a term used to describe a mass composed of cotton matrix referring to a retained surgical sponge [1-3]. Most cases of gossypibomas in the literature have been connected with abdominal surgery and its occurrence varies between 1/100 and 1/3000 for all surgical interventions [3,4]. Also reports describing findings of intraplevral retained sponges can be found but there is no data concerning the incidence [5-10].

Gossypibomas have several remarkable aspects including the risk of complications, presenting a diagnostic problem and associated with possible medico legal consequences [9].

The appearance and spontaneous modifications of a pericardial gossypiboma over years has not been documented on serial chest computed tomographic (CT) scan studies. The purpose of this report is to document the serial CT appearance of a gossypiboma due to a retained pericardial surgical sponge after sternotomy in an elderly patient.

Case Report

An 82-year-old man underwent a coronary bypass surgery. He made an uneventful recovery. The posterioanterior and lateral chest x-ray revealed a radiopaque filament at the retrocardiac region (Fig. 1) then he was consulted us with the pre-diagnosis of gossypiboma. The chest CT scan at early postoperative period showed a 10x10x7 cm diameter well-defined mass located intrapericardially with a minimal compression to left ventricle and left atrium. The mass appeared heterogeneous with irregular hyperdense internal areas and gas bubbles with a radiopaque filament inside (Fig. 2). Routine laboratory testing (complete blood count, erythrocyte sedimentation rate, blood biochemistry panel) was normal. Although the diagnosis is simple in this case because of the radiopaque filament, the differential diagnosis included a postoperative hematoma and an abscess formation. A reoperation was offered for the removal of the retained sponge but the patient refused as he has no complaints.

Follow-up CT scans has been performed every 6 months beginning from the application of the patient. The diameter of the gossypiboma decreased by 3 cm and gas bubbles disappeared at 4th year (Fig. 3) and the patient was still symptom-free. after 4 years.

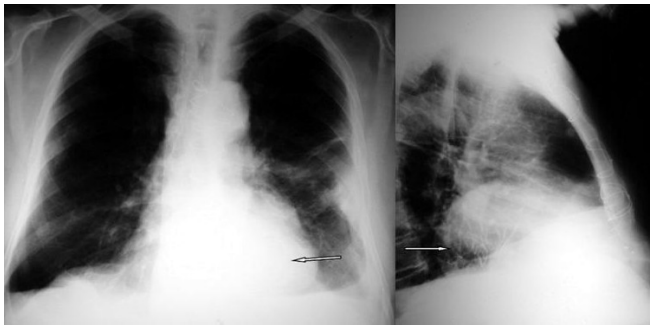

Fig.1. The posterioanterior and lateral chest x-ray revealed a radiopaque filament at the retrocardiac region

Discussion

Gossypibomas are non-neoplastic granulomatous proliferations induced by foreign bodies such as surgical sponges inadvertently left in operative wounds. They are composed of cotton matrix surrounded by granulomatous reaction [3]. Although the most common site is the abdominal cavity, many other sites such as the nose, breast, pancreas, pararenal space, tracheobronchial tree, vagina, spine, femur, neck and prostate have also been reported, whereas retained intrapericardial foreign bodies are extremely rare [1,11-14].

Emergencies, hemorrhagic procedures and time consuming operations are some circumstances that were reported to explain operative loss of sponges or other foreign substances [3,15,16]. They may be discovered incidentally or their presence may present a variety of consequences such as pain, abscess, fistula formation, perforation, adhesion, migration within contiguous organs, or embolisation through vessels, occlusion or sepsis [9,15]. Aseptic encapsulation may also develop and patient remains asymptomatic for years like in our case [2].

Conventional chest radiographs usually reveals an unusual opacity rising suspicion of a gossypiboma when a radiopaque marker is seen [9]. But sometimes this marker may be misinterpreted as a calcification, a surgical suture or an epicardial

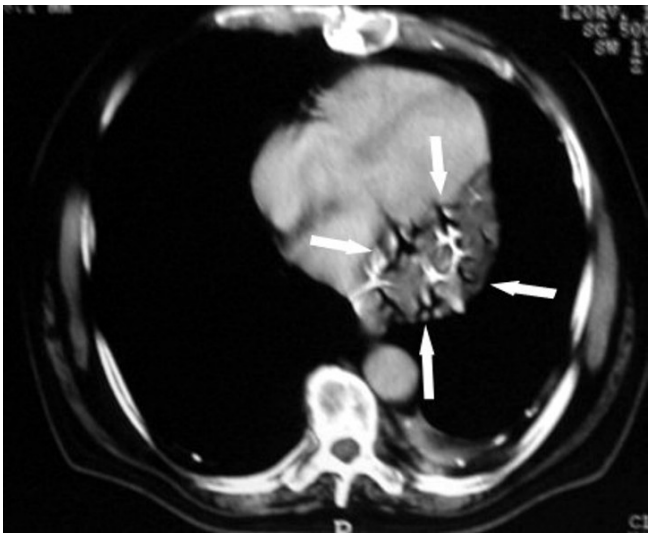

Fig.2. Thorax tomography showing heterogeneous mass with irregular hyperdense internal areas and gas bubbles with a radiopaque filament inside at admission.



Fig.3. Thorax tomography at 4th year showing the diameter of the gossypiboma decreased by 3 cm and gas bubbles disappeared.

pacing wire [7]. In the present case plain radiography is the key imaging examination because of the radiopaque marker and it directed us for a CT, which is the most effective method for detection of a retained surgical sponge in the thoracic cavity [7].

The most characteristic CT feature for a retained surgical sponge is spongiform pattern with gas bubbles [4,7,8]. A surgical sponge retained in the pericardial cavity usually appears as a well encapsulated cystic mass at the pericardial or retrocardial region [1,11,13]. In our case hypodense areas were noted on the first CT examination with gas bubbles. On serial CT examinations the diameter of the gossypiboma decreased by 3 cm in 4 years showing a homogenous appearance. The gas bubbles disappeared and the radiopaque marker was still inside. A thin but not calcified wall adjacent to left ventricle and atrium was noted with minimal enhancement after injection of contrast material.

In elderly patients, due to reduced immune response, foreign body reaction causing abscess formation and fistulisation may be at slower rates then young patients and surgical intervention is advised although the patient is asymptomatic [8]. We explained the possible complications if not operated, however the patient refused the removal of the retained sponge.

This case demonstrated the close follow-up and serial radiographical examinations of a retained intrapericardial sponge where patient refused surgical intervention for removal.

Competing interests

The authors declare that they have no competing interests.

References

1. Coşkun M, Boyvat F, Ağıldere AM. CT features of a pericardial gossypiboma. Eur Radiol 1999; 9: 728-30.
2. Bellin MF, Hornoy B, Richard F, et al. Perirenal textiloma: MR and serial CT appearance. Eur Radiol 1998; 8: 57-9.
3. Taçyıldız I, Aldemir M. The mistakes of surgeons: "Gossypiboma". Acta Chir Belg 2003; 103: 71-5.
4. Yuh-Feng T, Chin-Chu W, Cheng-Tau S, Min-Tsung T. FDG PET CT features of an intraabdominal gossypiboma. Clin Nucl Med 2005; 30: 561-3.
5. Topal U, Şahin N, Gökalp G, Gebitekin C. İntratorasik tekstilomlarda radyolojik bulgular. Tanısal ve Girişimsel Radyoloji 2004; 10: 280-3.
6. Gür S, Bozkurt M, Savaş R. İntratorasik gossipibomada BT bulguları: Olgu sunumu. Ege Tıp Dergisi 2005; 43: 117-9.
7. Suwatanapongched T, Boonkasem S, Sathianpıtayakul E, Leelachaikul P. Intrathoracic gossypiboma: radiographic and CT findings. Br J Radiol 2005; 78: 851-3.
8. Dülger H, Bayram AS, Kan İİ, Topal U, Gebitekin C. İntratorasik Gossipiboma. Toraks Dergisi 2002; 3: 204-6.
9. Catalano O, Nunziata A. An unusual thoracic opacity. Radiologie 1997; 37: 763-4.
10. Rijken MJ, J van Overbeeke A, Staaks GHA. Gossypiboma in a man with persistant cough. Thorax 2005; 60: 708.
11. Lerner CA, Dang HP. MR imaging of a pericardial gossypiboma. AJR Am J Roentgenol 1997; 169: 314.
12. Scott WW, Beall DP, Wheeler PS. The retained intrapericardial sponge: value of the lateral chest radiograph. AJR Am J Roentgenol 1998; 171: 595-7.
13. Unverdorben M, Bauer U, Oster H, Kraska H, Vallbracht C. A surgical gauze appearing as a retrocardiac mass in a patient after coronary artery bypass surgery. Eur J Radiol 1999; 29: 273-5.
14. Tsutsui JM, Hueb WA, Nascimento SA, Borges Leal SM, de Andrade JL, Mathias W Jr. Detection of retained surgical sponge by transthoracic and transesophageal echocardiography. J Am Soc Echocardiogr. 2003; 16: 1191-3.
15. Rajput A, Loud PA, Gibbs JF, Kraybill WG. Diagnostic challenges in patients with tumors. Journal of Clinical Oncology 2003; 21: 3700-5.
16. Akdemir A, Şimşek D, Yeniel AÖ, Çınar C, Ergenoglu AM. Batın Ön Duvarında Unutulan Cerrahi İğne: Olgu Sunumu. J Clin Anal Med. 2013; DOI: 10.4328/JCAM.2079.

How to cite this article:
Özpolat B, Günal N, Yazkan R, Dural K. Intrapericardial Gossypiboma in an Elderly Patient. J Clin Anal Med 2013;4(suppl 3): 272-4.